

Re-Laparotomy And Parallel Vertical-Compression Sutures And Prostaglandins For Massive Intraperitoneal Haemorrhage Following Caesarean Section For Placenta Praevia

H Muppala, F Basama, F Hamer

Citation

H Muppala, F Basama, F Hamer. *Re-Laparotomy And Parallel Vertical-Compression Sutures And Prostaglandins For Massive Intraperitoneal Haemorrhage Following Caesarean Section For Placenta Praevia*. The Internet Journal of Gynecology and Obstetrics. 2005 Volume 5 Number 2.

Abstract

Postpartum haemorrhage is a serious, life-threatening obstetric problem. It remains as one of the leading causes of maternal morbidity and mortality both in the developing and the developed world. Traditionally postpartum haemorrhage is treated by either medical or radical surgical procedures. In the last decade conservative surgical procedures have been successfully used in various circumstances and forms. We are reporting for the first time the use of simple parallel through and through vertical compression sutures to the lower segment on re-laparotomy for massive intraperitoneal bleeding following caesarean section for placenta praevia. We discussed the reasons for bleeding from the lower segment and the technique of the procedure undertaken to achieve haemostasis. It is extremely important to closely monitor during post-operative period at risk patients. We also recommend it to be considered as a prophylactic procedure during caesarean section for placenta praevia.

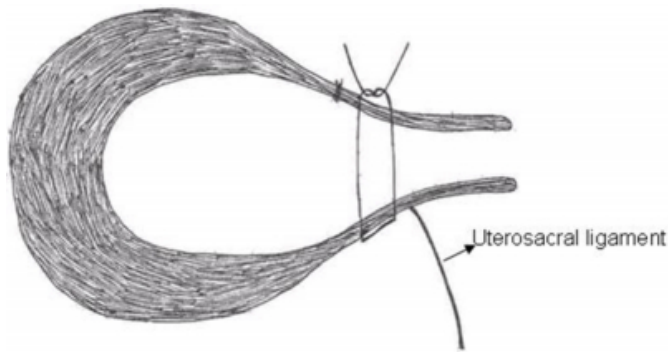
CASE REPORT

A 30-year old patient was in her fourth pregnancy. She has no significant past medical and surgical history. Her first delivery was by an emergency caesarean section for Pre-Eclamptic Toxaemia (PET) and foetal distress. The second and third pregnancies were early spontaneous miscarriages. In view of this history, she was commenced on low – dose aspirin. The anomaly scan at 20 weeks diagnosed placenta praevia, which was confirmed by repeat scan at 35 weeks, which revealed a grade 4 placenta praevia on right lateral wall of uterus completely covering the os. She had an elective caesarean section at 37+2 weeks gestation. The procedure was performed by a consultant under general anaesthesia. The placenta was completely delivered by controlled cord traction; a velamentous insertion of the umbilical cord was noticed. As a prophylaxis against postpartum haemorrhage, 800 micrograms of misoprostol were introduced into the uterine cavity in addition to an infusion of 40 unit of syntocinon in 500 ml of normal saline to run for 6 hours. The procedure was uncomplicated and the haemostasis was good. The estimated blood loss was 500–600 ml. She gave birth to a healthy baby, weighing 3.4 kg.

The immediate – postoperative period was uneventful. However, seventeen hours postoperatively, patient started complaining of abdominal and shoulder tip pains. She was pale, sweaty, tachycardic, and short of breath. The abdomen was distended. There was minimum lochia. Resuscitative measures were undertaken. Intraperitoneal haemorrhage was suspected, which was confirmed by an abdominal ultrasound scan that revealed massive intraperitoneal fluid. An emergency exploratory laparotomy was undertaken. The exploratory laparotomy revealed haemoperitoneum of nearly two litres. There were no specific bleeding points and the bleeding was mainly oozing from the lower segment and through the intact suture lines. The bleeding was controlled by four parallel, vertical – compression sutures to the lower segment of the uterus and without opening the lower segment. Number 1 vicryl suture with round bodied curved needle was used. The sutures were placed 1.5 to 2 cm apart. The needle was passed from the anterior to the posterior aspect of the uterus, and back to the anterior aspect approximately 2 cm cranial to the previous entry point. The sutures were placed just above the attachment of the uterosacral ligaments. (Fig. 1).

Figure 1

Figure 1: Through and through vertical compression sutures to the lower segment (hand-drawn figure).



500 µg of intramural haemabate were given intraoperatively and the syntocinon infusion was maintained, in addition to further 800 µg of misoprostol rectally. Haemostasis was confirmed before closure and placement of appropriate closed drains. The antibiotic prophylaxis, with co – amoxiclav (augmentin) was maintained for 5 days. She also received 3 units of compatible blood. The postoperative course was uncomplicated. And she made good recovery and was discharged home on 4th postoperative day.

DISCUSSION

Postpartum haemorrhage is a serious, life – threatening obstetric problem. It remains as one of the most common causes of maternal morbidity and mortality both in the developing and the developed world. ¹ Maternal mortality due to postpartum haemorrhage in developing world is around 1 in 1000; where as in developed world it is around 1 in 100000 deliveries. ¹ Globally postpartum haemorrhage accounts for a quarter of all maternal deaths. In UK blood loss above 1000ml has been reported following 1.3% of deliveries. ² Death from obstetric haemorrhage was 3rd leading cause of maternal mortality in the U.K. ³ In the last report of the confidential enquiry (6th) into maternal death and child health in the United Kingdom there were 17 deaths from obstetric haemorrhage; 4 from placenta praevia, 3 from placental abruption, and 10 from postpartum haemorrhage and substandard care was identified in 89% of the cases. ³ All of the women who died from placenta praevia had previous caesarean section. A high index of suspicion coupled with prevention, early recognition and prompt appropriate intervention are the keys to minimise the complications and its consequences. We are reporting for the first time the use of simple parallel through and through vertical compression sutures to the lower segment on re –

laparotomy for massive intraperitoneal bleeding following caesarean section for placenta praevia.

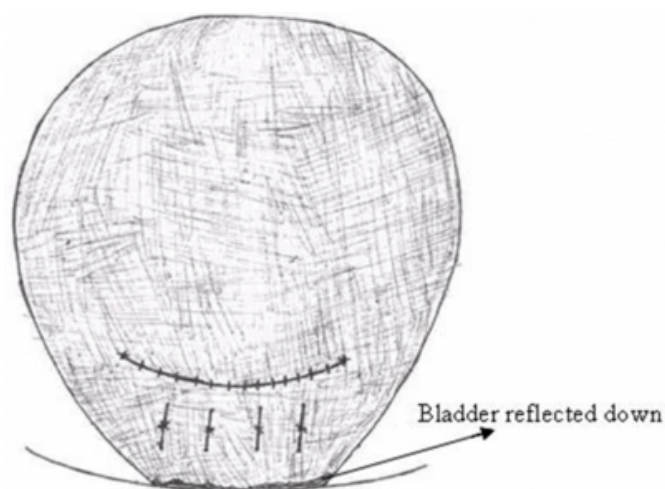
In this case we thought that the multiple oozing points on the lower segment might be due to small lacerations that developed after the removal of placenta. ^{4,5} We also thought that the inherent inability of the lower segment of the uterus to contract effectively was an additional contributing factor. We were aware of different techniques reported in the medical literature, such as B – Lynch sutures for atony of the uterus and other less reported varied methods of conservative compression sutures. ⁶ These techniques are, usually, employed as a second – line management in primary postpartum haemorrhage before proceeding to ligation of internal iliac arteries, embolisation of uterine arteries, or hysterectomy; ⁷ however, after the consideration of the different techniques we decided that the employment of parallel, vertical sutures was the most appropriate technique to be undertaken in order to preserve the woman's reproductive functions and to avoid hysterectomy and its related complications and consequences.

The sutures are easy to apply and provide a safe, conservative, alternative to hysterectomy and should be considered in cases of thin, floppy lower segment, which fails to contract. We would also recommend prophylactic use of parallel vertical compression sutures to the lower segment in placenta praevia in optimal numbers and tension to avoid postpartum haemorrhage, its associated complications and complex rectifying procedures. ^{8,9} This prophylaxis procedure is most appropriate for patients with placenta praevia and previous uterine scar, who are more prone to uncontrollable intrapartum haemorrhage and not infrequently require caesarean hysterectomy. ¹⁰

The parallel, vertical – sutures with optimal tension not only prevents tears and injury to the lower – uterine segment, but also ensure its patency, thus preventing fluid collection; haematometra, pyometra, and synaechiae. ^{8,11} (Fig. 2). This process is further aided by the effective contraction and retraction of upper segment, ¹² which ensures the patency of the uterus, the expulsion of the lochia, and effective haemostasis, through its attachment and compression. ¹³ Suturing the anterior and posterior uterine walls together will give an almost immediate haemostatic effect, and the suture material will be absorbed within a few weeks. ⁵ This technique, not only retains the uterus, but also preserves fertility. The technique does not require experience; however, basic – surgical skills are certainly required.

Figure 2

Figure 2: Anterior aspect of lower segment after placement of four parallel vertical compression sutures in optimal tension (hand-drawn figure).



The relative maternal hypervolaemia, which is present near term, may delay the clinical signs of haemorrhage, such as hypotension and tachycardia; hence, the clinical manifestations may only become apparent when the blood loss was substantial and that often occur, just, before the patient becomes haemodynamically unstable. Failure to achieve haemostasis could result in dilutional coagulopathy and disseminated intravascular coagulation. Hypothermia and acidosis due to prolonged hypovolaemic shock may follow. Most maternal deaths are avoidable by; rapid institution of resuscitative measures, early diagnosis, and timed – operative intervention as demonstrated in this case.

This case also emphasise the standard of care for such patients and the importance of the involvement of senior obstetricians in the management at an early stage. It also highlights the importance of intensive, postoperative monitoring, especially for patients, who are at risk of postpartum haemorrhage.

References

1. Drife J. Management of Primary Postpartum Haemorrhage. *British Journal of Obstetrics and gynaecology* 1997; 104:275-277.
2. William Thompson, M. Ann Harper. Postpartum haemorrhage and abnormalities of the third stage of labour. *Turnbull's Obstetrics*. 3rd Edition 2001:619-633.
3. Department of Health (2004) The Report on the Confidential Enquiries into Maternal Deaths and Child Health (CEMDCH): Why mothers die? in the United Kingdom. 2000 - 2002. London: HMSO, 2004.
4. M.Giridi, W. Noble, Z. Rafique, K. Patil and S. W. Lindow. Case Reports. Caesarean section for placenta praevia complicated by postpartum haemorrhage managed successfully with recombinant activated human coagulation factor VIIa. *Journal of Obstetrics and Gynaecology* 2004; 24(8):925-926.
5. W. A. A. Tjalma, Y. Jacquemyn. Brief communication. A uterus-saving procedure for postpartum haemorrhage. *International Journal of Obstetrics and gynaecology* 2004; 86:396-397.
6. M. S. Allam, C. B-Lynch. Review Article. The B-Lynch and other uterine compression suture techniques. *International Journal of Obstetrics and gynaecology* 2005; 89:236-241.
7. Mousa H.A.; Alfircvic Z. Major postpartum haemorrhage: survey of maternity units in the United Kingdom. *Acta Obstetrica et gynaecologica Scandinavica* 2002; 81(8):727-730(4).
8. Yuh-Ming Hwu, Chie-Pien Chen, Hung-Sheng Chen, Tsung-Hsien Su. Surgical Technique. Parallel vertical compression sutures: a technique to control bleeding from placenta praevia or accreta during caesarean section. *BJOG: an International Journal of Obstetrics and Gynaecology* 2005; 112:1420-1423.
9. Seffah JD. Re-laparotomy after caesarean section. *International Journal of Gynaecology and Obstetrics* 2005; 88(3):253-7.
10. The management of postpartum haemorrhage. Scottish obstetric guidelines and audit project. (SPCERH 6, published June 1998). Guideline update prepared March 2002.
11. Chih-Ping Chen, Tung-Yao Chang, Li-Fan Yeh, Chen-Ju Lin, Wayseen Wang. Sonographic appearance of the uterus after simple square suturing for rapid control of postpartum haemorrhage and preservation of fertility. *Journal of Clinical Ultrasound* 2002; 30(3):189-191.
12. Sunita Sharma, Hazem El-Rafaey. Prostaglandins in the prevention and management of postpartum haemorrhage. *Best practice & Research Clinical Obstetrics and gynaecology* 2003; 17(5):811-823.
13. Cho JH, Jun HS, Lee CN. Haemostatic suturing technique for uterine bleeding during caesarean delivery. *Obstetrics and Gynaecology* 2000; 96(1):129-131.

Author Information

H. Muppala, DGO

Department of Obstetrics and Gynaecology, Women's Directorate, Burnley General Hospital

F.M.S. Basama, MRCOG, MD

Department of Obstetrics and Gynaecology, Women's Directorate, Burnley General Hospital

Fiona Hamer, FRCOG

Department of Obstetrics and Gynaecology, Women's Directorate, Burnley General Hospital