

Holmium:YAG Laser Fiberoptic Bronchoscopy Via Laryngeal Mask Airway

L Myers, S Bakthavachalam, T Thomason, K Klein

Citation

L Myers, S Bakthavachalam, T Thomason, K Klein. *Holmium:YAG Laser Fiberoptic Bronchoscopy Via Laryngeal Mask Airway*. The Internet Journal of Otorhinolaryngology. 2006 Volume 6 Number 2.

Abstract

The laryngeal mask airway (LMA) is a supraglottic device that is open to the laryngeal inlet and is used to maintain a patent airway during inhalational anesthesia. Use of an LMA in combination with a flexible fiberoptic bronchoscope (FFB) has opened new possibilities to safely and effectively visualize and manage lesions of the laryngo-tracheal region. Further, the LMA and FFB in combination with a fiberoptic laser have been described to successfully diagnose and treat airway lesions.

We describe the application of this anesthetic technique for 8 patients undergoing holmium:YAG (yttrium aluminum garnet) laser bronchoscopy for glottic, subglottic, and tracheal lesions. For this patient population, we found this application to be an exceptionally versatile technique, providing adequate airway protection while permitting spontaneous and/or assisted ventilation without obscuring the airway lesions.

INTRODUCTION

Airway protection for patients with glottic or subglottic stenotic lesions requiring general anesthesia for treatment is crucial for patient safety. Endotracheal intubation, jet ventilation, and spontaneous ventilation under deep intravenous sedation are established anesthetic techniques used for advanced surgical management. Despite proper patient selection and thoughtful planning for the most appropriate anesthetic method, each of these techniques may still be less than optimal to appropriately manage a lesion of the upper airway.

The laryngeal mask airway (LMA) is a supraglottic device that is open to the laryngeal inlet and is used to maintain a patent airway during inhalational anesthesia. The LMA has shown that the supraglottic airway approach is not only feasible, but in many situations superior to tracheal intubation.^{1,2} Although the LMA initially was recommended as an alternative to the facemask, its use has expanded, benefiting patients undergoing a variety of diagnostic and therapeutic procedures. Use of an LMA in combination with a flexible fiberoptic bronchoscope (FFB) has opened new possibilities to safely and effectively visualize and manage lesions of the laryngo-tracheal region. Subsequently, the LMA and FFB in combination with a fiberoptic laser have been described to successfully diagnose and treat airway lesions.^{1,2,3}

We describe the application of this anesthetic technique for patients undergoing holmium:YAG (yttrium aluminum garnet) laser bronchoscopy for glottic, subglottic, and tracheal lesions. For this patient population, we found this application to be an exceptionally versatile technique, providing adequate airway protection while permitting spontaneous and/or assisted ventilation without obscuring the airway lesions.

DESCRIPTION OF TECHNIQUE

After the patient is transferred to the operating room suite, intravenous or inhalational anesthesia is induced. An LMA is then inserted in standard fashion to the level of the laryngeal inlet. The LMA cuff is then inflated to secure the airway and the LMA is connected to the ventilatory circuit. General inhalational anesthesia is maintained with sevoflurane or desflurane with an $\text{FiO}_2 < 0.3$. The patient is allowed to breathe either spontaneously or with mechanical assistance. A Portex® Fiberoptic Bronchoscope Swivel Adaptor (Smiths Medical ASD, Inc., Keene, NH) is placed between the LMA and ventilator tubing. This allows a flexible fiberoptic bronchoscope to be placed into a side port on the adaptor and advanced down the LMA lumen until the larynx is visualized. The Holmium:YAG laser fiber (Lumenis, Inc., Santa Clara, CA) is passed through the flexible bronchoscope until the tip of the fiber is visualized (Figure 1). The fiber tip is allowed to contact the lesion

requiring ablation and the laser is activated. If obstruction of the breathing circuit is becomes a problem, the bronchoscope and laser fiber may be intermittently removed in order to fully ventilate the patient and maintain adequate arterial oxygenation. After completion of the procedure, the patient emerges from anesthesia and the LMA is removed. The patient is transferred to the post anesthesia care unit for recovery.

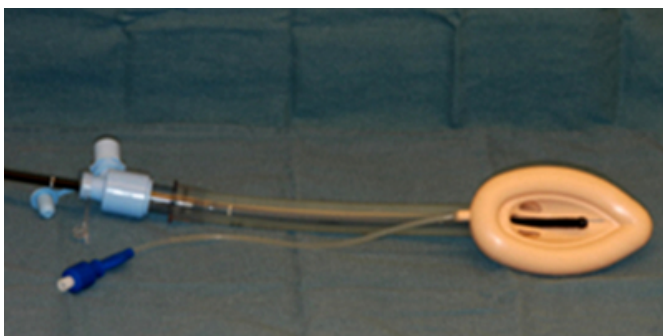
RESULTS

We report 7 patients who underwent 8 holmium:YAG laser fiberoptic bronchoscopies (HLFB) via LMA. Four patients were female and 3 were male. The average age was 47.1 years (range 35.6 - 61.5 years). One patient had a glottic lesion, 3 patients had subglottic stenosis, and 4 patients had tracheal stenosis. One patient was treated for both tracheal and subglottic stenosis on two separate procedures. Five patients were treated as outpatients and 2 were managed as inpatients. The average post-treatment hospital stay for the 2 inpatients was 1.5 days. Seven procedures were elective and 1 procedure was semi-urgent. The average power setting was 8 Watts (range 1.6 – 10 Watts) and the average total energy used was 2.93 KJ (range .026 – 6.0 KJ).

There were no intraoperative complications noted, such as loss of airway, migration of LMA from laryngeal inlet, need to replace LMA, need to convert to endotracheal intubation, uncontrollable hemorrhage, or airway fire.

Figure 1

Figure 1: Holmium:YAG fiber through bronchoscope in a laryngeal mask airway with bronchoscope swivel adapter



DISCUSSION

The Holmium:YAG fiber laser can be used for ablation, excision, incision, vaporization and immediate hemostasis of soft tissues through endoscopic, laparoscopic and open access for a wide variety of surgical applications and procedures. Otolaryngic applications of the holmium laser include partial turbinectomy, tonsillectomy/adenoidectomy,

polypectomy, endonasal and endoscopic sinus surgery, and as described here, ablation of airway stenosis. The VersaPulse PowerSuite holmium laser transmits energy through flexible fibers, making it especially suited for minimally invasive endoscopic procedures. The Holmium:YAG laser has a 2100-nm wavelength in the infrared spectrum with up to a 0.5 mm depth of penetration. The energy can delivered through a variety of small diameter disposable and re-useable delivery devices which allows for precise delivery of laser energy.

The laryngeal mask airway is a supraglottic device that allows for ventilation without tracheal intubation. The ability to use the LMA in combination with a flexible fiberoptic bronchoscope makes it a favorable device to manage the airway while accessing lesions throughout the upper- and large conducting-airway. The advantages of using a laryngeal mask airway include attenuation of the hypertensive response seen in conventional tracheal intubation, decreased airway resistance, and facilitation of smooth emergence from anesthesia.¹ In combination with a flexible bronchoscope, excellent visualization and maneuverability can be achieved to precisely access areas in the airway.

Although reported in the pediatric literature,^{3,4,5} there are few reports of using FFB via LMA adult population. Kanagalingam et. al described using the LMA with flexible bronchoscope in managing two adult patients with anterior glottic lesions that were inaccessible using suspension microlaryngoscopy.²

Clear communication and respectful cooperation between the anesthesia and surgical teams are crucial and must be maintained throughout entire procedure. All personnel involved must remain vigilant regarding the patient's oxygenation and ventilation.

SUMMARY

We present our favorable experience using an LMA coupled with flexible bronchoscopy to treat upper airway and tracheal lesions using the Holmium:YAG laser. We found this combined technique to safely maintain the airway while fully visualizing lesions in this region. In the properly selected patient, the LMA coupled with flexible bronchoscopy to treat upper airway and tracheal lesions using the Holmium laser offers many advantages over non-LMA anesthetic methods.

CORRESPONDENCE TO

Larry L. Myers, MD Department of Otolaryngology-Head and Neck Surgery University of Texas Southwestern Medical Center 5323 Harry Hines Boulevard Dallas, TX 75390-9035 214.648.5643 (office) 214.6489122 (facsimile) Larry.myers@utsouthwestern.edu

References

1. Jameson JJ, Moses RD, Vellayappan U, Lathi KG. Use of the laryngeal mask airway for laser treatment of the subglottis. *Otolaryngology Head Neck Surgery*

2000;123:101-02.

2. Kanagalingam J, Hurley R, Grant HR, Patel A. A new technique for the management of inaccessible anterior glottic lesions. *Journal Laryngology Otology*. 2003;117:302-06.

3. Ogata J. The airway management using laryngeal mask airway and tracheal fiberoptic in a pediatric patient with tracheal stenosis after tracheostomy. *Masui*. 2004;53:1282-5.

4. Somri M, Barna Teszler C, Tome R, Kugelman A, Vaida S, Gaitini L. Flexible fiberoptic bronchoscopy through the laryngeal mask airway in a small, premature neonate. *American Journal Otolaryngology*. 2005;26:268-71.

5. Tunkel DE, Fisher QA. Pediatric flexible fiberoptic bronchoscopy through the laryngeal mask airway. *Archives Otolaryngology Head Neck Surgery*. 1996;122:1364-7.

Author Information

Larry L. Myers, M.D.

Department of Otolaryngology-Head and Neck Surgery, University of Texas Southwestern Medical Center

Sivi Bakthavachalam, M.D.

Department of Otolaryngology-Head and Neck Surgery, University of Texas Southwestern Medical Center

Timothy S. Thomason, M.D.

Department of Otolaryngology-Head and Neck Surgery, University of Texas Southwestern Medical Center

Kevin Klein, M.D.

Department of Anesthesiology, University of Texas Southwestern Medical Center