

Primary Perianal Tuberculosis In A Chronic Alcoholic Patient: A Case Report

G Ercan, G Sadullah, K Neval Berrin, T Hakan, O Selver

Citation

G Ercan, G Sadullah, K Neval Berrin, T Hakan, O Selver. *Primary Perianal Tuberculosis In A Chronic Alcoholic Patient: A Case Report*. The Internet Journal of Surgery. 2008 Volume 18 Number 1.

Abstract

Perianal tuberculosis is a rare extrapulmonary form of the disease. We describe a chronic alcoholic patient with perianal tuberculosis without gastrointestinal or pulmonary spread. We present the management of a 68-year-old heterosexual man with a painless non-specific perianal ulcer. He consumed around 35-40g of alcohol per day. Examination of the anal region showed an ovoid and sharply demarcated perianal ulceration, about 3cm in diameter, with indurated edges and granulation tissue at the base. Microscopic examination with EZN stain of biopsy material was positive for acid-fast bacilli. Lowenstein-Jensen cultures of biopsies grew *Mycobacterium tuberculosis* and PCR was positive for *Mycobacterium tuberculosis*. Histopathological examination of perianal lesion biopsies showed epithelioid granulomas and Langhans' type multinucleated giant cells. Lesions which are painless, ulcerative and unhealing, especially in patients who have immune deficiency like chronic alcoholics, should remind us of perianal tuberculosis even if no primer is observed in a different region.

INTRODUCTION

Tuberculosis can be divided into three categories: pulmonary and extra-pulmonary alone, or both. Extra-pulmonary tuberculosis can attack any organ. Perianal tuberculosis, without the presence of any previous or active pulmonary infection, is extremely rare. Although the symptoms are often misleading and thus go unrecognized, they ought to be recognized, because they require specific treatment (1).

For many years, the medical literature worldwide has suggested an association between alcohol consumption and active tuberculosis (2). In this study, we present a case of perianal tuberculosis without gastrointestinal or pulmonary spread.

CASE REPORT

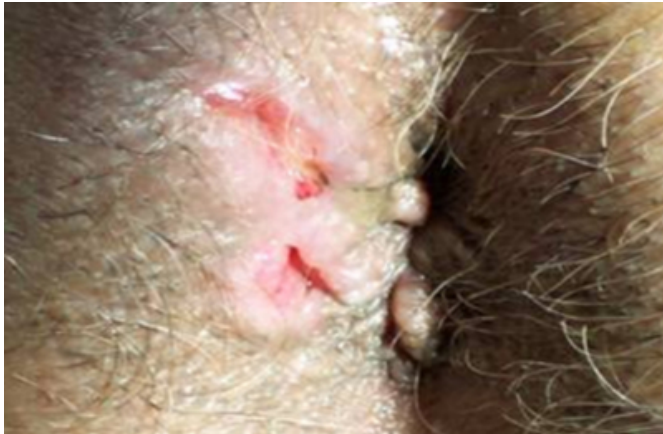Our patient was a 68-year-old heterosexual man who presented with painless perianal ulcers of 6-months' duration. He consumed around 35-40g of alcohol per day and did not have any systemic illness. There was no tuberculosis history in the patient's anamnesis, family and relatives. Treatment of perianal ulcer with multiple topical antibiotics and epithelializing ointment had been ineffective.

There were no other abnormalities on general examination. Local examination of the anus showed a 3x2cm shallow, single, posterior anal ulcer with irregular margin and

granulation tissue (Figure 1). Digital rectal examination and colonoscopy results were normal. Laboratory findings, including routine serum and urine biochemical analysis, complete blood count and liver function tests were normal. Erythrocyte sedimentation rate was 30mm. The enzyme-linked immunosorbent assay for HIV and syphilis serological tests were negative. Chest X-ray revealed no pathological findings. The tuberculin skin test with 2 IU of PPD-RT 23 showed a negative reaction with 4mm of induration. The perianal lesion was curetted and biopsy material was taken.

Figure 1

Figure 1: Perianal painful and ulcerative lesion with irregular margin



Microscopic examination with Ehrlich-Ziehl-Neelsen (EZN) stain of biopsy material was positive for acid-fast bacilli (Figure 2). From the culture of the biopsy specimen, tubercle bacilli were isolated on Löwenstein-Jensen medium. Sputum collected on three subsequent days was negative for tubercle bacilli. In addition, polymerase chain reaction (PCR) was positive for *Mycobacterium tuberculosis*. Histopathological examination of perianal lesion biopsies showed epithelioid granulomas and Langhans' type multinucleated giant cells (Figure 3).

Figure 2

Figure 2: Photomicrograph of the perianal biopsy material showing acid-fast bacilli (EZN stain, 10x).

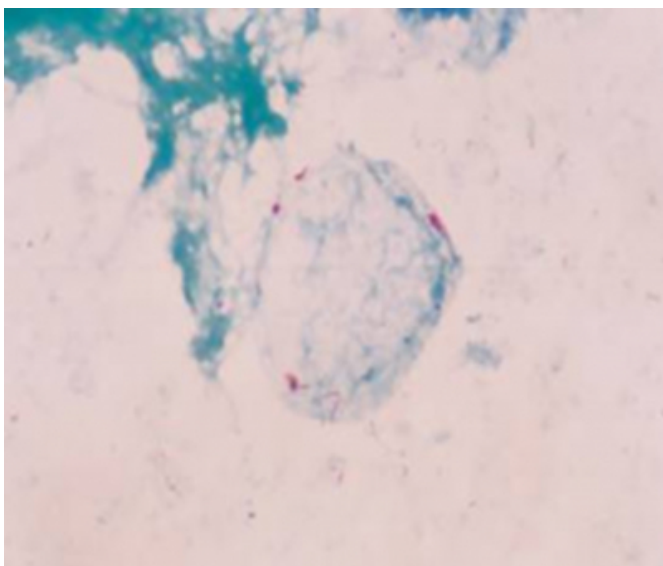
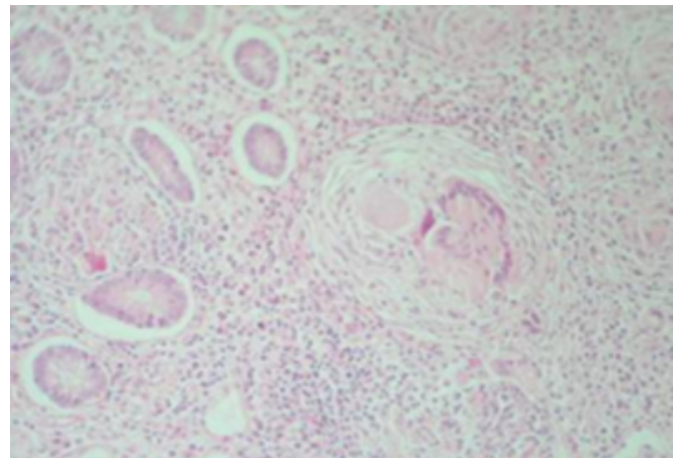


Figure 3

Figure 3: Photomicrograph of the perianal biopsy material showing epithelioid granulomas and Langhans' type multinucleated giant cells (H&E-stained, 20x).



Isoniazid 300mg/day, rifampicin 600mg/day, pyrazinamide 1500mg/day and ethambutol 1500mg/day were administered for two months and isoniazid 300mg/day, rifampicin 600mg/day were subsequently administered for four months. After treatment, the patient was followed up for eighteen months without encountering any problem.

DISCUSSION

Tuberculosis remains an important public health problem worldwide. According to the World Health Organization, the annual incidence of tuberculosis is nearly 8 million persons, with 2 million deaths per year (3). Extra-pulmonary tuberculosis may have different clinical manifestations and may be difficult to diagnose compared to pulmonary tuberculosis. Caseous foci frequently occur in lymph nodes, bone and prostate gland, but remain undetected in the absence of clinical symptoms (4). Gastrointestinal tuberculosis comprises less than 1 percent of all proved or suspected cases of tuberculosis, mainly affecting the ileum, peritoneum, large bowel, jejunum, and appendix. Anal disease is reported to be either absent or exceedingly rare (5).

The postulated mechanisms by which the tubercle bacilli reach the perianal region are: (i) haematogenous spread from the primary lung focus in childhood, with later reactivation; (ii) ingestion of bacilli in sputum from an active pulmonary focus; (iii) direct spread from adjacent organs; and (iv) through lymph channels from infected nodes (6). In our patient, any focus due to tuberculosis seen elsewhere in the body, or active tuberculosis, was not observed.

Various forms of tuberculosis are described in the literature:

ulcerative, miliary, lupoid, verrucous and fistulous. The reasons for such a spectrum of clinical presentations are not fully understood, but the site, the number and the virulence of the organisms appear to have some bearing upon the problem. Ulcerative tuberculosis is the commonest form. The ulcerated form of anal tuberculosis typically presents as a superficial ulceration, not hardened, with a hemorrhagic necrotic base that is granular and covered with thick purulent secretions of mucus. The lesion may be very painful, or the patient may have few symptoms (7). Also in our patient we found the ulcerative form, with irregular margin and granulation tissue, and this lesion was painless.

Sultan et al. presented that the average length of time between first manifestation of the disease and diagnosis was three years; all patients had undergone surgery previously (1). Our patient had not undergone any surgical treatment and the time to diagnosis was 6 months. So, chronic, repetitive or non-healing perianal lesions – with or without surgical treatment – should remind us of tuberculosis.

There are some difficulties of identifying perianal tuberculosis. First, the incidence of the perianal infection itself is relatively lower; the common causative agents are bacteria. Second, there are no significant characteristics of symptoms and signs at the infectious site to differentiate the causative organisms initially. Most symptoms in perianal tuberculosis mimic those in other common pathogen infections (5, 8). Diagnosis of tuberculosis is generally based on histologic or bacteriologic analysis. The typical histologic lesion is the epithelioid and giant cell tubercle around a zone of caseous necrosis, but the pathognomonic presence of caseation is not constant, and presents diagnostic problems, especially in the case of Crohn's disease with anoperineal localization. Diagnosis can also be done by looking for Koch's bacillus in the anal lesions by direct examination (Ehrlich-Ziehl-Neelsen stain) and culture. To overcome the slowness of the culture (3 to 4 weeks), new diagnostic techniques for tuberculosis have been proposed, in particular genomic amplification by polymerase chain reaction, which can detect the presence of the bacterial DNA in 48 hours with high sensitivity (10). The differential diagnosis for perianal tuberculosis is primarily Crohn's disease, which has remarkable clinical similarities with mycobacterial infections. Other possible granulomatous diseases of the anus can occur, such as amoebiasis, reaction to a foreign body, sarcoidosis, syphilis, and venereal lymphogranuloma with Chlamydia trachomatis. In rare cases, perianal tuberculosis can simulate cancer, particularly colloid cancer;

here, histology is vital to make the correct diagnosis (9).

Alcohol abuse is considered to be one factor that interferes with the host's immune surveillance system and has been implicated in atrophy of the thymus and spleen, loss or redistribution of peripheral blood leukocytes and diminished humoral and cell-mediated immune responses (10). The increased incidence of Mycobacterium tuberculosis infections in the chronic alcoholic is a clear example of pulmonary infection resulting, at least partially, from the defect in cell-mediated immunity noted in these patients. Although the association of alcoholism and tuberculosis has been attributed to sociodemographic factors, several series suggest that alcohol abuse independently predisposes the individual to reactivation disease. Indeed, a recent report of tuberculosis risk factors in a large cross-sectional study identified alcoholism as the strongest predictor of tuberculosis (11). It is considered that chronic alcohol use has been a predictor factor for tuberculosis infection in our patient.

In conclusion, perianal tuberculosis should be taken into account in the diagnosis of painless, ulcerative and unhealing anal lesions, especially in chronic alcoholic patients with immune system deficiency.

CORRESPONDENCE TO

Ercan Gedik Department of General Surgery School of Medicine University of Dicle, 21280 Diyarbakir/Turkey
Tel.: +904122488001-4679 Fax: +904122488523 e-mail: egedik@dicle.edu.tr

References

1. Sultan S, Azria F, Bauer P, Abdelnour M, Atienza P. Anoperineal tuberculosis: diagnostic and management considerations in seven cases. *Dis Colon Rectum* 2002; 45:407-10.
2. Mason CM, Dobard E, Zhang P, Nelson S. Alcohol exacerbates murine pulmonary tuberculosis. *Infect Immun* 2004; 72: 2556-63.
3. Dye C, Scheele S, Dolin P, Pathania V, Ravigliione MC. Consensus statement. Global burden of tuberculosis: estimated incidence, prevalence, and mortality by country. WHO Global Surveillance and Monitoring Project. *JAMA* 1999; 282: 677-86.
4. Slavin RE, Walsh TJ, Pollak A. Late generalized tuberculosis: a clinical pathologic analysis and comparison of 100 cases in the pre-antibiotic and antibiotic eras. *Medicine* 1980; 59: 352-66.
5. Candela F, Serrano P, Arriero JM, Teruel A, Reyes D, Calpena R. Perianal disease of tuberculous origin: report of a case and review of the literature. *Dis ColonRectum* 1999; 42: 110-2.
6. Le Bourgeois PC, Poynard T, Modai J, Marche C, Avril MF, Chaput JC. Peri-anal ulceration. Tuberculosis should not be overlooked. *Presse Med* 1984; 13: 2507-9.

7. Jali HM. Tuberculous anal ulcer. Journal of the Royal Society of Medicine 1989; 82: 629-30.
8. Lin CH, Yeh SP, Huang HH, Liao YM, Chiu CF. Perianal tuberculosis during neutropenia: a rare case report and review of literature. Ann Hematol 2006; 85: 547-8.
9. Gupta PJ. Ano-perianal tuberculosis - solving a clinical dilemma. African Health Sciences 2005; 5: 345-7.
10. Cook RT. Alcohol abuse, alcoholism and damage to the immune system: a review. Alcohol Clin Exp Res 1998; 22:1927-42.
11. Happel KI, Nelson S. Alcohol, immunosuppression, and the lung. Proc Am Thorac Soc 2005; 2: 428-32.

Author Information

Gedik Ercan, M.D.

Assistant Professor, Department of General Surgery, Dicle University

Girgin Sadullah, M.D.

Assistant Professor, Department of General Surgery, Dicle University

Kaya Arserim Neval Berrin

Assistant Professor, Department of Microbiology, School of Veterinary Medicine, Dicle University

Temiz Hakan, M.D.

Doctor, Department of Microbiology, Hospital of Diyarbakır

Ozekinci Selver, M.D.

Assistant Professor, Department of Pathology, Dicle University