

# Acquired Tracheoesophageal Fistula in Infancy: Communication is Key to Successful Outcome

A Reddy, J Iocono, R Brown Jr.

## Citation

A Reddy, J Iocono, R Brown Jr.. *Acquired Tracheoesophageal Fistula in Infancy: Communication is Key to Successful Outcome*. The Internet Journal of Anesthesiology. 2008 Volume 19 Number 1.

## Abstract

Acquired Tracheoesophageal Fistula (TEF) is a life threatening condition and usually occurs secondary to trauma or invasion of anatomic structures in the mediastinum by neoplasm. It is uncommon for infants to ingest articles large enough to produce esophageal damage. Failure to diagnose foreign body ingestion in a timely manner can allow time for erosion into the wall of the esophagus with subsequent profound injury to the esophagus, the trachea or both.

We present a case of plastic lollipop ring ingestion in a 10-month-old infant resulting in acquired TEF. The importance of communication between the surgeons and the anesthesiologists prior to definitive operative procedure as well as during repair of a traumatic injury to the trachea is stressed. Acquired TEF in an infant can be a life threatening emergency and the anatomic relationships and plans for the worst-case scenario should be reviewed prior to taking the infant to the operating room.

## CASE REPORT

A previously healthy, ten month old female infant weighing 9.6 kg was admitted for respiratory distress. This was her fourth admission in five weeks, each with symptoms of non-productive cough, wheezing, stridor, subcostal retractions, and mild oxygen desaturation. During the third admission, the infant had new radiographic evidence of right middle lobe pneumonia (Figure 1). The otolaryngology service was consulted and performed a flexible laryngoscopy which showed only diffuse erythema, tonsillar hypertrophy, and copious secretions. She was discharged from the hospital with a referral to a pediatric pulmonologist for evaluation of tracheomalacia.

Within a week, the child returned to the hospital with respiratory distress. It was noted on this admission that her pneumonia had resolved but weight loss and increasing signs of airway obstruction were noted. On hospital day two, a flexible bronchoscopy was performed that revealed extrinsic compression of the trachea three centimeters above the carina as well as diffuse tracheobronchitis. A barium swallow suggested an H-type TEF and the pediatric surgery service was consulted for evaluation.

Following this initial evaluation, the patient was taken to the operating room for rigid bronchoscopy on hospital day four. Anesthesia was induced by mask and was maintained with

oxygen and sevoflurane and supplemented with rocuronium and fentanyl. Rigid bronchoscopy demonstrated that the previously discovered compression was due to a mass, a solid object, hard resembling a tooth or a nail. Several attempts to remove the object were unsuccessful. The surgeons then performed an esophagoscopy. The infant was intubated and ventilated with positive pressure without difficulty. Esophagoscopy revealed a mass at the same level of the mass in the trachea with inflammatory changes that nearly occluded the esophagus. Human hair was visualized around the mass and, with concerns for a possible teratoma, biopsies were taken (Figure 2). The procedure was aborted pending further work-up and the infant was taken to the pediatric intensive care unit (PICU), sedated and ventilated.

On hospital day nine, the infant was taken back to the operating room, with little new information about the mass. CT scan of the chest had revealed a soft tissue density resembling the thymus and pathological evaluation of the surgical biopsy revealed reactive esophageal epithelium. No radio-opaque foreign body was seen on any of the preoperative studies. However, a repeat Barium swallow showed a definite TEF at the level of the second to third thoracic vertebrae. Conversations ensued between the surgical and anesthesia team to define the anatomical issues that were expected during the dissection as well as plans for crisis management during the subsequent procedure.

With a firm diagnosis of a tracheo esophageal fistula, the patient was taken to the operation room for definitive repair. Anesthesia was induced with sevoflurane, fentanyl and rocuronium. The patient was positioned in the left lateral decubitus position and a video assisted thoracoscopic (VATS) examination of the chest was performed. The fistula was not visualized and was presumed to be high in the chest, possibly at the thoracic inlet. A chest tube was placed, the VATS aborted and the infant was re-positioned in the supine position and a supraclavicular incision and partial sternotomy was performed.

After careful dissection, the mass was located at the level of the carina. Examination of the left side of the trachea revealed a large defect that was being occluded by the foreign body. The mass was removed producing an open defect in the trachea at the level of the carina through which all ventilating gas escaped. With direct laryngoscopy and help from the surgeons, the in situ 4.0 ETT could not be advanced past the open fistula into the right mainstem bronchus. Attempts to pass a new ETT directly through the surgical field were similarly unsuccessful. The infant was quickly extubated and bag valve mask ventilation was used to recover the oxygen saturations with the surgical team occluding the hole at the carina. Direct laryngoscopy was then repeated. With assistance from the surgeons on the field, a 3.0 ETT was advanced into the right mainstem bronchus. The ETT was held in place by the anesthesiologist for the remainder of the operation. Manual ventilation was continued for the remainder of the repair because of constant changes in airway compliance. The defect involved 75% of the trachea including proximal portions of the left and right mainstem bronchi. The foreign body was a plastic ring that had had a lollipop candy on top, likely until just before ingestion. (Figure 3) The separation of the esophagus and trachea and the subsequent closure of the fistula were uneventful. The infant was transferred back to the PICU in stable condition. She was maintained on low-pressure ventilation with sedation and was extubated ten days later. This allowed sufficient time for primary healing of the tracheobronchial tree and post operative radiologic confirmation of resolution of the acquired tracheo-esophageal fistula.

Subsequently, the child was discharged home on oral feedings with supplementation per gastrostomy. These were weaned over the next month. The child returned 10 months later with a mild esophageal stricture and food bolus that was removed via flexible esophagoscopy. Esophageal

dilation was performed at that time. The child is well at 18 months post surgery.

## DISCUSSION

Acquired tracheoesophageal fistula (TEF) is a rare complication of foreign body ingestion, and most commonly occurs when older children ingest button-type batteries or coins <sup>(1,2,3)</sup>. To our knowledge, there have been no reports of an acquired tracheoesophageal fistula in an infant. This is of note because the small size of the airway in children less than one year of age can readily and rapidly produce devastating hypoxic injury during attempts to diagnose and make the necessary anatomic repairs. We believe that this child was “fed” the foreign body by her older sibling weeks before presentation for recurrent “upper respiratory infections”.

According to the American Association of Poison Control Centers for the year 2005, there were 5100 cases of non-automotive battery ingestion and 12,740 cases of ingestion of toys or coins in children less than 6 years of age <sup>(4)</sup>. Despite this huge volume, outcomes are usually good. There were 16 major reaction outcomes and 1 death from battery ingestion and 5 major reaction outcomes and 0 deaths from coin or toy ingestion <sup>(4)</sup>. Many of these ingestions are not witnessed, and it has been shown that nearly 50% of children with known foreign body ingestion are asymptomatic <sup>(3)</sup>. Thus it is likely that the true number of uneventful foreign body ingestions in children is much higher.

As complications from foreign body ingestion are a rare occurrence, so too is the incidence of TEF. The most common TEF in an infant is a Type C congenital defect giving rise to proximal esophageal atresia (EA) and a distal esophageal fistula to the trachea. This defect occurs with an incidence of 1 in 4000 neonates <sup>(5)</sup>. Of the five described types of EA, the H-type which is TEF without EA, similar to the case we present here, occurs in 4% of cases, or, roughly 1 in 100,000 neonates. More commonly reported in the literature, acquired TEF is seen following prolonged mechanical ventilation using a cuffed endotracheal tube or in burn victims <sup>(3)</sup>. In congenital or acquired TEF, surgical closure is necessary <sup>(6)</sup>, presenting special difficulties for the anesthesiologist. The first clue that this child did not have a congenital H-type TEF was that the location of the fistula was at the level immediately above the carina and not at the thoracic inlet.

Several cases of acquired TEF are reported in the literature but few address anesthetic management and none deal with

the special issues attendant to a child this small. Nevertheless, the anesthetic management of TEF has been discussed as far back as 1966, perhaps even earlier (<sup>7</sup>). In adults, the use of a double-lumen endotracheal tube for the anesthetic management of TEF, whether traumatic or acquired, has been described (<sup>8,9,10</sup>). One-lung ventilation in children is limited by the size of the double lumen endotracheal tube, recognizing that resistance to flow increases exponentially as diameter decreases. In neonates, Andropoulos et al published results from a large series of elective TEF repairs (<sup>11</sup>). Their recommendation for airway management is similar to many single case reports in the literature. After induction and muscle paralysis, the endotracheal tube is placed in the trachea beyond the TEF. In this case placement of the ETT distal to the foreign body was not possible, increasing the risk of ventilating the fistula and producing ventilatory compromise. If the TEF is large, insertion of a Fogarty embolectomy catheter into the esophagus to occlude the TEF (<sup>11</sup>) can reduce the risk of respiratory embarrassment. The literature for TEF management outside of the neonatal period has not been reported in a large scale series, but a few case reports have been published. Most, if not all of these cases represent H type fistulas that are not diagnosed until the child suffers multiple and recurrent lower respiratory tract infections.

One-lung ventilation with a single lumen ETT in children with TEF also seems to be a commonly described technique, although other alternatives have been proffered. For instance, Somerville et al reported the use of cardiopulmonary bypass in a 2 year old that developed complete airway obstruction during surgical manipulation of an aspirated foreign body (<sup>12</sup>). In the case that we report we too completely lost the ability to ventilate the patient at the point of foreign body removal. Fortunately, we were able to guide a smaller endotracheal tube through the larynx and into the right mainstem bronchus through the surgical field before the situation became catastrophic.

Jacob et al described the use of spontaneous ventilation in the lateral decubitus position during repair of a large traumatic TEF (<sup>13</sup>). Unlike the case we present, the fistula in that case was open and could not be occluded by artificial means. In our patient, the foreign body lodged between the esophagus and the carina created an air tight seal that allowed positive pressure ventilation. The presence of this seal was key to the management of ventilation and oxygenation during the procedure. In a strikingly similar case, Robins et al reported the anesthetic management of an

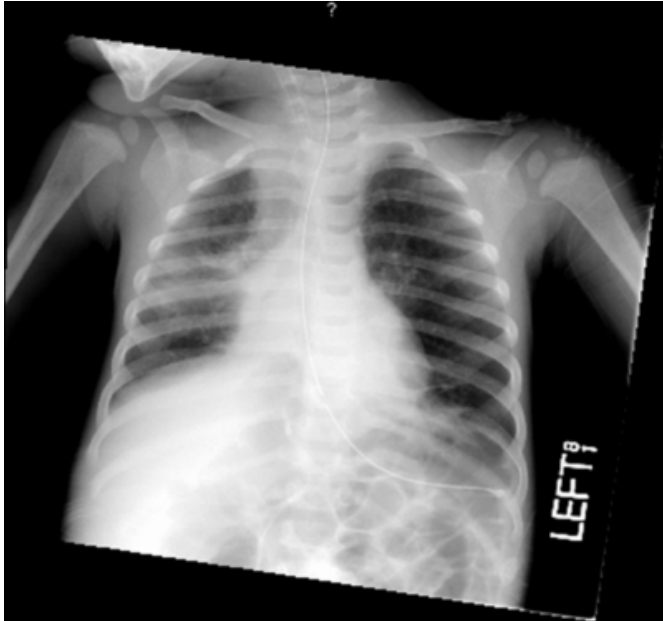
acquired TEF in a 15 month old (<sup>14</sup>). However, in their case, the communication between the trachea and esophagus was present preoperatively, and was not created during the sudden removal of the foreign body.

The issue of communication between the anesthesia and surgical teams prior to taking the patient to the operating room was a key element in a successful outcome and deserves to be highlighted. Assuring that every member of the team understands the anatomic relationships, the expected course of the procedure and the possible consequences of issues unforeseen is best practice with every patient, but certainly with those where manipulation of the airway and great vessels in a small space is expected. Industries other than medicine, in which the outcome of a error could be devastating, such as airlines and nuclear power, view a comprehensive time out prior to initiation of a procedure as sacrosanct. The Joint Commission for the Accreditation of Healthcare Organizations has encouraged communication within the perioperative team prior to the surgical procedure and views a time out as the Universal Protocol. Crew resource management, actually training the anesthesiologist, the surgeon and the nurse together prior to a surgical crisis takes the Universal Protocol to the next level by providing time for comprehensive discussion of the roles that each will play in the event of a crisis.

To our knowledge, this is the youngest patient in which a traumatic TEF has been reported. In addition, this is the only reported case of emergent intraoperative initiation of one-lung ventilation following traumatic creation of a large TEF. Continuous communication between the pediatric surgeon and the pediatric anesthesiologist prior to the surgical procedure and during the critical period when the trachea was opened was a key to the excellent outcome for this child. Had this robust communication not been present, the outcome would certainly have been devastating.

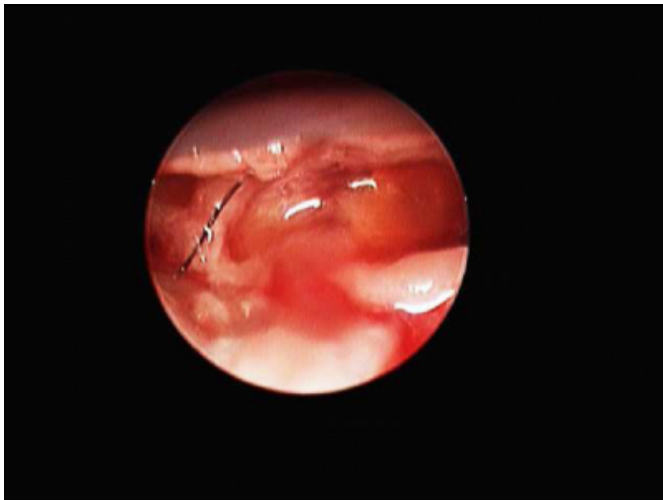**Figure 1**

Figure 1: Resolving Right Middle Lobe Pneumonia



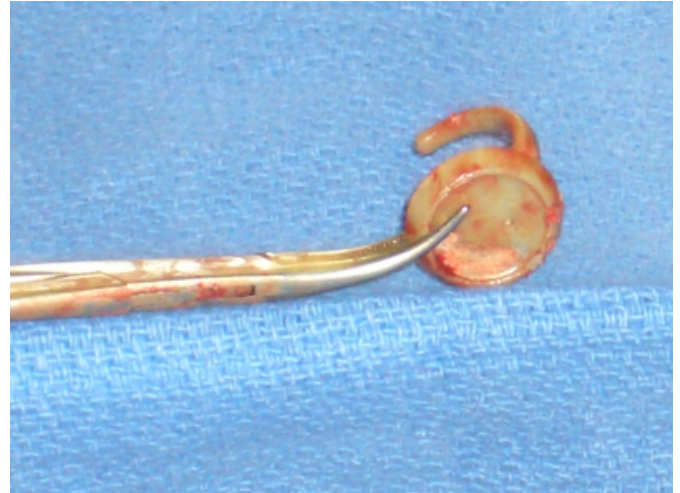**Figure 2**

Figure 2: Mass with hair



**Figure 3**

Figure 3: Retrieved lollipop ring



### CORRESPONDENCE TO

Department of Anesthesiology Room N202, UKMC,  
Lexington, KY 40536-0293 Phone (859) 323-5956; fax  
(859) 323-1080; Email: aredd2@email.uky.edu

### References

1. Imamoglu M, Cay A, Kosucu P, Ahmetoglu A, Sarihan A. Acquired tracheo-esophageal fistulas caused by button battery lodged in the esophagus. *Pediatr Surg Int.* 2004; 20:292-294.
2. Szold A, Udassin R, Seror D, Mogle P, Godfrey S. Acquired tracheoesophageal fistula in infancy and childhood. *J Pediatr Surg.* 1991; 26:672-75.
3. Arana A, Hauser B, Hachimi-Idrissi S, Vandenplas Y. Management of ingested foreign bodies in childhood and review of the literature. *Eur J Pediatr.* 2001; 160:468-72.
4. Lai MW, Klein-Schwartz W, Rodgers GC, Abrams JY. 2005 Annual Report of the American Association of Poison Control Centers National Poisoning and Exposure Database. *Clin Toxicol.* 2006; 44:803-932.
5. Orenstein S, Peters J, Khan S, Youssef N, Hussain SZ. In Behrman: Nelson's Textbook of Pediatrics, 17th ed. 2004; 1219-20.
6. Zwischenberger JB, Savage C, Bhutani, MS. Townsend: Sabiston Textbook of Surgery, 17th ed. 2004; 1797-98.
7. Johnston AE, Conn AW. The anaesthetic management of tracheo-oesophageal fistula: a review of five years' experience. *Can Anaesth Soc J.* 1966; 13:28-39.
8. Horishita T, Ogata J, Minami K. Unique anesthetic management of a patient with a large tracheoesophageal fistula using fiberoptic bronchoscopy. *Anesth Analg.* 2003; 97:1852-8.
9. Reed WJ, Doyle SE, Aprahamian C. Tracheoesophageal fistula after blunt chest trauma. *Ann Thorac Surg.* 1995; 59:1251-56.
10. Chan CS. Anaesthetic management during repair of tracheo-oesophageal fistula. *Anaesthesia.* 1984; 39:158-60.
11. Somerville NS, Mearns C, Chin C, Blaney S, Anderson D. Anesthetic management of the complications of previously undiagnosed ingested foreign body in a pediatric patient. *Ped Anes.* 2004; 14:1023-26.
12. Jacob R, Kunder S, Mathai J, Chacko J, John V. Traumatic tracheoesophageal fistula in a 5-year old. *Ped*

Anes. 2006; 16:1068-72.

13. Andropoulos DB, Rowe RW, Betts JM. Anesthetic and surgical management during tracheo-oesophageal fistula

repair. Paediatr Anaesth. 1998; 8:313-19.

14. Robins B, Das AK, Anesthetic Management of Acquired Tracheoesophageal fistula: A brief report. Anesth Analg. 2001; 93:903-5.

**Author Information**

**Arundathi Reddy, MBBS**

Departments of Anesthesiology and Surgery, University of Kentucky Medical Center

**Joseph A. Iocono, MD**

Departments of Anesthesiology and Surgery, University of Kentucky Medical Center

**Raeford E. Brown Jr., MD**

Departments of Anesthesiology and Surgery, University of Kentucky Medical Center