

Iron Deficiency Anaemia In Infancy Presenting As A Stroke

A Al-Hmadi, F Abouriana, A Karra, H Darrat, A Zeglam

Citation

A Al-Hmadi, F Abouriana, A Karra, H Darrat, A Zeglam. *Iron Deficiency Anaemia In Infancy Presenting As A Stroke*. The Internet Journal of Pediatrics and Neonatology. 2006 Volume 7 Number 2.

Abstract

We report the case of a 6 months old girl who developed left sided hemiplegia following an infarction of the area supplied by the Thalamus Striat artery (caudate body and lentiform nuclei). She presented with sudden loss of power involving the left side of her body associated with deviation of her mouth to the right. Investigations revealed reactive thrombocytosis secondary to iron deficiency anaemia (IDA) as the cause of her cerebrovascular accident (CVA). IDA produces many common systemic abnormalities but CVA is rarely mentioned as a possible presenting feature.

CASE REPORT

A 6 month old girl was born after a normal pregnancy and delivery. Her parents and siblings were healthy. She was well until presented with sudden loss of power involving left side of her body associated with deviation of her mouth to the right (Fig.1). When she was first seen at the hospital she was in mild distress. No documented fever was detected or convulsion at the time. Her muscle tone was increased on the left side with reduced muscle power (Grade 2) and reflexes were brisk on both sides. Her mouth deviated to the right when she was crying. The rest of her systemic examination was unremarkable.

Initial investigations revealed: Platelets ($1042 \times 10^3 / \mu\text{L}$), haemoglobin (8.5g/dL), MCV (66.7fL), MCH (20.4pg) MCHC (30.6 g/dL). A peripheral smear showed microcytic hypochromic anaemia with an anisocytosis and increased platelets. No blast cells were seen. Brain MRI with an Angiogram was undertaken within 48 hours and showed an infarction of the area supplied by the Thalamus Striat artery (caudate body and lentiform nuclei) (Fig.2). Cardiac echocardiogram was normal. Her conscious level and vital signs were regularly assessed. Furthermore, other investigations (Pasteur Cerba Laboratory, Cedex, France) showed a normal bleeding profile and a negative sickle cell test. Erythrocyte sedimentation rate was 10mm/h. Homocysteine level 2.00 mg/L (normal value less than 2.00mg/L), Anti-cardiolipin Ab, IgG 22U GPL/ml (15-100U GPL/ml=significant level), Antiphospholipid Ab, IgG less than 10GPL/ml (<10UGPL/ml=absence of antibodies), Fibrinogen 1.54g/L (normal value 2-4), Antithrombin activity 120% (80-120), Protein C activity

99% (80-130), Protein S activity 82% (60-130), Factor V (Leiden) was normal and serum ferritin 5 ng /mL (4 – 161 ng / mL).

We made a provisional diagnosis of CVA caused by either vascular event or brain tumour and the patient was managed according to the guideline published by the royal college of physicians and appraised by the royal college of paediatrics and child health.

The infant was started on Aspirin (5mg/kg/day) and subcutaneous Low-molecular-weight heparin (100U/kg/day). She had been evaluated by the physiotherapy department and a programme of rehabilitation has been arranged which consisted of muscle strengthening activities to improve functional activity.

After one days of starting treatment, the infant developed minor muscle twitches involving mainly the left side of her body for which she was started on intravenous phenobarbitone. No more twitches seen since.

A diagnosis of reactive thrombocytosis secondary to iron deficiency anaemia was made and it is believed that her neurological manifestations were all due to these problems. The infant was started on oral iron therapy and by the second week her platelets count started to return to normal. Her last and the most recent platelets count was $281 \times 10^3 / \mu\text{L}$ and haemoglobin 12.2 g/dL.

The infant was discharged on oral phenobarbitone and aspirin. An intensive programme of physiotherapy has been arranged for her. On follow up, she has been well and

asymptomatic. Phenobarbitone and aspirin were tailed off and discontinued after six months as all of her blood parameters were normal.

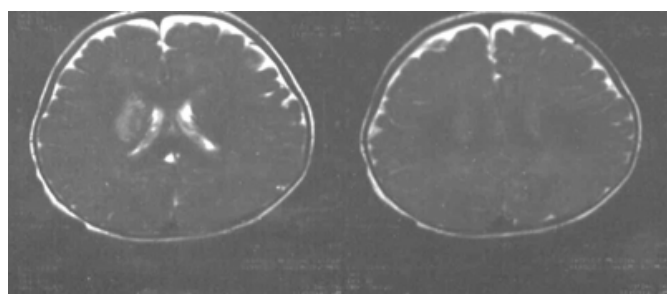
Figure 1

Figure 1: photograph showing left -side hemiparesis. The infant is not able to use his left arm. Consent for this photograph was obtained from the parents.



Figure 2

Figure 2: Right basal ganglia infarction (caudate body and lentiform nuclei).



DISCUSSION

CVA in infancy and childhood is still regarded as a rare event and therefore knowledge of aetiology, diagnosis and management is limited among general Paediatricians. The estimated yearly incidence of stroke in childhood is between 3-8 per 100,000^{2,3}. Reactive thrombocytosis is common and usually transient in children. Thrombotic or haemorrhagic complications secondary to thrombocytosis are rare despite of strikingly high platelet count. Reactive thrombocytosis is mediated by increased release of a number of cytokines (IL-6, thrombopoietin, IL-3, IL11, GM-CSF) in response to infections, inflammation, vasculitis and tissue trauma. Although thrombocytosis in association with IDA is well

documented, the mechanism remains unclear. A recent study showed that an elevation of erythropoietin, although observed in thrombocytosis patients with IDA, had no correlation with platelet count. The frequency of reactive thrombocytosis is far more common than essential thrombocytosis and depends on age. Rates are highest during the first 3 months of life⁴. No evidence suggests that the incidence of either primary or reactive thrombocytosis vary significantly from one country to another or from one ethnic group to another⁵.

We publish this case report to highlight the importance of screening for IDA in infants and children who present with unexpected CVA. CVA in a child is a serious condition that may adversely effect the child's development as well as the future management and counselling of the family⁴.

ACKNOWLEDGEMENT

We would like to acknowledge DR. S Zerti and the physiotherapy department in Al-Khadra hospital for their contribution to the infant's care. We are also grateful to the nursing staff in the Paediatric department for their help. We thank all intern doctors for their assistance with literature searching. We thank also Dr. N Yahya and Dr. B Bezan for the medical photographs.

CORRESPONDENCE TO

Dr. A M Zeglam, (MBBCh, DCh, MRCPCH, FRCPI)
Consultant Neurodevelopment Paediatrician Associate
Professor of Paediatrics and Child Health, Department of
Paediatrics Al-Khadra Teaching Hospital PO BOX 82809
Tripoli, Libya, zeglama@yahoo.com

References

1. Royal College of Physicians- Clinical Guidelines for Diagnosis and Management of Stroke in Children, 2004.
2. Giroud M, Lemesle M, Gouyon JB, Nivelon JL, Milan C, Dumas R. Cerebrovascular disease in children under 16 years of age in the city of Dijon, France: a study of incidence and clinical features from 1985 to 1993. *J Clin Epidemiol* 1995;48(11):1343-8.
3. Lynch JK, Hirtz DG, DeVeber G, Nelson KB. Report of the National Institute of Neurological Disorders and Stroke workshop on perinatal and childhood stroke. *Pediatrics* 2002;109(1):116-23.
4. Sutor AH. Screening children with thrombosis for thrombophilic proteins. *Cui bono? J Thromb Haemost* 2003;1(5):886-8.
5. Schneppenheim R, Greiner J. Thrombosis in infants and children. *Hematology Am Soc Hematol Educ Program* 2006:86-96.

Author Information

A. Al-Hmadi

Registrar in Paediatrics, Al-Khadra Teaching Hospital

F. Abouriana

Registrar in Paediatrics, Al-Khadra Teaching Hospital

A. Karra

Specialist in Paediatrics, Al-Khadra Teaching Hospital

H. Darrat

Senior House Officer in Paediatrics, Al-Khadra Teaching Hospital

A.M. Zeglam

Consultant Neurodevelopment Paediatrician, Associate Professor of Paediatrics and Child Health, Department of Paediatrics and Child Health, Al-Khadra Teaching Hospital