

Giant cell tumour of the sphenoid bone – Lefort 2 approach for surgery

A Gupta, B Walia, A Wani, A Jha, S Vaishya, V Gupta

Citation

A Gupta, B Walia, A Wani, A Jha, S Vaishya, V Gupta. *Giant cell tumour of the sphenoid bone – Lefort 2 approach for surgery*. The Internet Journal of Neurosurgery. 2008 Volume 5 Number 2.

Abstract

Giant cell tumour is one of the rare tumors of the sphenoid bone. The tumour usually has delayed presentation due to late onset of symptoms. The excision is relatively difficult due to narrow corridors available for surgery. We have described here our experience with use of Le Fort 2 osteotomy in removal of the tumour. Despite having adequate corridor, we could not achieve total excision and had to administer adjuvant therapy for control of disease.

INTRODUCTION

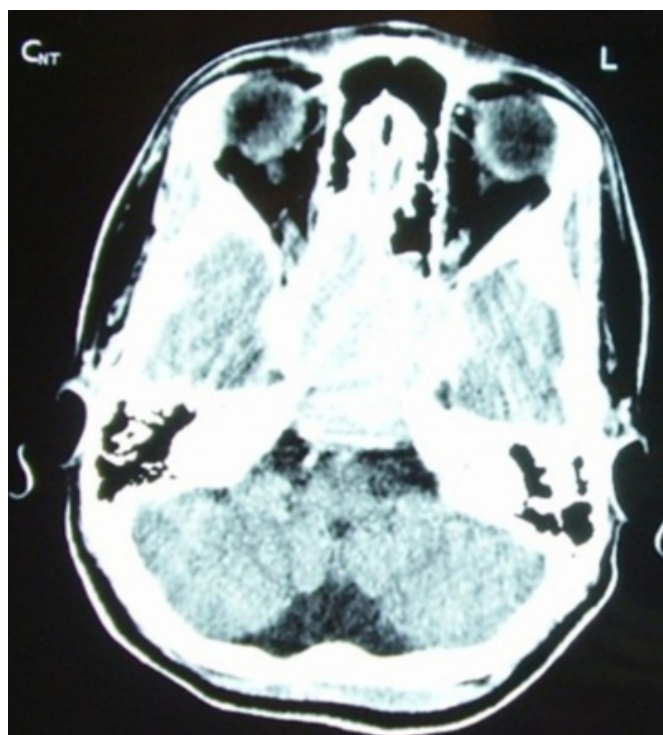
Giant cell tumour (GTC) is primarily a tumor of long bones of uncommon variety, accounting for less than 5% of all bony tumors. [1,6,9,18] They are rarely located in cranium, where it usually affects sphenoid and temporal bones. [18] GCT of the sphenoid bone accounts for 1-2 % of all Paranasal sinus tumors. [7,5] GCT of sphenoid may present initially with non-specific symptoms like headache. The patient can have cranial nerve palsies, endocrinopathy due to involvement of pituitary. [16,12,14,15] The tumor may spread to involve orbit or laterally into sub-temporal region or may enlarge posteriorly with compression of brain stem. The removal of such tumors is difficult because of its location and limited access. Various skull base approaches have been described to remove these tumors. [15]

CASE REPORT

A 24-year-old female presented in our hospital with history of headache for and diplopia on seeing towards left side for past two months. She had left sixth cranial nerve palsy. There was no other neurological deficit. CT scan revealed a large tumour measuring 5.4x6.2x5.5 cm involving sphenoid bone, extending to clival-basiocciput region, and eroding the sella. (Figure 1)

Figure 1

Figure 1: CT scan showing tumour-involving sphenoid bone, extending to clival-basiocciput region, and eroding the sella



MRI defined the extent of tumour filling the sphenoid sinus and eroding the sellar floor and the mass was abutting the cavernous sinus, predominantly involving the left side, eroding the clinoids on left side, and inferiorly involving whole of clivus. (Figure 2a, b)

Figure 2

Figure 2a,b: MRI showing tumour filling the sphenoid sinus and eroding the sellar floor extending to involve whole of clivus

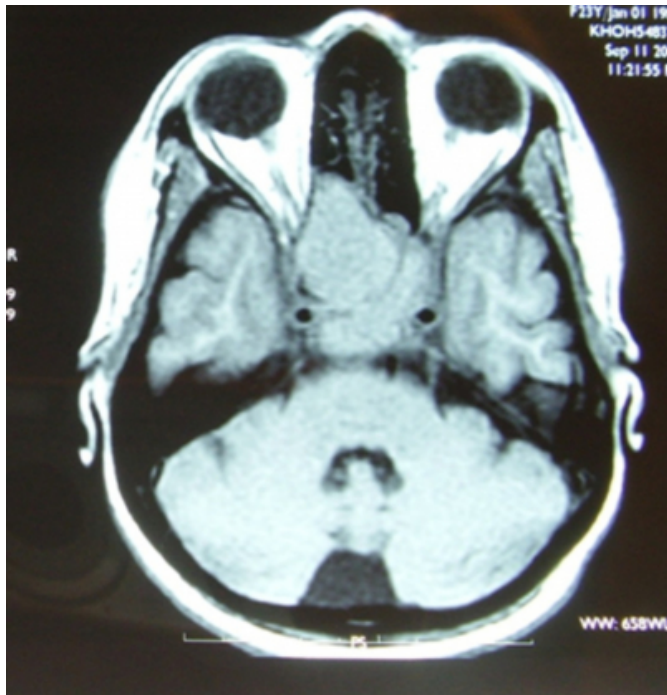
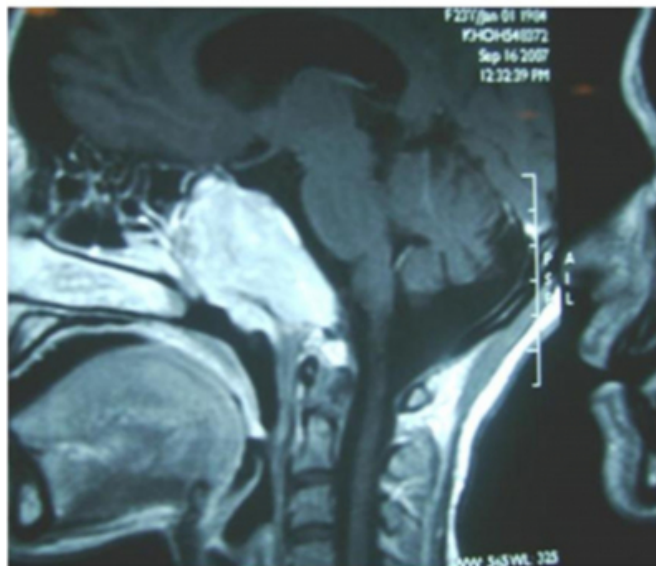


Figure 3

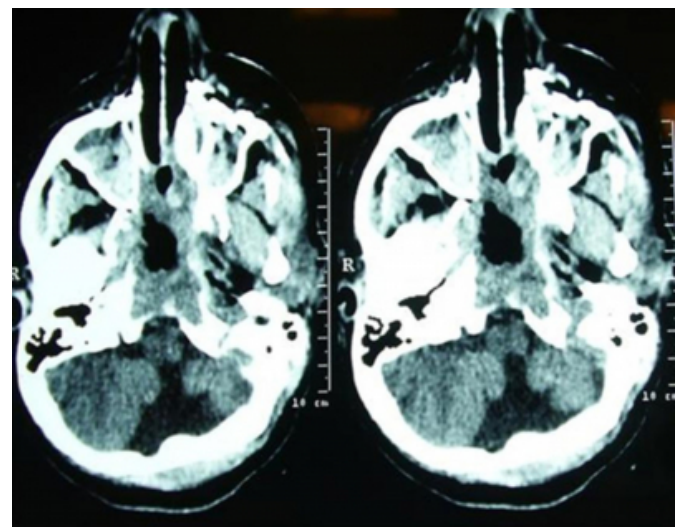


Tumour was encroaching carotid arteries bilaterally. A pre op angiogram was done which showed vascular tumour with bilateral blood supply. Complete endocrinal profile was done which was normal. Serum electrolytes, calcium and phosphates were also normal. Before coming to this hospital, she had already undergone trans-nasal biopsy of the lesion, which was suggestive of Giant cell tumour.

The patient was operated through transfacial approach with Weber Fergusen incision with lip split with bilateral front maxillary swing and Le Fort 2 osteotomy. Midpalatal split with sphenoidotomy was also done for exposure. The tumour excision was done but the tumour was vascular and once posterior part was reached, there was lot of bleeding and we decided not to remove the tumor further in this sitting. Her post op recovery was good with no new neurological deficits. Postoperative CT scan revealed presence of residual tumour. (Figure 3)

Figure 4

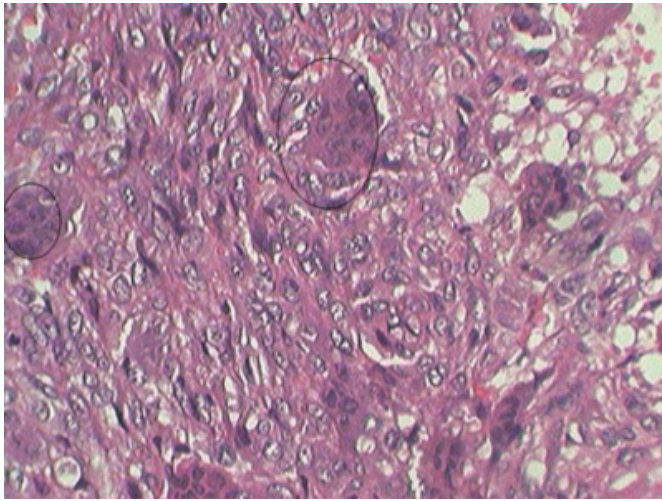
Figure 3: Postoperative CT scan showing residual tumour



She was advised re-surgery but she refused and hence she was referred for gamma knife surgery. The histopathological examination revealed presence of tumor composed of two cell population. The mononuclear cells were oval to spindle shaped with eosinophilic cytoplasm arranged in sheet like pattern. The giant cells were distributed throughout the lesion with focal clustering at periphery. Giant cell nuclei were upto twenty in number. There was no abnormal mitosis or nuclear atypia (Figure 4). Hence, diagnosis of giant cell tumor was made.

Figure 5

Figure 4: Microscopic appearance of the tumour showing multiple giant cells (having numerous nuclei) with interspersed spindle cells



DISCUSSION

The tumors are usually homogenous and hyper dense enhancing on contrast. [11] Bony tissue is destroyed by the tumour with local mass formation. The various approaches described in literature for this tumour involve midfacial approaches (Transoral, transpalatal, lateral rhinotomy and midfacial degloving) and lateral approaches include infratemporal approach. Each procedure has certain advantages and disadvantages. [15]

GCT involves sphenoid bone possibly because it is derived from endochondrium. [13] These are locally aggressive tumors with variable malignant potential, and are vascular tumors with multiple giant cells seen. They usually arise from epiphysis of long bones and rarely involve skull. [9,6,1,18]. GCT is extradural tumour with a rare intradural involvement. [4] Le Fort osteotomy was first described by Langenbeck which was later on modified. [15] The combination of trans palatal and bilateral maxillary

swing with Le Fort 2 osteotomy allowed us an extensive exposure of the tumor which could not be provided by Le Fort1 osteotomy.

The diagnosis of GCT is based on histopathological examination. The tumour consists of multinucleate giant cells, which are evenly distributed amongst smaller spindle shaped cells. The extent of mitosis is variable. The main differential diagnoses are from tumors of hyperparathyroidism, giant cell reparative granulomas, aneurysmal bone cyst, and the bone invading tumors like

chondrosarcoma, chordoma and fibrous dysplasia. [17,18]

The giant cell reparative granuloma is a reaction to trauma and intraosseous hemorrhage. They have clumping of giant cells around the areas of hemorrhage unlike in GCTs. Besides GCT is found in age group of 25-40 years, while reparative granuloma is usually seen in patients younger than 20 years of age. The present lesion did not have blood filled cavernous spaces; hence, aneurysmal bone cyst is excluded. Brown tumors of hyperparathyroidism are excluded as clinical features of hyperparathyroidism were not there and serum calcium was normal.

Fibrous dysplasia and cartilage forming tissues are also excluded here, as there was absence of foci of osteoid and bone formation and there were no mitotic figures seen. [17,18,2]

The goal of surgery is total removal but this is not always possible due to involvement of adjoining structures especially carotids. The brisk bleeding we encountered was also one of the contributing factors that limited the extent of removal that we could achieve. The best option available for residual tumour is re-exploration; however, in certain cases radiotherapy has been given. The role of radiotherapy is highly controversial, as it has been

seen to induce malignant changes. [1783] Since our patient refused second surgery and there was significant residual tumour we performed gamma knife surgery to the residual tumour.

CORRESPONDENCE TO

Dr. Abrar Ahad Wani Consultant, Department of Neurosurgery, Max superspeciality hospital, Saket. New Delhi E-mail: abrarwani@rediffmail.com

References

1. Abrar Ahad Wani, Makhan Lal Babu, Altaf Ahmad Kirmani, Altaf Umer Ramzan, Abdul Rashid Bhat, Syed Shafiq Alam, Altaf Ahmad, Khalil Mohammad Baba. Giant Cell tumor of axis- a rare entity. *Journal of Pediatric Neurology* 2007;5: 351-354
2. Aldo Spallone, Gerardo Lopez Flores, Luis Ochoa Zaldivar, Barbara Estupinam. Giant Cell Tumor (Osteoclastoma) of the petrous Bone: Case Report. *Skull Base surgery* 1999; 9(2):155-159
3. Brimo F, Aziz M, Rosen G, Turcotte R, Nahal A. Malignancy in giant cell tumour of bone: is there a reproducible histological threshold? A study of three giant cell tumours with worrisome features. *Histopathology*. 2007; 51(6):864-6.
4. Dahlin DC, Cupps RE, Johnson EW Jr. Giant-cell tumor: a study of 195 cases. *Cancer*. 1970 ; 25(5):1061-1070.
5. De Monte F, Ginsberg LF, Clayman GL.. Primary

- malignant tumors of the sphenoid sinus .Neurosurgery 2000; 46(5):1084-91;
6. Elder JB, Berry C, Gonzalez- Gomez I, Kreger MD, Mc Comb JG. .Giant cell tumor of the skull in pediatric patients. Report of two cases. J Neurosurg. 2007; 107(1):69-74
7. Esposito F, Kelly D F, Vinters HV, De Salles AA, Sercarz J, Gorgulhos AA. Primary Sphenoid sinus neoplasms: a report of four cases with common clinical presentation treated with transsphenoidal surgery and adjuvant therapies. J Neurooncol.2006 ; 76(3):
8. Findlay JM, Chiasson D, Hudson AR, Chui M. Giant-cell tumor of the middle cranial fossa. Case report. J Neurosurg. 1987; 66(6):924-928 .299-306.
9. Goldenberg RR, Campbell CJ, Bonfiglia M. Giant-cell tumor of bone: An analysis of two hundred eighteen cases. J Bone Joint Surg (Am) 1970; 52:619-664
10. Keith A. Kattner, Ann Stroink,Kundan Gupta, Takanori Fukushima, Chinbang Li. Giant cell tumor of the Sphenoid Bone .Skull Base Surgery 1999; 9(2):155-159
11. Kioumehri F, Rooholamini SA, Yaghmai I, Hoover L, Arnold A, Hannah J, Rodriguez L. Giant-cell tumor of the sphenoid bone: case report and review of the literature. Can Assoc Radiol J. 1990; 41(3):155-157
12. Ohaegbulam SC, Gupta IM. Giant cell tumour of the sphenoid bone with dural extension. J Neurol Neurosurg Psychiatry 1977; 40:790-794
13. Pitkethly DT, Kempe LG. Giant-cell tumors of the sphenoid. Report of two cases. J Neurosurg 1969;30:304-3 10
14. Suster S, Porges R, Tobias J, Nanes M. Giant-cell neoplasm of the sphenoid bone. Mt Sinai J Med (NY) 1989; 56:118-122
15. Tyler MLewark, Gregory C.Allen,Khalid Chowdhury, Kenny H.Chan.Le Fort Osteotomy and skull base tumors- A pediatric Experience .Archives of otolaryngology-Head and neck surgery.2000;126(8);1004-1008
16. Vernet O, Ducrey N, Dervaz JP, Tribolet N. Giant cell tumor of the orbit. Neurosurgery 1993; 32:848-851
17. Watkins LD, Uttley D, Archer DJ, Wilkins P, Plowman N. Giant cell tumors of the sphenoid bone. Neurosurgery. 1992; 30(4):576-581
18. Wolfe JT 3rd, Scheithauer BW, Dahlin DC. Giant-cell tumor of the sphenoid bone. Review of 10 cases. J Neurosurg. 1983; 59(2):322-327.

Author Information

Ashish Gupta, MCh

Department of Neurosurgery, Max Superspeciality Hospital

Bipin S. Walia, MCh

Department of Neurosurgery, Max Superspeciality Hospital

Abrar Ahad Wani, MCh

Department of Neurosurgery, Max Superspeciality Hospital

AN Jha, MS, FRCS

Department of Neurosurgery, Max Superspeciality Hospital

Sandeep Vaishya, MCh

Department of Neurosurgery, Max Superspeciality Hospital

Vipul Gupta, MD

Department of Neurosurgery, Max Superspeciality Hospital