

Systemic Wegener's Granulomatosis Involving The Testes

A Patnaik, N Mirza, H Roppelt

Citation

A Patnaik, N Mirza, H Roppelt. *Systemic Wegener's Granulomatosis Involving The Testes*. The Internet Journal of Internal Medicine. 2009 Volume 9 Number 1.

Abstract

We report a patient with biopsy proven ANCA positive Wegener's granulomatosis (WG) of the lung who also presented with testicular pain. Ultrasound of the scrotum showed bilateral intra testicular masses with hypoechoic densities. Testicular tumour markers were negative. The patient was treated empirically for possible orchitis with antibiotics with no improvement in symptoms. The patient also received treatment with immunosuppressants and steroids for Wegener's granulomatosis with improvement in his overall symptoms. Since he refused a testicular biopsy, a repeat sonogram of the scrotum was obtained after four months. The scrotal sonogram showed complete resolution of the hypo echoic densities suggesting probable testicular involvement with Wegener's granulomatosis which responded to immunosuppressive treatment.

INTRODUCTION

Wegener's granulomatosis is a systemic necrotizing vasculitis of unknown etiology and typically involves the upper and lower respiratory tracts and the kidneys (1). The diagnosis of Wegener's granulomatosis is made by histological demonstration of vasculitis: granulomatous inflammation and necrosis in involved organs. The urogenital tract other than the kidneys is involved in less than 1 % of cases (2).

We describe the clinical course and the sonographic characteristics of testicular vasculitis in a patient with systemic Wegener's granulomatosis involving both the lungs and testes. Given the ease of doing a testicular biopsy over an open lung biopsy, the testis may be biopsied if vasculitic involvement is suspected (though our patient refused this procedure).

CASE REPORT

A 62 year old Caucasian male presented with generalized myalgias, fatigue, cough productive of yellow sputum and testicular pain ongoing for one week. The patient's medical history was significant for chronic kidney disease attributed to hypertension. His surgical history included cauterization for management of epistaxis in 2004 and 2008, resection of a ureteral polyp which per histology was inflammatory in nature, and a splenectomy secondary to trauma related to a motor vehicle accident. His review of systems was negative for conjunctivitis, hearing difficulties, sicca symptoms, hemoptysis, arthralgias or raynaud's phenomenon. His social

history revealed occupational related asbestos exposure and a 30 pack year history of smoking.

His physical examination demonstrated a chronically ill appearing male. Examination of the head and neck was normal with no lymphadenopathy. Lung auscultation demonstrated bibasilar rhonchi. Cardiovascular and abdominal examination was normal. No rash was noted. Musculoskeletal examination did not show evidence of synovitis or joint swelling. There was mild bilateral scrotal swelling and tenderness with no inguinal lymphadenopathy.

Laboratory studies were significant for a normocytic anemia (hemoglobin of 9.6 g/dl) leukocytosis, and thrombocytosis. Creatinine kinase was normal. Rheumatoid factor was negative. Liver function tests were normal. Serum creatinine was 1.36 mg/dl [normal range 0.8 – 1.50 mg/dl]. Urinalysis demonstrated hematuria [RBC 10-25 hpf] and proteinuria [total protein in urine was 65.2 mg/dl]. No red blood cell casts were observed. Urine and blood cultures were negative. Erythrocyte sedimentation rate was 48mm/hr, [normal 0-15] C reactive protein was high at 192 mg/dl [normal 0 – 0.5] and anti-proteinase 3 antibodies were positive [1:80]. Hepatitis B and C, HIV, and thyroid abnormalities were excluded.

A chest radiograph followed by computed tomography of the chest was obtained which showed bilateral lung opacities with a right upper lobe lung nodule. An open lung biopsy of the right lung nodule was obtained and demonstrated necrotizing granulomata with angitis and organizing

pneumonia- changes consistent with Wegener’s granulomatosis (Fig 1). Stains for acid fast bacilli and for fungi were negative.

A scrotal ultrasound was performed with a 10 MHz linear transducer to evaluate the patient’s testicular pain. The right testicle measured 4.1 x 2.7 x 2 cm. The left testicle measured 3.8 x 2.6 x 2.1 cm. No fluid collections were seen around the testes. Bilateral intra testicular hypo echoic areas were noted. Doppler evaluation of the testes showed patchy distribution of blood flow to both testicles (Fig 2). The differential diagnosis for these findings included malignancy (lymphoma), infection (orchitis) and testicular involvement of Wegener’s granulomatosis. Serum alpha fetoprotein and beta human chorionic gonadotropin levels were normal. The patient was treated with antibiotics for possible orchitis with no improvement in his testicular symptoms. He refused a testicular biopsy.

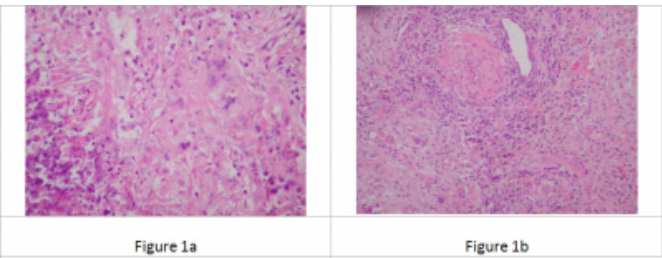
The patient was treated with a combination of oral cyclophosphamide and prednisone for Wegener’s granulomatosis. He showed marked clinical improvement and his testicular symptoms resolved. We repeated the scrotal sonogram four months later and noted complete resolution of the hypo echoic testicular masses (Fig 2).

PATHOLOGY (OPEN LUNG BIOPSY)

Necrotizing granulomata with angiitis and organizing pneumonia consistent with Wegener’s granulomatosis.

Figure 1

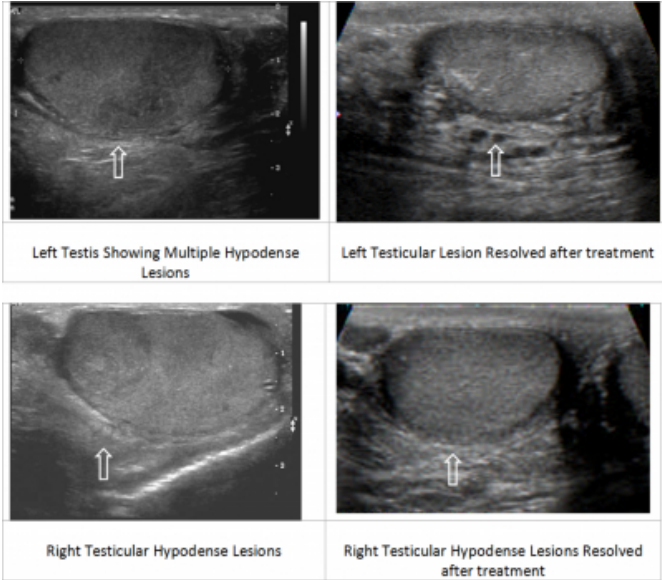
Figure 1 Open Lung Biopsy



SCROTAL ULTRASOUND

Figure 2

Figure 2 Scrotal Ultrasound



DISCUSSION

Wegener’s granulomatosis is characterized by necrotizing granulomatous vasculitis involving the upper and lower respiratory tracts and the kidneys (1) and generally affects caucasians in the fourth through sixth decades of life. Urogenital involvement other than kidneys is rare (less than 1 %) and when seen is normally confined to the prostate gland (2). The clinical presentation of WG usually consists of upper and lower airway symptoms (nasal obstruction, sinusitis, otitis, cough, hemoptysis, and dyspnea) and renal involvement (proteinuria with rapidly progressive glomerulonephritis).

Based on the 1994 Chapel Hill Consensus, the diagnosis of Wegener’s granulomatosis requires a tissue biopsy (usually a kidney biopsy) showing evidence of vasculitis demonstrated by granulomatous inflammation and necrosis in the involved organs (3).

Antineutrophil cytoplasmic antibodies (ANCA) are often positive in Wegener’s granulomatosis. The target antigen is proteinase-3(PR3) a serine protease found in the azurophilic granules of the neutrophils (4). The sensitivity of anti PR3 is 70-90% in classic Wegener’s and 65-70% in limited disease. The specificity ranges from 88-100% (5). However, some patients with Wegener’s granulomatosis do not have antinuclear cytoplasmic antibodies. Positive ANCA and specifically anti-proteinase-3 antibodies may help diagnose Wegener’s granulomatosis though tissue biopsy is advised to confirm the diagnosis (6). In our case, the anti-proteinase-3

antibodies were positive and the lung biopsy confirmed the diagnosis. The standard treatment of systemic Wegener's granulomatosis includes the combination of immunosuppressant (commonly oral cyclophosphamide) and steroids. The prognosis is poor if left untreated.

Urogenital involvement of Wegener's granulomatosis other than kidneys is extremely rare. Most cases of testicular vasculitis in the setting of ANCA associated disease occur in polyarteritis nodosa (38-86%), not Wegener's (10). Davenport et al. (7) described eight patients with Wegener's granulomatosis localized to the urogenital tract and two cases involving the testes. Scrotal skin, bladder, ureters, urethra, and penis were the other sites reported in their series. All of the patients in their series had limited WG localized to the urogenital tract unlike our patient with systemic WG. Agraharkar et al. (8) reported one patient who presented with hemoptysis and sensorineural hearing loss and was noted to have a pulmonary lesion and a painless right testicular mass. Wegener's granulomatosis was diagnosed in this latter case by testicular biopsy.

There is little literature describing typical ultrasound findings of Wegener's granulomatosis involving the testes. Fulgam et al described the sonographic appearance of a patient with isolated necrotizing vasculitis of the testis (9). The authors reported that the initial sonogram of the scrotum showed increased testicular blood flow with sharply delineated hypo echogenicity. The hypo echoic areas represented the absence of blood flow likely secondary to acute vasculitis with thromboses or acute hemorrhage and hematoma formation. Subsequently the hypo echogenic areas became 'more rounded' and showed subtle but detectable blood flow. This was due to reactive hyperemia with tissue necrosis surrounding the original lesions. On gross pathology the specimen confirmed that the hypo echoic areas on ultrasound examination of the scrotum corresponded to the areas of tissue necrosis.

In our case, we were not able to obtain a testicular biopsy as

the patient refused this procedure. However the bilateral testicular hypo echoic lesions in the initial sonogram likely represented vasculitic changes. Further support for this is the resolution of these lesions seen in the subsequent scrotal ultrasound following immunosuppressive treatment.

CONCLUSION

This case illustrates the need to consider testicular vasculitis in the differential diagnosis of any patient with WG presenting with testicular pain and no history of trauma or evidence of infection. The testes are very rarely involved in WG and this diagnosis may be missed, even if symptoms are present. If vasculitic involvement of the testes is suspected in systemic WG, a testicular biopsy should be performed, though the ultrasound findings described in this article may be sufficient to establish the diagnosis (8, 9).

References

1. Calabrese LH, Antineutrophil Cytoplasmic Antibody Associated Vasculitis, in Kelly's Textbook of Rheumatology, Saunders 2005
2. Yalowitz PA, Green LF, Sheps SG, Carlin MR, Wegener's granulomatosis involving the prostate gland: A report of a case, J urology 1996;96:801-804
3. Leavitt RY, Fauci AS, Bloch DA et al., The American college of Rheumatology 1990 criteria for the classification of Wegener's granulomatosis, Arthritis Rheum 1990;33:1101-1107
4. Van der Woude FJ, Rasmussen N, Lobatto S, et al., Autoantibodies against neutrophils and monocytes: tool for diagnosis and marker of disease activity in Wegener's granulomatosis. Lancet 1985;1:425-429
5. Rao JK, Allen NB Feussner JR et al., A prospective study of antineutrophilic cytoplasmic antibody and clinical criteria in diagnosing Wegener's granulomatosis, Lancet 1995
6. Langford CA, The diagnostic utility of c-ANCA in Wegener's granulomatosis, Cleve Clin J Med 1998;65;135-140
7. Davenport A, Downey SE, Goel S, Maciver AG, Wegener's granulomatosis involving the urogenital tract. Br J Urol 1996; 78; 354-357
8. Agraharkar M, Gokhale S, Gupta R, Wegener's granulomatosis diagnosed by testicular biopsy, Int Urol Nephrol 2003
9. Fulgam PF, Jensen P, Sonographic appearance of isolated necrotising vasculitis of the testis, Journal of clinical ultrasound 2006
10. Patalano VJ, Sommers SC. Biopsy diagnosis of periarteritis nodosa. Arch Path 1961;72:1

Author Information

Asha Patnaik, MD

Department of Medicine, Division of Rheumatology, Stony Brook University Medical Center

Naureen Mirza, MD

Department of Medicine, Division of Rheumatology, Stony Brook University Medical Center

Heidi Roppelt, MD

Department of Medicine, Division of Rheumatology, Stony Brook University Medical Center