

# Pyloric Leiomyoma - An Unusual and Very Rare Cause of Gastric Outlet Obstruction with Review of Literature

Nadeem-ul-Nazeer, A Bashir

## Citation

Nadeem-ul-Nazeer, A Bashir. *Pyloric Leiomyoma - An Unusual and Very Rare Cause of Gastric Outlet Obstruction with Review of Literature*. The Internet Journal of Surgery. 2008 Volume 18 Number 2.

## Abstract

Acquired gastric outlet obstruction (GOO) by a pyloric leiomyoma is a very rare condition. We report an unusual case of a 41-year-old male who presented with epigastric fullness and postprandial upper abdominal distention for three and a half years, and recurrent non-bilious vomiting and progressive weight loss for two months. The case was diagnosed preoperatively by upper GI endoscopy and histopathology. We are reporting this case because of its rarity and excellent outcome if diagnosed and managed properly. Even after extensive search of medical literature, we are able to find only few reports of this lesion causing gastric outlet obstruction.

## CASE REPORT

A 41-year-old male was referred to our tertiary care hospital from a peripheral centre for management of epigastric fullness and postprandial upper abdominal distention for three and a half years, and recurrent non-bilious vomiting and progressive weight loss for two months. His past surgical history consisted in an appendectomy performed seven years back for right iliac fossa pain.

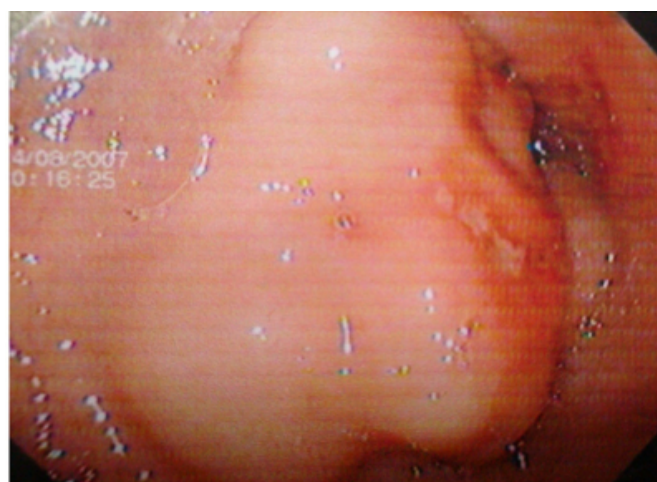
On admission, he was emaciated and weighed 51 kg. He had gross pallor. Abdominal examination revealed epigastric distention and a tympanic mass in the epigastric area was appreciated. Bowel sounds were sluggish and per-rectal examination was normal. His hernia orifices were normal.

His blood investigations were unremarkable except for a total leukocyte count (TLC) of  $17.06 \times 10^6$ . His serum amylase level was normal. Plain X-ray of the abdomen showed features of a distended stomach (a large gastric shadow with an air/fluid level). Ultrasonography (USG) of the abdomen was normal. Upper GI endoscopy revealed a hyperplastic 4.5x3.5cm growth in the distal part of the pylorus (anterior wall) with a small ulcerated area on the surface. The tissue sent for pathologic examination showed the tumor to be a leiomyoma. The patient underwent elective laparotomy and resection of the entire tumor with a rim of normal gastric wall. The patient became symptom-free and was discharged on the sixth postoperative day. At one-year follow-up, he is free of any symptoms and thriving well. The patient has also undergone upper GI endoscopy twice since

then and shows no recurrence until now.

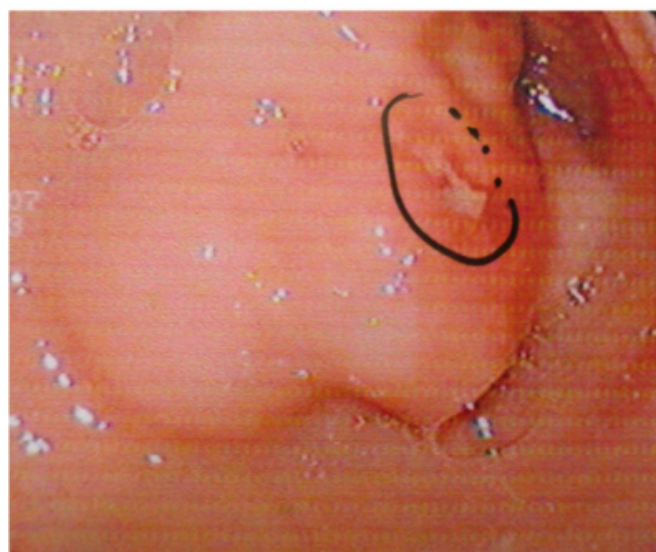
## Figure 1

Figure 1: Large pyloric tumor (leiomyoma) located on the anterior wall



**Figure 2**

Figure 2: Small ulcer on the surface of the pyloric mass. Fig. 3: Large mass occluding the lumen of the pylorus



**DISCUSSION**

Gastric outlet obstruction (GOO) is not considered a single entity; rather it is the clinical consequence of any disease process that produces a blockade to gastric emptying. GOO is categorized into two groups on the basis of its causes: benign and malignant. A study shows that only 37% of patients with GOO have benign disease and the remaining patients have obstruction due to malignancy.<sup>1</sup> The patient we report had a benign leiomyoma. The major benign causes of GOO are peptic ulcer disease (PUD), gastric polyps, ingestion of caustics, congenital duodenal webs, pyloric stenosis, gallstone obstruction (Bouveret syndrome), pancreatic pseudocysts, and bezoars. Leiomyomas, leiomyosarcomas, and leiomyoblastomas account for fewer than 2% to 3% of surgical resections performed for gastric neoplasms.<sup>13,15,16</sup> Gastric leiomyomas smaller than 1cm, however, were found in 46% of stomachs carefully sectioned at autopsy in 50 patients aged 19 to 82 years in one study.<sup>17</sup> Ulcers within the pylorus and first part of duodenum usually are responsible for outlet obstruction. Pancreatic cancer is the most common malignancy causing GOO. Other tumors that may cause gastric outlet obstruction include ampullary cancer, duodenal cancer, gastric cancer and cholangiocarcinomas. Duodenal ulcers give rise to this complication more often than gastric ulcers. Intrinsic or extrinsic obstruction of the pyloric channel or duodenum is the usual pathophysiology of GOO. In the pediatric patients, pyloric stenosis constitutes the most important cause of GOO. Vomiting is the cardinal symptom. Malnutrition is a

late sign. Our patient had vomiting for about two months and he was emaciated. Prolonged vomiting may lead to dehydration and electrolyte abnormalities. Patients may develop significant and progressive gastric dilatation if obstruction persists. Vomiting usually is non-bilious. Weight loss is frequent. Epigastric fullness and early satiety are common. Physical examination reveals the presence of chronic dehydration and malnutrition. A dilated stomach may be appreciated as a tympanitic mass in the epigastric area. Prolonged vomiting results in hypokalemic hypochloremic metabolic alkalosis due to loss of hydrochloric (HCl) acid. Laboratory findings may show anemia, and an X-ray typically shows a large gastric shadow with an air/fluid level (as in our patient). Barium upper GI studies are very helpful because they can delineate the gastric silhouette and demonstrate the site of obstruction. A rounded mass with smooth edges and reasonably normal overlying mucosa is the characteristic appearance of a leiomyoma on a barium study. Endoscopic biopsy findings may be deceptive unless ulceration is complete and the neoplasm is exposed.<sup>13</sup> Also, histologic differentiation between a benign or malignant gastric stromal tumor based on the endoscopic biopsy results may not be possible. On an abdominal computed tomographic scan, larger size (>5cm), lobulated contour, heterogeneous enhancement, ulceration, and exophytic growth pattern are all statistically significant predictors of a malignant gastrointestinal stromal tumor. UGI endoscopy can help visualize the gastric outlet and may provide a tissue diagnosis when the obstruction is intraluminal. A diagnosis of GOO is made if more than 400 cc remain in the stomach after 30 minutes. Initial management of GOO should be the same regardless of the primary cause: admission of patients for hydration and correction of electrolyte abnormalities. Sodium chloride solution is the initial intravenous fluid of choice. The potassium deficit is corrected after repletion of the volume status and after replacement of chloride. A nasogastric tube is placed to decompress the stomach. When PUD has been identified as a primary cause of GOO, treatment is focused on the reduction of acid production. H. pylori infection is treated, when identified. Scarring and fibrosis may worsen over time, although most patients improve temporarily with treatment. Surgical intervention is needed in more than 75% of patients presenting with GOO.<sup>2</sup> The most common surgical procedures performed for GOO related to PUD are vagotomy and antrectomy, vagotomy and pyloroplasty, truncal vagotomy and gastrojejunostomy, pyloroplasty, and laparoscopic variants of the mentioned procedures. Of these,

vagotomy and antrectomy with Billroth II reconstruction (gastrojejunostomy) seem to offer the best results. The role of the laparoscopic approach in the treatment of GOO is under evaluation. One group in China performed laparoscopic truncal vagotomy and gastrojejunostomy for GOO related to PUD with nearly complete resolution of symptoms. They reported no conversions to open procedure and no mortalities. Twenty-seven percent of patients did experience transiently delayed gastric emptying, which resolved with conservative measures.<sup>3</sup> Pneumatic balloon dilatation of a chronic benign stricture can be performed via endoscopy. A lubricated balloon is passed through the endoscope and is inflated with water or air. A series using this technique reports success rates over 76% after multiple dilatations.<sup>4</sup> Those treated with balloon dilatation, without treatment of *H. pylori* infection, have a higher rate of failure and recurrent obstruction.<sup>5</sup> Patients who are negative for *H. pylori* do not respond favorably to balloon dilatation and should be considered for surgical treatment early in the process.<sup>6</sup> The management of GOO secondary to malignancy is controversial. Of patients with periampullary cancer, 30-50% present with nausea and vomiting at the time of diagnosis.<sup>78</sup> The majority of these tumors are unresectable (40% of gastric cancers and 80-90% of periampullary cancers).<sup>910</sup> Gastrojejunostomy remains the surgical treatment of choice for GOO secondary to malignancy. Although surgeons traditionally have preferred an antecolic anastomosis to prevent further obstruction by advancing tumor growth, a publication evaluating the retrocolic anastomosis in this setting challenges conventional wisdom.<sup>11</sup> Recently, self-expandable metallic stents have been used for the treatment of GOO in a malignant setting.

Reviews of gastric stromal tumors have credited Giovanni Battista Morgagni with the first description of a gastric leiomyoma in 1762.<sup>121314</sup> The onset of symptoms in most patients occurs in the fifth or sixth decade of life, although children are also affected.<sup>1316</sup> Gastric leiomyomas cause epigastric pain and/or upper gastrointestinal hemorrhage. When a leiomyoma or other stromal tumor in the gastric wall grows to a size of 3 to 4 cm, ulceration of the overlying mucosa occurs, as in our patient. Chronic blood loss is a more common presentation, although hematemesis has been reported. With leiomyosarcomas or leiomyoblastomas, hemorrhage has been reported to occur in many patients. Asymptomatic gastric stromal tumors may be discovered on radiographs, during endoscopic evaluations of the stomach, or at an exploratory laparotomy for another disease

process.<sup>15</sup>

There have been continuing difficulties in differentiating benign from low-grade malignant gastric stromal neoplasms for many years. For benign lesions, enucleation at operation is contraindicated. Resection of the gastric wall with a 2- to 3-cm cuff of normal tissue is appropriate. A larger exophytic lesion may require a gastrectomy with similar margins and resection of adherent omentum, lymph nodes, or adjacent organs. In recent years, acronyms such as GIST (gastrointestinal stromal tumor) and STUMP (smooth muscle tumor of uncertain malignant potential) have been used by pathologists when describing tumors formerly known as leiomyomas, leiomyosarcomas, and leiomyoblastomas. Benign leiomyomas are cured by resection of the entire tumor with a rim of normal gastric wall as was done in our patient.

## References

1. Andersson A, Bergdahl L. Carcinoid tumors of the appendix in children. A report of 25 cases. *Acta Chir Scand*. 1977;143(3):173-5.
2. Doberneck RC, Berndt GA. Delayed gastric emptying after palliative gastrojejunostomy for carcinoma of the pancreas. *Arch Surg*. 1987;122(7):827-9.
3. Siu WT, Tang CN, Law BK, Chau CH, Yau KK, Yang GP, et al. Vagotomy and gastrojejunostomy for benign gastric outlet obstruction. *J Laparoendosc Adv Surg Tech A*. 2004;14:266-9.
4. Lam YH, Lau JY, Fung TM, et al. Endoscopic balloon dilation for benign gastric outlet obstruction with or without *Helicobacter pylori* infection. *Gastrointest Endosc*. 2004;60:229-33.
5. Taskin V, Gurer I, Ozyilkan E, Sare M, Hilmioglu F. Effect of *Helicobacter pylori* eradication on peptic ulcer disease complicated with outlet obstruction. *Helicobacter*. 2000;5:38-40.
6. Gouma DJ, van Geenen R, van Gulik T, de Wit LT, Obertop H. Surgical palliative treatment in bilio-pancreatic malignancy. *Ann Oncol*. 1999;10 Suppl 4:269-72.
7. Jaffin BW, Kaye MD. The prognosis of gastric outlet obstruction. *Ann Surg*. 1985;201(2):176-9.
8. Khullar SK, DiSario JA. Gastric outlet obstruction. *Gastrointest Endosc Clin N Am*. 1996;6:585-603.
9. Kurtz RC, Sherlock P. Carcinoma of the stomach. In: *Bockus Gastroenterology*. 4th ed. Philadelphia, PA: W. B. Saunders Co.; 1985.
10. Lillemoe KD, Sauter PK, Pitt HA, Yeo CJ, Cameron JL. Current status of surgical palliation of periampullary carcinoma. *Surg Gynecol Obstet*. 1993;176(1):1-10.
11. Lillemoe KD, Cameron JL, Hardacre JM, Sohn TA, Sauter PK, Coleman J, et al. Is prophylactic gastrojejunostomy indicated for unresectable periampullary cancer? A prospective randomized trial. *Ann Surg*. 1999;230:322-8.
12. Giberson RG, Dockerty MB, Gray HK. Leiomyosarcoma of the stomach: clinicopathologic study of 40 cases. *Surg Gynecol Obstet*. 1954;98:186-196.
13. Basson MD, Modlin IM, Flynn SD. Current clinical and pathologic perspectives on gastric stromal tumors. *Surg*

Gynecol Obstet. 1992;175:477-489.

14. Virchow R. Die krankhaften Geschwuelste. Vol 3. Berlin, Germany: A Hirschwald; 1867:128. Cited by: Giberson RG, Dockerty MB, Gray HK. Leiomyosarcoma of the stomach: clinicopathologic study of 40 cases. Surg Gynecol Obstet. 1954;98:186-196.

15. Sebastian MW. Benign tumors of the stomach. In: Sabiston DC Jr, ed. Textbook of Surgery: The Biological

Basis of Modern Surgical Practice. Philadelphia, PA: W. B. Saunders Co.; 1997:868-875.

16. Schorlemmer GR, Benson M, Grimes M, et al. Neoplasms of gastric smooth muscle. Contemp Surg. 1983;22:89-100.

17. Meissner WA. Leiomyoma of the stomach. Arch Pathol. 1944;38:207-209.

**Author Information**

**Nadeem-ul-Nazeer**

Postgraduate, Department of General Surgery, Sher-i-Kashmir Institute of Medical Sciences (SKIMS), University of SKIMS

**Athar Bashir**

Senior Registrar, Department of Surgical Gastroenterology, Sher-i-Kashmir-Institute-of-Medical-Sciences (SKIMS),  
University of SKIMS