

# Treatment Of Congenital Ichthyosis With Acitretin

A Cakmak, F Baba, S Cakmak, K Shermatov, H Karazeybek

## Citation

A Cakmak, F Baba, S Cakmak, K Shermatov, H Karazeybek. *Treatment Of Congenital Ichthyosis With Acitretin*. The Internet Journal of Pediatrics and Neonatology. 2007 Volume 8 Number 1.

## Abstract

We assessed the clinical efficacy, tolerability and safety of acitretin in a patient with ichthyosis. A newborn infant with ichthyosis who presented at birth with collodion baby appearance, was treated with acitretin. A moderate response to acitretin therapy (1 mg/kg/day) administered for 6 months was observed, with improvement in cutaneous lesions. Clinical improvement was achieved shortly after treatment. The treatment resulted in a satisfactory improvement in the skin condition of the case. The tolerance to the drug was good. Side effects were not observed. The oral acitretin treatment is efficient in severe congenital ichthyosis.

## INTRODUCTION

Ichthyosis belongs to the group of genodermatoses, characterized by hyperkeratosis and desquamation of the epidermis. Clinical manifestation is heterogeneous and depends on the type of the disease (1). Congenital ichthyoses which affect the entire body in the perinatal period include several major subtypes; harlequin ichthyosis, lamellar ichthyosis (LI), and congenital ichthyosiform erythroderma (2,3,4,5). Severe congenital ichthyosis which shows intense hyperkeratosis on whole body of the neonate include several distinct types of ichthyosis with different pathogenesis (2,3,4). At the terminal differentiation of keratinocytes, a variety of proteins specific for keratinization are expressed and unique subcellular structures are formed. Some of these structures and proteins are thought to be closely associated with the pathogenesis of severe congenital ichthyosis.

Topical treatment of ichthyosis classically includes generous and frequent applications of emollients and keratolytic agents such as retinoic acid (0.1% cream) lactic acid, urea, a mixture of lactic acid and propylene glycol, and calcipotriol (6,7,8,9,10). Unpredictable transcutaneous absorption of topically administered drugs and potential teratogenicity and toxicity of systemic drugs therefore make it mandatory to innovate more efficacious and less toxic drugs for the treatment of ichthyosis. We assessed the clinical efficacy of acitretin treatment of congenital ichthyosis, and hereby report the successful treatment of this disease without any side effects in a newborn.

## CASE REPORT

A 2850 g male infant was born to a 24-year-old woman after a pregnancy of 40 weeks gestation. The baby was the first child of the family and parents were first degree relatives. There was no family history of congenital abnormalities.

The mother had neither regular obstetric follow-ups nor any ultrasound examinations during pregnancy because of financial problems. She had a normal spontaneous vaginal delivery at home with help of a midwife. Postpartum APGAR scores were not determined.

At delivery, the infant was noted to have a thick keratin-coated yellow skin, split by deep and extensive fissures into polygonal plates. He had severe bilateral ectropion, eclabium, underdeveloped nasal bridge, rudimentary ears and sparse scalp hair. He also had flexure contractures with hypoplasia of the fingers and toes (Figure 1). The baby was referred to our hospital's neonatal intensive care unit. The baby's routine laboratory tests and abdominal ultrasoundographic evaluations were within normal limits. The baby was kept in the incubator and fed with nasogastric tube and intravenous fluids. Ophthalmic and dermatologic treatments, vaporisation of incubator, and wide-spectrum antibiotic treatments were started.

Phototherapy was applied because of hyperbilirubinemia. Acitretin (1mg/kg/day) treatment was started. Pretreatment skin punch biopsy revealed a moderate degree of hyperkeratosis with complete absence of granular cell layer in the epidermis. Hyperkeratosis extended into the hair

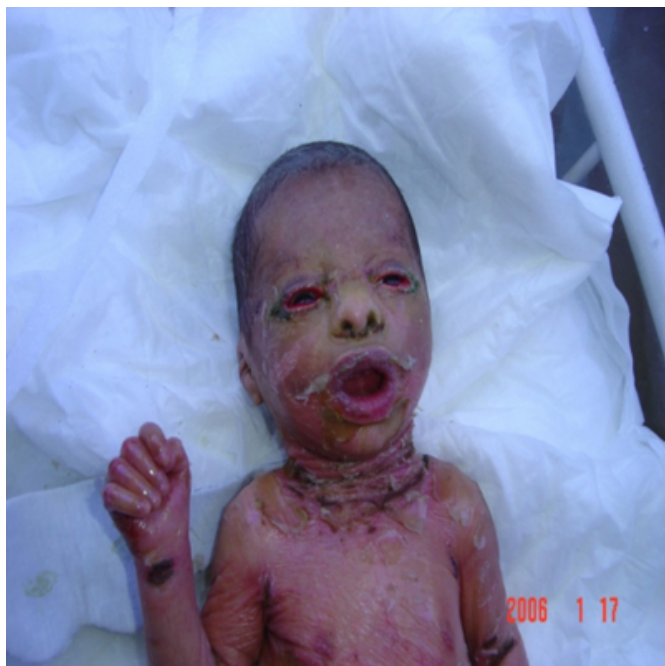follicles forming keratotic follicular plugs. (Figure 2 : 200X,HE)

The patient was clinically followed up regularly for six months. A post-treatment rebiopsy was performed and it revealed significant improvement of epidermal changes as continuous granular cell layer (Figure3: 200 X, HE).

In accordance with histologic improvements, the patient's clinical appearance improved significantly as well (Figure 4).

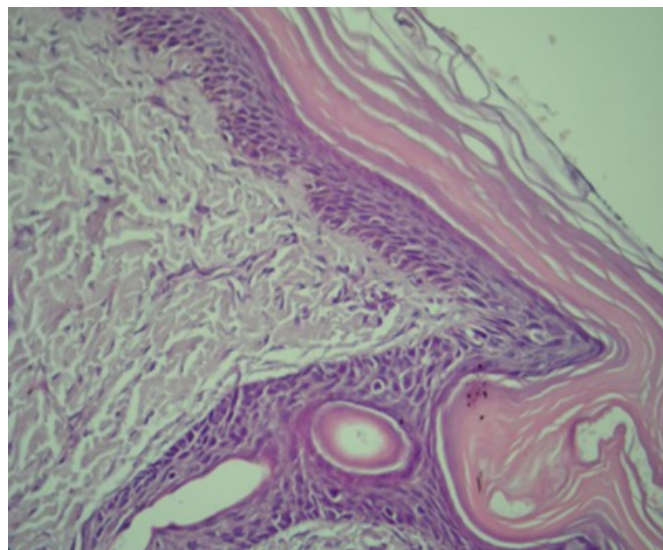
**Figure 1**

Figure 1: Pretreatment appearance of the patient.



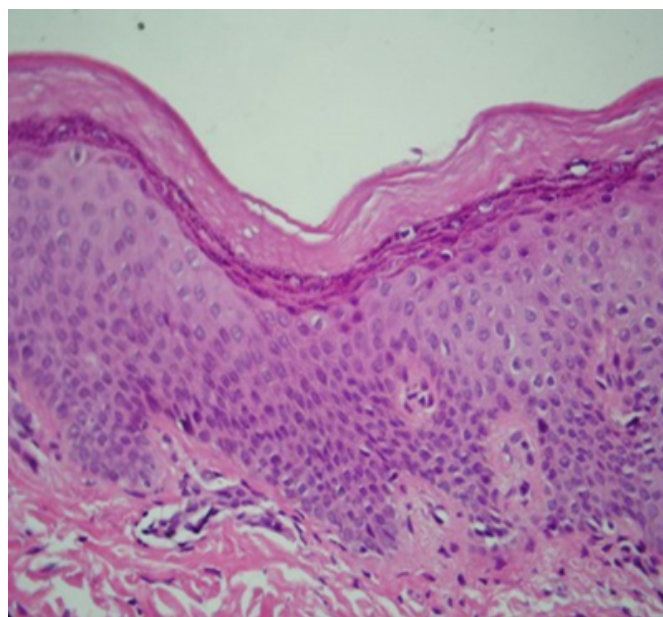
**Figure 2**

Figure 2: Pretreatment punch biopsy material showing moderate degree of hyperkeratosis with complete absence of granular cell layer. Hyperkeratosis extends into the hair follicle forming keratotic follicular plug. (200X, HE)



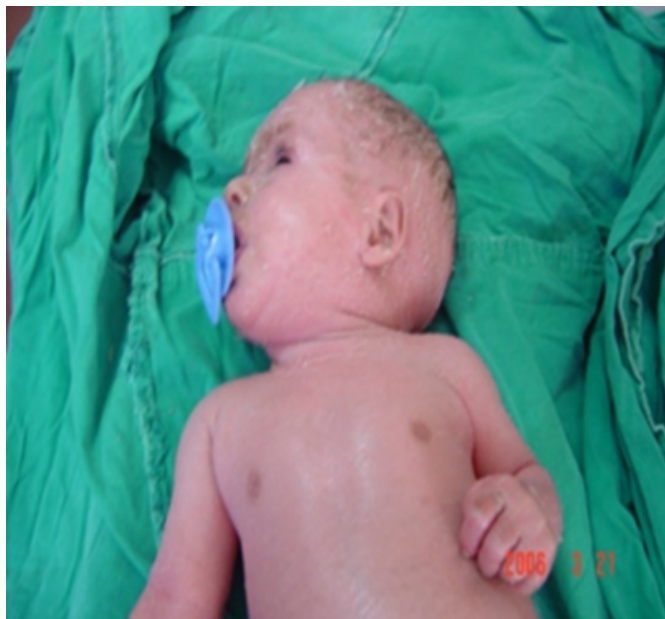**Figure 3**

Figure 3: Posttreatment punch biopsy showing continuous granular cell layer. (200 X, HE)



**Figure 4**

Figure 4: Post-treatment appearance of the patient.



### DISCUSSION

Many surviving congenital ichthyosis patients have been treated with retinoids and survival is often attributed to early therapeutic intervention. However, the role of retinoids in improved survival still remains to be determined (11,12,13,14,15,16). Many perinatal congenital ichthyosis deaths are caused by interference of severe infections causing loss of vital functions and the late onset of retinoid action; therefore, other factors such as improved intensive care of severely compromised neonates, are likely to be important in survival of the patient. (16).

The clinical features of infants with congenital ichthyosis are generally similar to our case, which is typical. No visceral malformation is reported, the disorder consisting exclusively of an error of epidermal keratinization. Respiratory movements are restricted; secondary infection and septicemia are frequent complications. Death usually occurs in the first few weeks of life.

Prenatal diagnosis is now possible, using sonography, which shows ectropion, eclabium, nasal or aural abnormalities, and hypoplasia of the extremities. However, a precise diagnosis needs fetal skin biopsy made between 20 and 22 weeks of gestation (17). If the number and size of the biopsy specimens are small, it may be possible to misdiagnose an affected fetus as normal (17). Prenatal diagnosis is vital in genetically inherited lethal diseases. According to the prenatal diagnosis, the patients should thoroughly be evaluated and

the families be informed about the disease (18).

At light microscopic examination, a thick compact stratum corneum with parakeratosis, hypogranulosis and hyperkeratosis of the hair canals is seen (19). On ultrastructural examination, the granular layer keratinocytes present abnormalities of lamellar granules. Between the cornified cell and the granular cell layers, extracellular lamellar structures are lacking (17). In our case histopathologic evaluation revealed moderate degree of hyperkeratosis and complete absence of granular cell layer in the epidermis with keratotic follicular plugs.

Control biopsy performed after a acitretin (1 mg/kg/day/ 6 month) therapy showed that the prior findings had completely ceased.

Some rare long-term survivals of congenital ichthyosis are reported. This survival is often attributed to early treatment with retinoids. The clinical presentation then evolves with age into a viable form of generalized ichthyosis (20). However, the persisting dermatosis remains severe and the quality of life of affected children is poor.

El-Ramly et al (21). presented eight cases of ichthyosis treated with retinoids. They reported that aromatic retinoid treatment resulted in a satisfactory improvement of skin condition. Tamayo et al (22). also recommended oral retinoid treatment after their experience in eight children with lamellar ichthyosis.

Gicquel et al (23) reported bilateral ectropion treatment in an infant with severe lamellar ichthyosis by N-acetylcysteine applied directly to the skin with association of oral acitretin. Topical N-acetylcysteine has been proved to have an antiproliferative effect on keratinocytes in vitro and in vivo. It may be useful in the treatment of major forms of ectropion in children with lamellar ichthyosis. Its association with conventional acitretin treatment may prevent unnecessary surgery. In accordance with the prior studies in literature, our patient showed dramatic improvement in skin lesions and ectropion with oral acitretin treatment.

Verfaille et al. (24) investigated the efficacy, tolerability and safety of oral liarozole, a retinoic acid metabolism blocking agent, with acitretin in patients with ichthyosis. Between-group comparisons for efficacy and tolerability revealed no statistically significant differences except for scaling on the trunk at baseline which was significantly worse in the liarozole group and showed a more pronounced

improvement in this group than in the acitretin-treated patients. The expected retinoic acid-related adverse events were mostly mild to moderate and tended to occur less frequently in the liarozole group. The results of this trial warrant further clinical trials to confirm efficacy and safety of liarozole as an orphan drug in ichthyosis. Saracoglu et al. (25) treated two newborn infants with ichthyosis with acitretin (1 mg/kg/day). Clinical improvement was achieved shortly after treatment. They concluded that early management of severe ichthyosis cases could prevent life-threatening events.

Furthermore, long-term retinoid therapy is responsible for toxicity. Long-term therapy with oral retinoids provokes anxiety and shows adverse effects on bone mineralization. The most commonly reported effect is the production of osteophytes and calcification of ligaments (25). Paige et al (26) observed no evidence of skeletal toxicity in 42 children treated over an 11-year period. No complication due to oral acitretin treatment was observed in our patient.

In conclusion, early management of severe ichthyosis cases can prevent life-threatening events. In severe congenital ichthyosis cases, mortality due to the complications, is high in the neonatal period. Therefore, acitretin treatment seems to be the most efficient treatment in severe congenital ichthyosis with no major side effects and easy oral application.

### CORRESPONDENCE TO

Alpay Cakmak, MD Harran University School of Medicine  
Department of Pediatrics TR-63100, Sanliurfa, TURKEY.  
Tel: +90 414 3141170 Mobile Phone : +90 5326235956 e-mail: alpaycakmak@gmail.com Fax: +90 414 3151181

### References

1. Zapalowicz K, Wygledowska G, Roszkowski T, et al. Harlequin ichthyosis--difficulties in prenatal diagnosis. *J Appl Genet.* 2006;47:195-197.
2. Williams MLK, Lynch PJ. Generalized disorders of cornification: The ichthyoses. In: W.M. Jr Sams and P.J. Lynch Editors, *Principles and Practice of Dermatology*, 2nd ed Churchill Livingstone, New York, NY 1996; 379-396.
3. Judge MR, Harper JI. The ichthyoses. In: J. Harper Editor, *Inherited Skin Disorders, the Genodermatoses* Butterworth-Heinemann, Oxford. 1996; 69-96.
4. Akiyama M. Severe congenital ichthyosis of the neonate. *Int. J. Dermatol.* 1998; 37 : 722-728.
5. Akiyama M. The pathogenesis of severe congenital ichthyosis of the neonate. 1999;21:96-104.
6. Erdem G. Treatment of collodion babies with a topical preparation containing lactic acid. *Turk J Pediatr* 1982;24:97-101
7. Küster W, Bohnsack K, Rippke E Upmeyer HJ, Groll S, Traupe H. Efficacy of urea therapy in children with ichthyosis. A multicenter randomized, placebo-controlled, double-blind, semilateral study. *Dermatology* 1998;196:217-222
8. Ganemo A, Virtanen M, Vahlquist A. Improved topical treatment of lamellar ichthyosis: a double-blind study of four different cream formulations. *Br J Dermatol* 1999;141:1027-1032
9. Delfino M, Fabbrocini G, Sammarco EM, et al. Efficacy of calcipotriol versus lactic acid cream in the treatment of lamellar and x-linked ichthyoses. *J Dermatol Treat* 1994;5:151-152
10. Sarici U, Iahin M, Yurdakok M. Topical N-acetylcysteine treatment in neonatal ichthyosis The Turkish Journal of Pediatrics 2003; 45: 245-247.
11. Lawlor F, Peiris S. Harlequin fetus successfully treated with etretinate, *Br J Dermatol* 1985; 112:585-590.
12. Rogers M, Scarf C. Harlequin baby treated with etretinate. *Ped Dermatol* 1989;6: 216-221.
13. Ward PS, Jones RD. Successful treatment of Harlequin fetus, *Arch Dis Child* 1989; 64: 1309-1311.
14. Roberts LJ. Long-term survival of a harlequin fetus, *J Am Acad Dermatol* 1989; 21:335-339.
15. Williams ML, Elias PM. Genetically transmitted, generalized disorders of cornification: the ichthyoses, *Derm Clin* 1987; 5: 155-178.
16. Choate KA, Williams ML, Elias PM, Khavari PA. Transglutaminase 1 expression in a patient with features of harlequin ichthyosis: case report. *J Am Acad Dermatol.* 1998;38:325 - 9.
17. Akiyama M, Dale BA, Smith LT, et al. Regional difference in expression of characteristic abnormality of harlequin ichthyosis in affected fetuses. *Prenat Diagn* 1998; 18: 425-436.
18. Tarim E, Bagii T, Bulgan E, et al. Harlequin Fetus. *J of Perinatology* 2002;10: 38-39.
19. Dale BA, Holbrook KA, Fleckman P, et al. Heterogeneity in harlequin ichthyosis, an inborn error of epidermal keratinization: variable morphology and structural protein expression and a defect in lamellar granules. *J Invest Dermatol* 1990; 94: 6-18.
20. Moreau S, Salame E, Goullet de Rugy M, et al. Harlequin fetus: a case report. *Surg Radiol Anat.* 1999;21: 215 - 6.
21. El-Ramly M, Zachariae H. Long-term oral treatment of two pronounced ichthyotic conditions: lamellar ichthyosis and epidermolytic hyperkeratosis with the aromatic retinoid, Tigason (RO 10-9359). *Acta Derm Venereol.* 1983; 5: 452-6
22. Tamayo L, Ruiz-Maldonado R. Oral retinoid (Ro 10-9359) in children with lamellar ichthyosis, epidermolytic hyperkeratosis and symmetrical progressive erythrokeratoderma. *Dermatologica.* 1980; 5 :305-14.
23. Gicquel JJ, Vabres P, Dighiero P. Use of topical cutaneous N-acetylcysteine in the treatment of major bilateral ectropion in an infant with lamellar ichthyosis. *J Fr Ophtalmol.* 2005;28:412-5.
24. Verfaillie CJ, Vanhoutte FP, Blanchet-Bardon C, van Steensel MA, Steijlen PM. Oral liarozole vs. acitretin in the treatment of ichthyosis: a phase II/III multicentre, double-blind, randomized, active-controlled study. *Br J Dermatol.* 2007 ; 29: [Epub ahead of print]
25. Saracoglu ZN, Tekin N, Urer SM, Sabuncu I, Aksit A. Oral acitretin treatment in severe congenital ichthyosis of the neonate. *Turk J Pediatr.* 2002;44:61-64.
26. Paige DG, Judge MR, Shaw DG, et al. Bone changes and their significance in children with ichthyosis on long-term etretinate therapy. *Br J Dermatol.* 1992 ; 4 : 387-91.

**Author Information**

**Alpay Cakmak**

Assistant Professor, Department of Pediatrics, Harran University School of Medicine

**Fusun Baba**

Assistant Professor, Department of Pathology, Harran University School of Medicine

**Sevin Cakmak**

Associate Professor , School of Medicine, Dicle Universty Department of Ophthalmology

**Kabil Shermatov**

Associate Professor, Department of Pediatrics, Harran University School of Medicine

**Himmet Karazeybek**

Professor, Department of Pediatrics, Harran University School of Medicine