

# The Effect Of Low-Dosed Unfractionated And Low-Molecular-Weight Heparins On Bone Healing In Vivo

H Erli, M Melchert, M Rüger

## Citation

H Erli, M Melchert, M Rüger. *The Effect Of Low-Dosed Unfractionated And Low-Molecular-Weight Heparins On Bone Healing In Vivo*. The Internet Journal of Orthopedic Surgery. 2005 Volume 3 Number 2.

## Abstract

**Aim:** To elucidate if low-dosed heparins (both unfractionated and low-molecular-weight) have a significantly negative effect on bone healing in vivo, as reported previously. While other studies applied higher doses, we used doses comparable to clinical application.

**Methods:** Female rabbits received defined metaphyseal defects to their femora and were then subjected to daily injections of either saline solution, unfractionated low-dose heparin (UFH) or one of two different low-molecular-weight heparins for a period of 6 weeks. After scarification, the remaining osseous defects were histomorphometrically examined.

**Results:** We found some indication, but no statistical evidence, that both UFH and two different LMWH appear to reduce bone healing compared to placebo after 6 weeks. In the placebo group, an average defect reduction of 50.7 % was observed. In the UFH group, the defects had reduced by 42,7 % on average, in the certoparine group by 42,7 % and in the dalteparin group by 47,9 %.

**Conclusion:** As our results do not prove a significant reduction of bone healing in vivo at clinically relevant doses, we recommend to continue using a combined approach for clinical DVT prophylaxis, including daily s.c heparin administration, until full mobilization.

## LIST OF ABBREVIATIONS

DVT - Deep vein thrombosis

LMWH - Low molecular weight heparin

UFH - Unfractionated heparin

IU - International Unit, used to measure the anticoagulatory effect of a given heparin. Based on a WHO reference heparin derived from porcine intestinal mucosa. 1 mg of standard heparin contains ca. 170 IU (156).

## INTRODUCTION

For more than 30 years, subcutaneous administration of heparin has been the gold standard for the prophylaxis of venous thrombembolisms (33). In orthopaedic surgery, injuries to the lower extremity, vertebral column or pelvis, are associated with an very high risk of thromboembolic incidents, such as deep vein thrombosis and pulmonary embolisms. Pulmonary embolism have been found in 2-22% of trauma patients. In the U.S., an estimated 100,000 patients die from pulmonary embolisms each year (34). Prophylaxis

includes daily subcutaneous heparin administration as well as mechanical compression of the lower extremities, either by stockings or pneumatic compression devices. In our clinic, we use daily s.c. shots of enoxaprin (Clexane/Lovenox™) combined with compression stockings until patients are fully mobilized and are allowed to sustain their full body weight.

In a recent comprehensive review by Agudelo et al., the patho-physiological prerequisites for venous thrombembolism are discussed at length (37). Virchow's triad, published in 1856, established intimal venous injury, hemostasis and hypercoagulability as the 3 major factors for the development of venous thrombembolisms (35). More recently studies by Meissner et al. find hypercoagulability in up to 80% of trauma patients, persisting for at least one month after injury (36). As Agudelo and Morgan report, most thrombi in high-risk patients originate in the deep veins of the calf. Of these, about 10-20% eventually extend into more proximal veins, of which about half eventually lead to pulmonary embolisms.

Commercial medical-grade heparins are derived mainly from porcine intestine or bovine lung tissue. Heparins are mucopolysaccharides with molecular masses of 6-30 kDa (unfractionated heparin) and 1-10 kDa (low molecular weight heparins), respectively (<sub>14,15</sub>). Heparins as pentasaccharides bind to antithrombin III (<sub>18</sub>), amplifying its efficacy 1000-fold. The anticoagulatory effect is achieved at serum concentration of 0,1 to 1 International Unit (I.U.) heparin/mL blood. Side effects include haemorrhages in the skin, mucous tissue, and wounds, as well as in the gastrointestinal and urinary tracts. (<sub>30,34</sub>). Another, not uncommon side effect is heparin-induced thrombocytopenia Type II (HIT II), an antibody/antigene reaction leading to a fast decline of platelet counts below 100k /  $\mu$ L or below 50% of an individual's normal platelet level. UFH are typically used for the treatment of acute deep vein thrombosis and arterial embolism, as well as acute myocardial infarction.

Low molecular weight heparins (LMWH) are derived from standard heparin by chemical processes called fractioning or fragmentation. Due to these different production processes, LMWH are a heterogeneous group of substances with varying pharmacokinetic and pharmacodynamic properties and can not be readily substituted for one another (<sub>4</sub>). The average molecular mass of LMWH varies between 3.900 and 6.000 Da (<sub>13,14</sub>). Generally, LMWH provide their antithrombotic effect by binding to AT III and deactivating thrombin (Factor IIa). While UFH binds to AT III and deactivates Factor IIa equally, LMWH have less affinity to Factor IIa, most likely due to their shorter polysaccharide chains. While UFH binds to AT III and Factor IIa 1:1, LMWH bind to AT III 2 to 4 times more likely than to Factor IIa (<sub>5</sub>). For this reason LMWH do not effect tests such as aPTT as UFH and can not be monitored in terms of clinical effect, but only in terms of serum concentration of anti-Xa units. LMWH are used primarily for the prophylaxis of venous thromboembolic disorders, venous thromboses, pulmonary embolisms, during extracorporeal circulation and hemodialysis (<sub>6,28</sub>).

In 1948, Lenggenghagen discovered that even minute concentrations of heparin can be an effective anticoagulant by blocking Factor Xa and thus preventing the formation of fibrin clots (<sub>11,52,53</sub>). Large studies in the 1970s by Kakkar and Gallus corroborated these results (<sub>16,22,23,24,25,26,47</sub>). Schöndorf et al. reported a reduction of thromboembolic incidents in orthopaedic patients receiving low-dose heparin from 60% to 18%. Instead of traditional continuous i.v. infusion of 18 I.U. heparin/ kg body weight/ hour or

subcutaneous injections of 3 x 12.500 or 2 x 25.000 I.U./day, low-dose anticoagulation reduced these amounts to 3 x 5.000-7.500 I.U./day with equal efficacy. For more than 30 years, low-dosed heparins represent the gold standard for the prophylaxis of venous thromboses and associated complications in clinical medicine. Prophylaxis of arterial thrombosis (such as in myocardial infarction) and therapy of manifest deep vein thromboses as well as embolic incidents are treated with traditional i.v. heparin or weight-adjusted LMWH.

Both UFH and LMWH have been reported to interfere with bone physiology. Many cases of heparin-induced osteoporosis have been reported, leading to fractures of vertebral bodies or femoral neck, amongst others (<sub>2,41,46,51</sub>). The interactive pathways between heparins and bone cells have remained largely elusive. Both direct influences on osteoblasts and osteoclasts, as well as indirect influences such as interference with intercellular signalling, hormone feedback loops and mineral metabolism are being discussed. Monreal et al. suggested an inhibitory effect on osteoblasts with data derived from a rat model (<sub>40</sub>), while Fuller et al. consider an amplification of osteoclast activity the more likely reason (<sub>15</sub>). Asher et al. postulate that heparins actually interfere with collagen synthesis, resulting in less extracellular matrix and osteoid being produced and thus an overall reduced bone density (<sub>3</sub>). Mutoh et al. found a negative correlation between heparin and serum levels of vitamin-d3 (<sub>43</sub>). Crisp et al. postulate an increased activity of PTH under heparin (<sub>9</sub>), while Dahlmann et al. consider an attenuation of calcitonin activity to be the more likely cause for the formation of osteoporotic bone (<sub>10</sub>). Mätzsch et al. discuss a correlation between zinc-mediated binding to sulfonic acid groups and the adverse effects on bone formation (<sub>37</sub>).

Street et al. investigated the effect of prophylactic administration of the LMWH enoxaparin on the healing of a closed rib fracture in a rabbit model. Fracture healing was significantly attenuated at all times in animals receiving subcutaneous enoxaparin compared with that of the control animals. Fracture healing was assessed using histomorphometric, histologic and immunohistochemical methods (<sub>50</sub>). In accordance with this result Osip(<sub>43</sub>) and Kock (<sub>27</sub>) reported an significant inhibition of osteoblast growth by application of LMWH in a standardized in vitro model. Handschin described a significant, dose dependent inhibition of osteoblast proliferation, inhibition of protein synthesis and inhibited expression of phenotype markers

(osteocalcin and alkaline phosphatase genes) in primary human osteoblast cell culture incubated with dalteparin (<sub>18</sub>).

In contrast to these results Matziolis et al (<sub>35</sub>) described an increased osteoblast-proliferation rate by exposing human osteoblasts in vitro to heparin concentration used therapeutically in humans. They showed also a synergism between heparin and the used fetal calf serum (FCS) which was able to amplify the positive effect of heparin. Hausser found similar results in an in vitro model using osteoblast-like Saos-2 cells. He reported that low concentrations of heparin (5 -500 ng/ml) promoted matrix deposition and subsequent mineralization (<sub>19</sub>).

This study was designed to elucidate if there are significant differences between two common low molecular weight heparins (LMWH) and unfractionated heparin (UFH) on bone healing and possibly derive a clinical guideline for the use and dosage of heparins for orthopaedic and traumatologic patients.

## **MATERIALS AND METHODS**

### **ANIMAL MODEL**

This in vivo study was approved by the local and state animal protection boards according to German Animal Protection Law.

26 female New Zealand White rabbits with an average weight of 3 kg were used for this experiment. 13 of them were kept in 2 kennels of 20 m<sup>2</sup> each, able to move about freely on mulched hay litter. Water and food was made available around the clock, ambient temperature cycled around 21° Celsius with a 12h day/night rhythm.

The animals were arranged into 4 groups of 6 animals each, group 1 receiving daily s.c. injections of saline solution for 6 weeks following operation, group 2 receiving daily s.c. injections of UFH, group 3 receiving daily s.c. injections of dalteparin-sodium (Fragmin), group 4 receiving daily s.c. injections of certoparin-sodium (Mono-Embolex).

### **SURGICAL PROCEDURE**


Initially, the animals received a solution of Ketamin (ketaminhydrochloride) and Rompun 2% (xylazinehydrochloride) i.m. and were then placed into single cages. After anaesthesia taking effect, the animals received an i.v. (Abbocath 22G) into an ear vein to maintain anaesthesia intraoperatively (Ketamin/Rompun and L-Polamivet). The animals were also intubated to prepare for assisted respiration in case of pulmonary depression. For

protection of their conjunctiva, the animals were treated with panthenole ointment.

After shaving, washing and disinfecting the surgical field, sterile drapes were put in place. The incision was made laterally. The fascia lata was split and the lateral quadriceps was removed from its insertion and moved ventromedially to open a window in the soft tissues and prepare the lateral femur condyla for trepanation. Cylindrical bone defects were mill cut into the femoral condylae of the rabbits strictly perpendicular to the long axis of the femur using a water-cooled precision diamond mill cutting system (Diamond Bone Cutting System DBCS, Merck, Darmstadt, Germany; Fig. 1). The instrument used for this experiment was originally developed for the atraumatic trepanation of implant beds and extraction of bone cylinders with an outside diameter of 3,6 mm. After placement of the defect, it was thoroughly rinsed with saline solution, haemostasis was obtained and each layer of tissue subsequently sutured. Finally a spray-on dressing was applied. Likewise, an identical defect was placed into the opposite leg of each animal.

### Figure 1

Figure 1: The watercooled precision diamond millcutting system &#40Diamond Bone Cutting System , Merck, Darmstadt, Germany&#41; used in this study for the trepanation of the bone defects.



After the operation, the animals were individually housed for 14 days to limit excessive movement and to control wound healing. The animals received i.m. shots of Suovipen (an aqueous Penicillin/Streptomycin-solution) on post-op day 2 and 4 to contain possible infections. The animals received i.m. injections of Temgesic (buprenorphine) for analgesia.

### INTERIM CARE

During the 6 week study interval, the animals received daily drug administration and wound inspection. Wound dehiscences, when detected, were surgically revised under sterile conditions as outlined above. Single, noticeably less mobile animals were x-rayed to rule out possible fractures to the trepanized bone. None of the animals were found to have fractures, and in all but one case, returned to normal behavior and mobility within days.

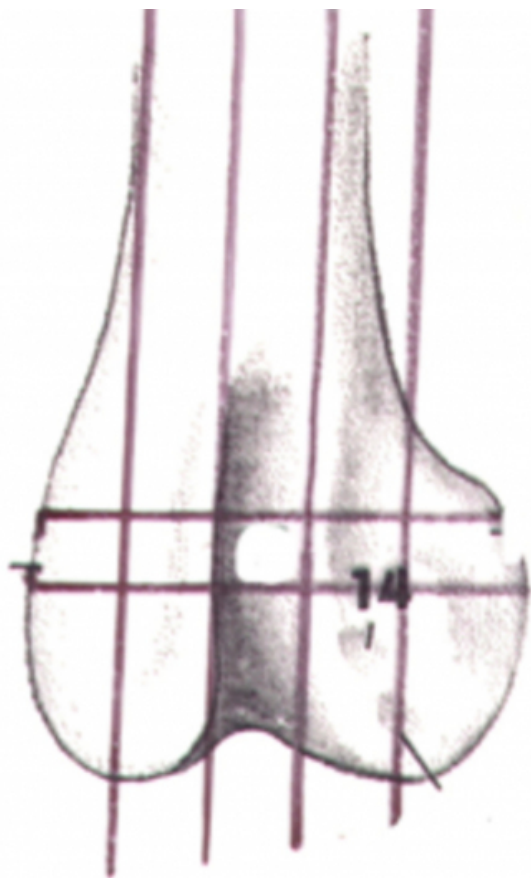
Heparins were administered subcutaneously on a daily basis and dosed as follows: UFH 133 IE/kg body weight/ day, dalteparin 50 anti-Xa-units /kg body weight/ day, certoparin 50 anti-Xa-units /kg body weight/ day.

### POST-MORTEM

After sacrifice of the animals by professional staff, the hind legs of the animals were exarticulated to ease the preparation of the distal femora. At first, the specimens were fixed in an aqueous solution of 3,8% formaldehyde for a period of one week. Then, the specimens were extensively rinsed in water for two days to remove any remaining formaldehyde and prevent its interference with subsequent steps of preparation. For dehydration, the specimens were placed into a graded ethanol series (70, 80, 90, 96 and 100%) for 7 days, respectively. Then, they were placed into a acetone/ethanol solution to further reduce fat content. The dehydrated and degreased specimens were placed into a methylmetacrylat (MMA) solution to prepare for final embedding in MMA using Technovit 7200 (Heraeus-Kulzer, Wehrheim, Germany). The specimens were fully immersed in MMA, which polymerized and dried at 35°C in an oven for a period of one week. Sections perpendicular to the axis of the implant cylinder were cut from each preparation. The sections were ground to a thickness of 100µm and polished using an EXACT device. Then, a toluidine-blue stain was used to assess the remaining osseous defect (39).

**Figure 2**

Figure 2: Schematic of a frontal cross section of a rabbit femur. Horizontal lines marking position of the milled canal. Vertical lines marking tissue cross sections histomorphometry.



## HISTOMORPHOMETRIC EVALUATION OF BONE DEFECTS

As previously established, in the absence of heparin, an osseous defect of 3,6 mm diameter at the distal femora of rabbits will be completely filled with new bone in 50% of cases (29) after 6 weeks. With the administration of heparins, a reduction in bone healing is to be expected (29), resulting in a larger residual bone defect at the end of the study interval. These remaining defects, transformed to two-dimensional tissue sections, can be quantified histomorphometrically and help to differentiate the effects on bone healing of the various heparins applied. The sections were individually analyzed using a Leitz DM/LM microscope (Leitz, Wetzlar, Germany) with digital image acquisition and analysis software DISKUS (Hilgers, Königswinter, Germany), allowing true-to-scale measurements of the defect areas.

## STATISTICAL ANALYSIS

All numeric data are given as means and standard deviations. To calculate the statistical significance of differences

between the three heparin groups and the control group, the ANOVA test was applied.

## RESULTS

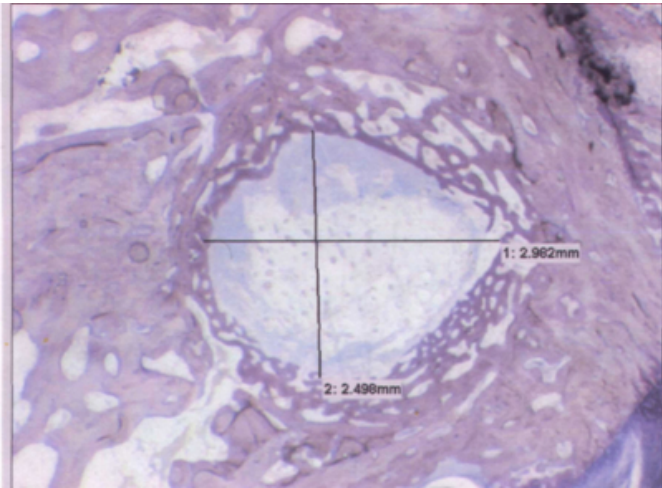
In the first group of this in vivo experiment, the animals received 0,9 % NaCl solution (physiologic saline), serving as control. All animals in this group recovered quickly from surgery and regained normal mobility during the first two weeks post-op. All animals were sacrificed after 6 weeks and both legs were prepared for histological analysis. A representative example is given in Fig. 3. The stained tissue sections displayed no indication of inflammation or excessive callus formation. The light-pink stained semitranslucent tissue around the residual defects displayed the typical morphology of woven and lamellar bone. This observation translates to prolific growth of vital bone tissue directly into the defect zone in the control group. The average defect size in the control group was  $5,01 \pm 1,73 \text{ mm}^2$ , yielding an average defect reduction of 50,7 % after 6 weeks.

In the second group, unfractionated heparin (UFH) was administered. All animals recovered well from surgery and were sacrificed after 6 weeks, as scheduled. Again, histological analysis revealed no irregular tissue or indication for an inflammatory reaction in or around the defect in any tissue section. The average defect size in the UFH group was  $5,83 \pm 1,76 \text{ mm}^2$ , translating to a defect reduction by 42,7 % after 6 weeks and indicating an inhibition of bone formation compared to the control group ( $p > 0,05$ ).



Figure 3

Figure 3: Typical tissue cross-section. The original perimeter of the defect is distinguishable by dense, lamellar bone with a homogeneous orientation of collagen fibers, whereas the newly formed bone grown into the defect displays a loose, more heterogeneous morphology typical for young, woven bone.



The third group of animals received daily s.c. shots of the LMWH certoparine (Mono-Embolex™). All animals recovered well from surgery and were sacrificed after 6 weeks, as scheduled. Histological analysis revealed no irregular tissue or indication for an inflammatory reaction in or around the defect in any tissue section. The average defect size in the certoparine group was  $5,82 \pm 1,88 \text{ mm}^2$ , translating to an average defect reduction of 42,7 % after 6 weeks. For certoparine, we found no statistically significant inhibition of bone formation compared to the control group ( $p>0,05$ ).

The fourth group of animals was treated with the LMWH dalteparine (Fragmin™). Again, all animals recovered well from surgery and were sacrificed after 6 weeks, as planned. Histological analysis revealed no irregular tissue or indication for an inflammatory reaction in or around the defect in any tissue section. The average defect size in the dalteparine group was  $5,3 \pm 1,33 \text{ mm}^2$ , indicating a inhibition of bone formation compared to the control group. This translates to a an average defect reduction of 47,9 % after 6 weeks. We were not able to establish statistical significance for these results ( $p>0,05$ ). Histomorphometrical data is provided numerically in Table 1 and shown graphically in Fig. 4.

Figure 4

Figure 4: Overall results of this study. The average remaining defects of the control group were the smallest in this experiment, indicating the most prolific bone growth after 6 weeks. The LMWH dalteparine (Fragmin) group showed less inhibition of bone growth compared to UFH and the LMWH certoparine (Mono-Embolex).

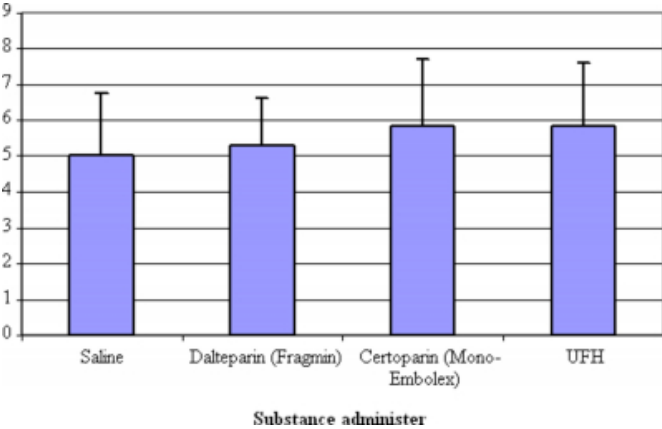


Figure 5

Table 1: Numerical data corresponding to the graph in Fig. 4

Substance	Defect after 6 weeks [mm²]	SD
Control/saline	5,01	± 1,73
Dalteparin/Fragmin	5,3	± 1,33
Certoparin/Mono-Embolex	5,82	± 1,88
Unfractionated heparin	5,83	± 1,76

DISCUSSION

In 1937, the swedish surgeon Crawford pioneered the clinical use of heparins for treatment and prophylaxis of thrombosis. Introduced more than 30 years ago, s.c. injections of heparins have become the current gold standard for the routine perioperative prophylaxis of deep vein thrombosis. Side effects like thrombocytopenia, haemorrhage or allergic reactions are not uncommon, but can typically be contained well if encountered.

Trauma patients have a comparatively high susceptibility for acquiring thrombosis and have to be monitored accordingly. By and large, patients with osteosynthesis to their lower limbs, hip or back, have to limit loading anywhere from 4 to 8 weeks, sometimes up to and in excess of 3 months post-operatively to allow the fracture to fully consolidate. During this period, the reduced mobility raises the risk for acquiring a thrombosis to up to 60 %. After its inception in the 1970s, subcutaneous heparinisation with its ease of operation and high efficacy became very successful and reduced the risk

for thrombosis from 60% to 18 % in orthopaedic patients.

However, heparins brought along a side effect with particular implication for traumatologic patients, namely reducing bone's capacity to heal, even causing osteoporosis after prologues administration. Since their introduction, subcutaneous heparins brought major advantages and improved the quality of life for millions of patients each year, but in orthopaedic disciplines, their use has remained a clinical problem to this day, leading to fracture non-unions, allograft loosening, periprosthetic fracturing, vertebral compression fractures or femoral neck fractures (<sup>2,41,42,46,51</sup>).

Asher et al. discovered the activation of a collagenase by UFH, resulting in the resorption of collagen I, a major protein of the extracellular matrix of bone cells and primary scaffold for mineralisation (<sup>3</sup>). Hurley et al. reported a suppression of collagen synthesis in rats following administration of both UFH and LMWH (<sup>21</sup>). Thompson et al. studied the mechanical properties of bone of rats subjected to UFH and found a significant reduction of breaking strength. Megard et al. supported these results by reporting significantly rarefied trabecular bone and thinning of cortical bone in a similar model (<sup>39</sup>). Muir et al. examined the parameters bone mass, osteoblast surface, osteoclast surface, serum alkaline phosphatase activity and urinary type I cross-linked pyridinoline (PYD) in rats subjected to either UFH or LMWH. Both substances significantly reduced osteoblast surface area (equivalent to cell number), but only UFH simultaneously increased osteoclast area/number (<sup>15</sup>). These results were supported by additional findings: Alkaline phosphatase activity was reduced by both substances, but only UFH simultaneously increased the amount of urinary PYD, an end product of osteoclastic bone resorption. Muir postulates two alternative explanations: (1) Both UFH and LMWH have the capacity to bind to osteoblasts, but only UFH also interacts with osteoclasts, practically doubling its adverse effect on bone healing. (2) Building upon results by Rodan, Braidman and McSheehy (<sup>7,38,45</sup>) who postulate paracrine signalling pathways between osteoblast and -clasts, he hypothesizes that UFH but not LMWH have the capacity to interfere with this signalling thus promoting osteoclast activity indirectly.

Our experiment was designed to elucidate if low-dosed unfractionated heparins or low molecular weight heparins have significantly different effects on bone healing. The bone defect model involved New Zealand white rabbits and was previously used by Kock et al. in 2002 (<sup>29</sup>). UFH was

administered at 133 IU/kg body mass/day. This is equivalent to a typical low-dose anticoagulation with 2 x 5000 IE of a 70kg female patient, for instance replacing cumarines in pregnant women with certain heart conditions. Both certoparine and dalteparine were dosed at 50 anti-Xa-units/kg body weight /day, equivalent to dosages administered perioperatively to high-risk traumatologic or orthopaedic patients. Leyvraz et al. demonstrated a clear advantage of weight-adjusted LMWH vs. serum-controlled UFH regarding efficacy of reducing perioperative thrombosis in high-risk patients. They used nadroparine, dosed between 38 and 58 anti-Xa-units /kg body weight /day (<sup>32</sup>).

Kock et al. reported a significant reduction in bone healing rate in rabbits subjected to 400 IU UFH /kg body weight/day or 80 anti-Xa-units/kg body weight/day of certoparin (<sup>29</sup>). In our study, UFH was dosed at 133 IU - a third of the amount used by Kock et al. – and continued to compromise bone healing. Both LMWH used in this study reduced bone healing as well. Our data suggests certoparine having a worse effect than dalteparine, however statistical significance for this observation could not be established.

The experiment began by surgically placing defined defects into the femoral condylae of the rabbits. Post-operatively, the animals were divided into groups of six (in one instance seven) and received daily shots of saline, and three types of heparins, respectively. The saline group was our point of reference. Using data by Kock et al., we expected 50% of the 3,6 mm defects to fill with new bone after a six week interval (<sup>29</sup>). The remaining 50% were expected to display small residual defects with both woven bone and trabecular bone grown into the defect zone from the original lamellar bone around its perimeter. The residual defect areas were quantified and served as reference for uncompromised, physiologic bone healing.

The animals in the other groups, one receiving UFH and two LMWH (certoparine and dalteparine), received injections of each substance equivalent to low-dose heparinisation in human patients. Likewise to the saline group, the residual defect areas were quantified microscopically.

After statistical analysis, we conclude that all heparins included in this study induced a non-significant reduction in bone healing rate compared to the control group, corroborating the results reported in many previous studies. When testing the UFH group vs. the certoparine (Mono-Embolex™) group we found some indication but no

statistically significant evidence for a stronger adverse effect by UFH. The statistical analysis of UFH vs. the second LMWH dalteparine (Fragmin™), again gave no significant difference between defect sizes.

While not providing statistically significant results, our animal study indicates that both UFH and LMWH interfere with bone healing, in some accordance with previous studies. However, the extent of this interference appears marginal given the possible implications of thromboembolic incidents. It is our assessment that daily LMWH administration until full mobilization should continue to be part of a proper prophylaxis of DVT in trauma patients.

## ACKNOWLEDGEMENTS

The authors of this study declare no industry relationship.

We would like to thank Mr. Mike Melchert and Mrs. E. Raby for excellent technical assistance and for manufacturing the tissue sections. This work was supported by the Interdisciplinary Center of Clinical Research on Biomaterials, IZKF Biomat, Aachen, Germany.

## CORRESPONDENCE TO

Matthias Rueger Department of Trauma Surgery RWTH University Medical Center Pauwelsstr. 30 52074 Aachen, Germany Tel.: +49-241-8088848 Fax: +49-241-8082415 e-mail: uc-labor@ukaachen.de

## References

1. Abildgaard U: Highly purified antithrombin III with heparin cofactor activity prepared by disc gel electrophoresis. *Scand J Clin Lab Invest* 21:89-91, 1968
2. Akkas N, Yeni YN, Turan B, Delilbasi E, Gunel U: Effekt of medication on biomechanical properties of rabbit bones: heparin induced osteoporosis. *Clin Rheumatol* 16(6):585-595, 1997
3. Asher JD, Nichols G: Heparin stimulation of bone collagenase activity. *Fed Proc* 24:211, 1995
4. AWMF online Leitlinien. Stationäre und ambulante Thromboembolie-Prophylaxe in der Chirurgie und der perioperativen Medizin. AWMF-Leitlinien-Register Nr. 003/001 Entwicklungsstufe: 2 + IDA
5. Barrowcliffe TW. *Br J Haematol* 90:1-7, 1995
6. Blanquaert F, Barrिताult D, Caruelle JP: Effect of heparin-like polymers associated with growth factors on osteoblast proliferation and phenotype expression. *J Biomed Mater Res* 44:63-72, 1999
7. Braidman IP, Anderson DC, Jones CJP, Weiss JB: Separation of two bone populations from fetal rat calvaria and a study of their responses to parathyroid hormone and calcitonin. *J Endocrinology* 99:387, 1983
8. Brinkhous KM, Jaques LB, Warner ED, Seegers WH: The inhibition of blood clotting: An unidentified substance which acts in conjunction with heparin to prevent the conversion of prothrombin to thrombin. *Am J Physiol* 125:683-687, 1939
9. Crisp AJ, Roelke MS, Goldring SR, Krane SM: Heparin modulates intracellular cyclic AMP in human trabecular bone cells and adherent rheumatic cells. *Ann Rheum Dis* 43:628-634, 1984
10. Dahlmann T, Sjöberg HE, Hellgren M, Bucht E: Calcium homeostasis in pregnancy during long-term heparin treatment. *Br J Obstet Gynecol* 168:1265-1270, 1992
11. De Takats G: Anticoagulants in surgery. *J Amer med Ass* 142:527, 1950
12. Donath K: Die Trenn-Dünnschlifftechnik. *Exakt-Kulzer-Druckschrift*
13. Estler CJ: Mittel zur Thromboseprophylaxe In: *Pharmakologie und Toxikologie / Lehrbuch für Studierende der Medizin, Pharmazie Naturwissenschaften Stuttgart*; New York: Schattauer, 2000
14. Forth W, Henschler D, Rummel W, Starke K: Antikoagulantien, Aggregationshemmer, Fibrinolytika und Hemmstoffe der Fibrinolyse In: *Pharmakologie und Toxikologie / Lehrbuch für Studenten der Medizin, Veterinärmedizin, Pharmazie, Chemie, Biologie sowie für Ärzte, Tierärzte und Apotheker. Mannheim, Leipzig, Wien, Zürich B I Wissenschaftsverlag*
15. Fuller K, Chambers TJ, Gallagher AC: Heparin augments osteoclast resorption stimulating activity in serum. *J Cell Physiol* 147:208-214, 1991
16. Gallus, Hirsh J: Thrombosis and Hemostasis 2,4:232-290, 1976
17. Greinacher A, Eichler P: Die Heparinassoziierte Thrombozytopenie - Klinik, Labordiagnostik, Pathophysiologie und Therapie. *DG Klinische Chemie Mitteilungen* 26:195-204, 1995
18. Handschin AE, Trentz OA, Hoerstrup SP, Kock HJ, Wanner GA, Trentz O: Effect of low molecular weight heparin (dalteparin) and fondaparinux (arixtra) on human osteoblasts in vitro. *Br J Surg* 92(2):177-83, 2005
19. Hausser HJ, Brenner RE: Low doses and high doses of heparin have different effects on osteoblast-like Saos-2 cells in vitro. *J Cell Biochem* 91(5):1062-73, 2004
20. Hirsh J: Heparin. *N Engl J Med* 324:1565-1574, 1991
21. Hurley MM, Kream BE, Raisz LG: Structural determinants of the capacity of heparin to inhibit collagen synthesis in 21-day fetal rat calvariae. *J Bone Miner Res* 5:1127, 1990
22. Kakkar VV: Low-dose heparin in the prevention of venous thromboembolism. *Thrombos Diathes Haemorrh* 33:87, 1975
23. Kakkar VV, Carrigan T, Spindler J, Fossard DP, Flute PT, Crellin RQ, Wessler S, Yin ET: Efficacy of Low Doses of Heparin in Prevention of Deep-Venous Thrombosis after Major Surgery. A Double-Blind, Randomized Trial. *Lancet* II:101-106, 1972
24. Kakkar VV, Djazaeri B, Fok J, Fletcher M, Scully MF, Westwick J: Low - Molecular Weight Heparin and Prevention of Postoperative Deep Vein Thrombosis. *Br Med J* 284:375-397, 1982
25. Kakkar VV, Laurence D, Benthey PG, De Haas HA, Ward VP, Saily MF: A Comparative Study of Low - Doses of Heparin and Heparin in the Prevention of Postoperative Deep Vein Thrombosis. *Thrombos Research* 13:111-121, 1978
26. Kakkar VV, Murray WJG: Efficacy and Safety of Low - Molecular Weight Heparin in Prevention Postoperative Venous Thrombosis. *Thromb-Embolicism a Co-Operative Study. Br J Surg* 72:786-791, 1985
27. Kock HJ, Handschin AE: Osteoblast growth inhibition by unfractionated heparin and by low molecular weight heparins: an in-vitro investigation. *Clin Appl Thromb Hemost*



Jul;8(3):251-5,2002

28. Kock HJ, Schmidt-Neuerburg KP, Hanke J, Rudofsky G, Hirche H

Thromboprophylaxis with low-molecular-weight heparin in outpatients with plaster-cast immobilisation of the leg.

Lancet 346(8973):459-61,1995

29. Kock HJ, Werther S, Uhlenkott H, Taeger G: Beeinflussung der Knochenheilung durch unfractionierte und niedermolekulare Heparine: eine tierexperimentelle Studie.

Unfallchirurg 105:791-796, 2002

30. Levine M, Hirsh J: Hemorrhagic complications of anticoagulant therapy.

Semin Thromb Hemost 12:39-57, 1986

31. Levine MN, Hirsh J, Gent M, et al: Comparing low molecular weight heparin with standard unfractionated heparin in prevention of deep vein thrombosis after elective hip surgery: a randomized trial Ann Intern Med 114:545-551, 1991

32. Leyvraz PF, Bachmann F, Hoek J, Büller HR, Tostel M, Samama M, Vandenbroek MJ: Prevention of deep vein thrombosis after hip replacement: randomised comparison between unfractionated heparin and low molecular weight heparin. Br Med J 303:543, 1991

33. Marbet GA Full Dose Heparinisation rather by Continuous or Discontinuous Heparin Infusion or by Subcutaneous Administration. Scand J Haem. Suppl 36:112-123, 1980

34. Marbet GA: Niedermolekulare Heparine: Vorteilhaftes Wirkungsprofil für Prophylaxe und Therapie venöser Thrombosen. Ther Umsch 49:843-849

35. Matziolis G, Erli, HJ, Rau HM, Klever P, Bosserhoff AK, Paar O: Heparin beschleunigt die Proliferation humaner Osteoblasten in vitro Der Orthopäde 31(6):575-81,2002

36. Matziolis G, Perka C, Disch A, Zippel H; Effects of fondaparinux compared with dalteparin, enoxaparin and unfractionated heparin on human osteoblasts.

Clacified tissue international 73(4):370-9,2003

37. Mätzsch T, Bergquist D, Hedener U, Nilsson B, Ostergaard P: Effects of low molecular weight heparin and unfragmented heparin on induction of osteoporosis in rats Thromb Haemost 63:505-509,1990

38. McSheehy PMJ, Chambers TJ: Osteoblastic cells mediate osteoclastic responsiveness to parathyroid hormone. J Endocrinology 118:824, 1986

39. Megard M, Cuche M, Grapeloux A, Bojoly C, Meunier PJ: Heparin osteoporosis : histomorphometric analysis of bone biopsy. La Nouvelle presse medicale 11(4):261-4,1982

40. Monreal M, Vinas L, Monreal L, Lavin S, Lafoz E Angles AM: Heparinrelated Osteoporosis in rats.Haemostasis 20:204-207, 1990

41. Muir JM, Hirsh J, Weitz JI, Andrew M, Young E, Shaughnessy SG. A Histomorphometric Comparison of the Effects of Heparin and Low-Molecular-Weight Heparin on Cancellous Bone in Rats. Blood 89 No9:3236-3242, 1997

42. Murray WJ,Lindo VS,Kakkar VV, Melissari E. Long-term administration of heparin and heparin fractions and osteoporosis in experimental animals. Blood Coagul Fibrinolysis;6(2):113-8, 1995 Apr

43. Mutoh S Takeshita N, Yoshino T, Yamaguchi I: Characterization of heparin-induced osteopenia in rats. Endocrinology 133:2743-2748,1993

44. Osip SL, Butcher M, Young E, Yang L, Shaughnessy SG: Differential effects of heparin and low molecular weight heparin on osteoblastogenesis and adipogenesis in vitro. Thromb Haemost 92(4):803-10,2004

45. Rodan GA, Martin TJ Role of osteoblasts in hormonal control of bone resorption - A hypothesis. Calcif Tissue Int 33:349, 1981

46. Schlachetzki J: Heparin und Knochenneubildung. Fortschr Med 87:119-122, 1969

47. Schöndorf: Dtsch med Wschr. 103:1877-1881, 1978

48. Squires JW, Pinch LW: Heparin-induced spinal-fractures. JAMA 241:2417-2418,1979

49. Stinchfield FE, Sankaran B, Samilson R: The effect of anticoagulant therapy on bone repair. J Bone Joint Surg Am 38:270-282, 1956

50. Street JT, McGrath M, O'Regan K, Wakai A, Mc Guinness A, Redmond HP

Thromboprophylaxis using a low molecular weight heparin delays fracture repair.

Clin Orthop Relat Res 381:278-89,2000

51. Thompson Jr RC: Heparin Osteoporosis. J Bone and Joint Surg. 55-A No3:606-612, 1973

52. Vin ET, Wessler S: Heparin-Accelerated Inhibition of Activated Factor X by ist Natural Plasma Inhibitor. Biochem Biophys Acta 201:387-390, 1979

53. Wessler S: Small Doses of Heparin and a New Concept of Hypercoagulability.

Thromb Diath Haemorrh 33:86, 1975

54. Geerts WH, Jay RM, Code KI, etc al. : A comparison of low-dose heparin with low-molecular weight heparin as prophylaxis against venous thromboembolism after major trauma. N Engl J Med. 1996; 335:701-707.

55. Virchow RLK. Collected assays on scientific medicine (in German). Frankfurt am Main. 1856.

56. Meissner MH, Chandler WL, Elliot JS. Venous thromboembolism in trauma:a local manifestation of systemic hypercoagulability? J Trauma. 2003; 54: 224-231

57. Agudelo JF, Morgan SJ Smith WR. Venous Thromboembolism in Orthopaedic Trauma Patients. Review. Orthopedics 2005; 28:1164.

**Author Information**

**Hans-Josef Erli**

Department of Trauma Surgery, RWTH University Medical Center

**Mike Melchert**

Department of Trauma Surgery, RWTH University Medical Center

**Matthias Rüger**

Department of Trauma Surgery, RWTH University Medical Center