

Mishaps With Endotracheal Tube Exchangers In ICU: Two Case Reports And Review Of The Literature

J Nates, D Berner

Citation

J Nates, D Berner. *Mishaps With Endotracheal Tube Exchangers In ICU: Two Case Reports And Review Of The Literature*. The Internet Journal of Anesthesiology. 1999 Volume 5 Number 1.

Abstract

INTRODUCTION

Endotracheal tube exchangers (ETTE) or airway exchange catheters (AEC) have been reported to be easy and safe to use (^{1,2,3,4,5,6,7,8,9,10}). ETTE or AEC are thin, long, rigid, hollow tubes that can be left in place as a safety device to be used as a guide for reintubation when inserted through an endotracheal tube (ETT) before its removal if extubation fails. Alternatively, AEC can be used to insufflate oxygen, monitor end tidal CO₂, or jet ventilation (¹¹). However, fiberoptic endoscopy has been suggested as a better and safer option to exchange ETTs (^{12,13,14}). Despite the wide spread use of ETTE or AEC, studies supporting their use are scarce (^{15,16}) with just a handful series lately (^{17,18,19,20}).

Recently, a surprising high failure rate exchanging endotracheal tubes has been noted by Mort et al. when using the oral approach (16). This preliminary report is the only study comparing two different ETTE found in a review of the literature using the keywords airway, exchanger, catheter, changer, endotracheal, intubation, extubation, difficult airway and fiberoptic bronchoscope with four different search engines (Grateful Med(r), Ovid(r), Healthgate Free Medline(r) and PubMed(r)) since 1966 to date. The scarce information about complications of this type leads us to report the following cases.

CASE 1

A 64 year-old white female with altered mental status secondary to an evacuated subdural hematoma, required immediate attention of her airway due to the rupture of the ETT cuff port at its origin. The patient had been weaned to pressure support/CPAP, her respiratory rate was >30 breaths/min, vital capacity <15 ml/kg and a tidal volume 200 ml (f/Vt ratio >120). Although she was maintaining her oxygen saturation above 96%, there was a large air leak, the

tidal volume was < 150 ml and it was decided to replace the ETT instead of extubation due to her previous poor pulmonary mechanics. Under sedation using intravenous propofol, 100% FiO₂ and attending supervision the anesthesia resident (PG-3) proceeded to change the oral ETT 7.5 mm-ID with a CAE (COOK(r) Airway Exchanger or CAE= C-CAE- 11.0-83). While ventilating the patient, a well-lubricated CAE was inserted through a BODAI suction safe(tm) SWIVEL Y connector attached to the oral tube. The damaged ETT was pulled out, a new ETT of the same size was introduced over the CAE as a guide down to 21-cm (teeth level), the CAE was removed and the ventilator connected. Due to the end tidal CO₂ waveform, extremely low tidal volume and breath sounds over the epigastrium, a direct laryngoscopy was performed confirming esophageal intubation and the ETT was repositioned without complications. Post-intubation chest X-rays did not show changes when compared to previous films. The patient was successfully extubated 2 days later.

CASE 2

A respiratory therapist requested the attending presence while assisting a PG-1 anesthesia resident to urgently exchange the endotracheal tube of a patient due to a large airway leak. The oxygen saturation had dropped to 91% and the patient was not ready for extubation. The 67 year-old white male had sustained a high-speed motor vehicle accident a week before and his injuries included a subdural hematoma with altered mental status, bilateral femur fractures that had been reduced surgically on arrival, and a right upper lobe lung contusion, which was in resolution. The patient was breathing spontaneously on synchronized intermittent mechanical ventilation (SIMV) with 10 cm H₂O of pressure support, the oxygen saturation was >95% on 40% FiO₂ and PEEP 5 cm H₂O. The respiratory therapist

(RT) had been inflating the cuff with larger volumes because of continuous leaking until the RT felt no further resistance (cuff rupture), no other airway problems had been reported until this point with the ETT size 8.0 mm-ID. The airway was class I, and the resident was allowed to use an endotracheal tube exchanger (COOK(r) Airway Exchanger or CAE= C-CAE- 11.0-83). After increasing the FiO₂ to 100% and giving propofol intravenously, the ventilation was assessed manually, and due to inadequate tidal volumes the patient was not paralyzed. The CAE was inserted through a BODAI suction safe(tm) SWIVEL Y connector and the ETT was pulled out, a new second ETT size 8.0 mm-ID was threaded using the CAE as a guide, the CAE was then removed and the ventilator was reconnected. No end tidal CO₂ or tidal volumes were sensed after the first 2 breaths and the attending took over the airway, and under direct laryngoscopy visualized the ETT in the esophagus. The ETT was repositioned under direct vision and after additional intravenous doses of propofol and fentanyl. No desaturation, aspiration or other complication occurred during the procedure, and a chest X ray after the exchange did not show any change, except for an ETT tip 3 cm above the carina.

DISCUSSION

ETT exchange is a simple procedure, and it does not seem to require especial training. However, these two examples of straight forward airways complicated with the use of this technique highlight the potential for losing the airway despite the fact that one of the reasons for the use of ETT exchangers is to maintain the airway and ventilation control during the procedure. After repositioning the ETT in the first patient, the defective ETT was examined carefully. The CAE was threaded through the tube, and to our surprise the CAE came out through the Murphy eye every time we tried to pass it through the removed ETT (as in the example of fig.1). We tried an Eschman catheter with the same result (as in the example of fig.2). The tube was very soft and was bent following the shape of the airway as it had been sitting in the oropharynx. We postulated then, that the tip of the ETT had been between the vocal cords when the CAE was threaded through the Murphy eye out of the trachea into the esophagus, explaining why we were able to ventilate with the CAE in position. In case #2, the tip of the ETT could have also been between the vocal cords passing the CAE through the Murphy eye into the esophagus. However, a second explanation in both cases is that, despite the respiratory therapist was holding the endotracheal tube in proper position during the exchange, the tube bent out of the trachea forced into the esophagus when threading the CAE.

In fact, excessive coiling in the hypopharynx has been reported with the consequent railroad of the ETT into the esophagus when using the Sheridan tracheal tube exchanger (16).

Figure 1

Fig 1. Cook Airway Exchange Catheter threaded through removed ETT

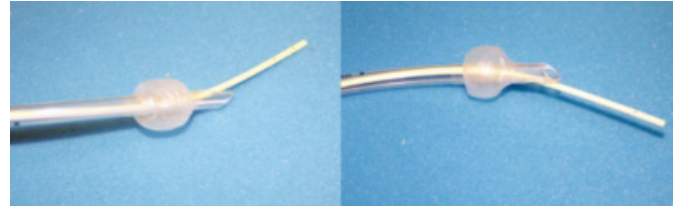
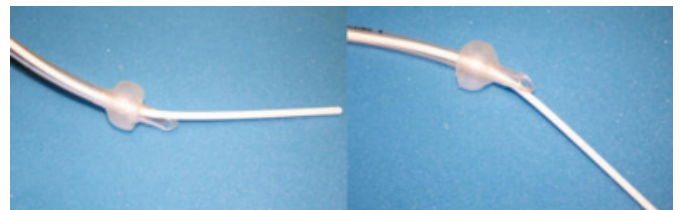


Figure 2

Fig 2. Eschman Catheter threaded through removed ETT



The AEC used in these 2 cases, the C-CAE 11.0-83, is recommended for endotracheal tubes whose inner diameter is 4 mm or larger and is small enough to pass through the Murphy eye with the potential problem of coming out through the Murphy eye instead of the tip of the ETT. On the contrary, the C-CAE 19.0-83 recommended for endotracheal tubes whose inner diameter is 7 mm does not fit through the Murphy eye but is more rigid and in our opinion, there is a higher risk of bending the ETT and displacing it into the pharynx if only a small part of the ETT is in the trachea. Though, Loudermilk et al. used the first (C-CAE 11.0-83) in a study of 40 adult patients with difficult airway without problems, and recommended its use (15).

If a tube exchanger comes out through the side hole while the ETT is still in the trachea, there is danger to damage the mucosa of the tracheal wall and even perforate the trachea or bronchial wall. There have been case reports of endobronchial rupture using tube changers (21,22). The use of a larger endotracheal tube exchanger eliminates the possibility of the exchanger coming out through the Murphy eye and it is recommended when available and feasible but, ETT partial obstruction or nasal tube exchanges require an instrument of smaller caliber and more flexibility respectively. If ventilation were necessary during the exchange with an adult size exchanger, it would have to be

through the exchanger itself requiring a different set up (jet ventilation) and of course, it would expose the patient to additional risks such as a pneumothorax from barotraumas (23).

Complications involving the Murphy eye have been reported during the passage of fiberoptic bronchoscopes (24), and curved tipped catheters (25). In the latter report, the authors stated that because selective bronchial toilette is not possible with curved tipped suction catheters, they stopped using ETT with Murphy eye routinely which is considered essential in all endotracheal tubes in opinion of other authors (26). The Murphy eye, a side hole between the cuff and the tip of the tube, was introduced in the early 40's by FJ Murphy (27) to avoid complete ETT obstruction by mucus plugs. In the last few years others have added other advantages like facilitating retrograde intubation (28), or to facilitate the intubation with the Bullard laryngoscope (29). Another advantage is to keep the right upper lobe ventilated if the ETT were to slide down into the right main bronchus (30). We consider the Murphy eye essential in any adult beveled ETT (nasal, oral, or tracheostomy tube) because the risk of obstruction increases with the angle of the bevel. The risks of eliminating the Murphy eye in the beveled ETT outnumber those with it.

The high complication rate associated with the use of ETT exchangers reported recently highlights the potential for complications associated with the use of these catheters (16). In their preliminary report of 98 patients, Mort et al. found that 60% of all patients developed hypoxemia and 8% developed bradycardia associated with hypoxemia leading to 1 episode of cardiac arrest and 2 surgical airways. Esophageal intubation occurred in 53% of the patients with the Sheridan TTX, in 26% of the patients using direct laryngoscopy and in none of the 27 patients when the tube was replaced using a Cook catheter-19F.

Endotracheal exchangers should be handled with caution; the rate of failure seems to be higher than expected depending on the type of AEC, technique and experience of the operator. The user should be aware that ETT exchange can lead to major complications that include laceration of the lateral wall, bronchial perforation with pneumothorax, loss of airway with hypoxemia and/or bradycardia, potential need of a surgical airway, cardiac arrest, or death. A clear algorithm and equipment for alternative ways to control the airway should be ready available before an ETT exchange is performed.

References

1. Bedger RC, Chang JL. A jet-stylet endotracheal catheter for difficult airway management. *Anesthesiology* 1987; 66(2): 221-3.
2. Cooper RM, Cohen DR. The use of an endotracheal ventilation catheter for jet ventilation during a difficult intubation. *Can J Anaesth* 1994; 41(12): 1196-9.
3. Deblieux P, Wadell C, McClarity Z, deBoisblanc BP. Facilitation of percutaneous dilational tracheostomy by use of a perforated endotracheal tube exchanger. *Chest* 1995; 108(2): 572-4.
4. Topf A, Eclavea A. Extubation of the difficult airway. *Anesthesiology* 1996; 85(5): 1213-1214.
5. Hartmannsgruber MW, Loudermilk E, Stoltzfus D. Prolonged use of a Cook airway exchange catheter obviated the need for postoperative tracheostomy in an adult patient. *J Clin Anaesth* 1997; 9 (6): 496-8.
6. Novella J. Intraoperative nasotracheal to orotracheal tube exchange in a patient with Klippel-Fail syndrome. *Anaesth Int Care* 1995; 23: 402-4.
7. Cooper RM. The use of an endotracheal ventilation catheter in the management of difficult extubations. *Can J Anaesth* 1996; 43(1): 90-3.
8. Cooper RM. Conversion of a nasal to an orotracheal intubation using an endotracheal tube exchanger. *Anesthesiology* 1997; 87: 717-8.
9. Drolet P, Girard M, Poiries J, Grenier Y. Facilitating submental endotracheal intubation with an endotracheal tube exchanger. *Anesthesia & Analgesia* 2000; 90 (1): 222.
10. Mandell-Brown MK, Bedger R, Chang JL, Johnson JT. Jet-stylet catheter for airway management. *Laryngoscope* 1987; 97(9):1104-5.
11. Benumof J. Airway exchange catheters for safe extubation: The clinical and scientific details that make the concept work. *Chest* 1997; 111(6): 1483-86.
12. Hartmannsgruber MWB, Rosenbaum SH. Safer endotracheal tube exchange technique. *Anesthesiol* 1998; 88: 1683.
13. Tapnio RU, Viegas OJ. An alternative method for conversion of a nasal to an orotracheal intubation. *Anesthesiol* 1998; 88: 1683-4.
14. Rosenbaum SH, Rosenbaum LM, Cole RP et al. Use of the flexible fiberoptic bronchoscope to change endotracheal tubes in critically ill patients. *Anesthesiol* 1981; 54: 169-70.
15. Loudermilk EP, Hartmannsgruber M, Stoltzfus DP, Langevin PB. A prospective study of the safety of tracheal extubation using a pediatric airway exchange catheter for patients with a known difficult airway. *Chest* 1997; 111 (6): 1660-5.
16. Mort TC, Meisterling EM, Waberski WM. Exchanging a tracheal tube in the ICU patient: A comparison of two exchangers with direct laryngoscopy. *Anesthesiology* 1997; 87 (35): 240 A.
17. Audenaert SM, Montgomery CL, Slayton D, Berger R. Application of the MIZUS endotracheal obturator in tracheostomy and tentative extubation. *J of Clin Anesthesia* 1991; 3 (5): 418-21.
18. Cooper RM. Clinical use of an endotracheal ventilation catheter for airway management: 202 consecutive cases. *Can J Anesth* 1996; 43: 90-3.
19. Atlas GM, Mort TC. Extubation of the difficult airway over an airway exchange catheter: Relationship of catheter size & patient tolerance. *Crit Care Med* 1999; 27 (12) S: A57.
20. Mort TC, Vithianantan S. Extubation of the difficult airway exchange catheter: Relationship of catheter size & patient tolerance. *Crit Care Med* 1999; 27 (1) S: 72 A.

21. Seitz PA, Gravenstein N. Endotracheal rupture from endotracheal reintubation with an endotracheal tube guide. *J Clin Anesth* 1989; 1: 214-17.
22. DeLima L, Bishop M. Lung laceration after tracheal extubation over a plastic tube changer. *Anesth Analg* 1991; 73:350-1.
23. Baraka AS. Tension pneumothorax complicating jet ventilation via Cook airway exchange catheter. *Anesthesiology* 1999; 91: 557-8.
24. MacGillivray RG, Odell JA. Eye to eye with Murphy's law. *Anaesthesia* 1986; 41(3): 334.
25. Kubota Y, Toyoda Y, Kubota H. A potential complication associated with a tracheal tube with a Murphy eye. *Anaesthesia* 1989; 44(10): 886-7.
26. Tamakawa S. Every endotracheal tube needs a Murphy eye! *Can J Anaesth* 1999; 46(10): 998-9.
27. Murphy FJ. Two improved intratracheal catheters. *Anesth Analg* 1941; 20:102-5.
28. Llew JC, Forrlor M, Forrlor C, Pottecher T. Retrograde orotracheal intubation. *Ann Fr Anesth Reanim* 1989; 8(6): 632-5.
29. Katoh H, Nishiyama J, Takigushi M et al. A better method to attach an endotracheal tube to the stylet of the Bullard laryngoscope. *Masui* 1993; 42(2): 237-41.
30. Ring WH, Adair JC, Elwyn RA. A new pediatric endotracheal tube. *Anesth Analg* 1975; 54:273-4.
31. Thompson J, Troop B, Levine J et al. Percutaneous dilational tracheostomy (PDT) in the intensive care unit. *Crit Care Med* 1998; 26(1): A243.

Author Information

Joseph L. Nates, MD, Assist. Professor

Director Neurosciences ICU, Neurosurgery and Anesthesia/Critical Care Medicine, University of Texas Medical School-Houston

Donna K Berner, MSPAS, PA-C

PAC-ICU, Neurosurgery, UCP