

Disseminated Intravascular Coagulation: A Very Rare Complication Of Neck Dissection

? Can, V Gündüz, B Baltac?, E Samim

Citation

? Can, V Gündüz, B Baltac?, E Samim. *Disseminated Intravascular Coagulation: A Very Rare Complication Of Neck Dissection*. The Internet Journal of Head and Neck Surgery. 2006 Volume 2 Number 1.

Abstract

Purpose: To present a case with lower lip squamous cell carcinoma underwent a fatal condition: Disseminated Intravascular Coagulation (DIC) during neck dissection.

Method: A case report

Result: Disseminated intravascular coagulation (DIC) often progresses in patients with malignant neoplasms, severe inflammation or multiple injuries, which induce bleeding. It is a very rare condition in head and neck surgery. In this case report, the approach to lower lip squamous cell carcinoma, the diagnosis and treatment of DIC were discussed.

Conclusion: Lower lip squamous cell carcinoma is not a benign disease. It should be treated appropriately including neck dissection. DIC is an unfortunate and uncommon condition. Although it is rare, all surgical team should be familiar with early symptoms, diagnosis and treatment of the this condition.

INTRODUCTION

Disseminated intravascular coagulation (DIC) often progresses in patients with malignant neoplasms, severe inflammation or multiple injuries, which induce bleeding. However, because the hemorrhagic symptoms of DIC cannot be observed in the early stage of the disease, the diagnosis and treatments are often delayed, and results can be fatal (1).

A case with DIC occurred during neck dissection was presented in this article. The approach to cases with lower lip carcinoma and the diagnosis and treatment of this uncommon entity were discussed in this article.

CASE REPORT

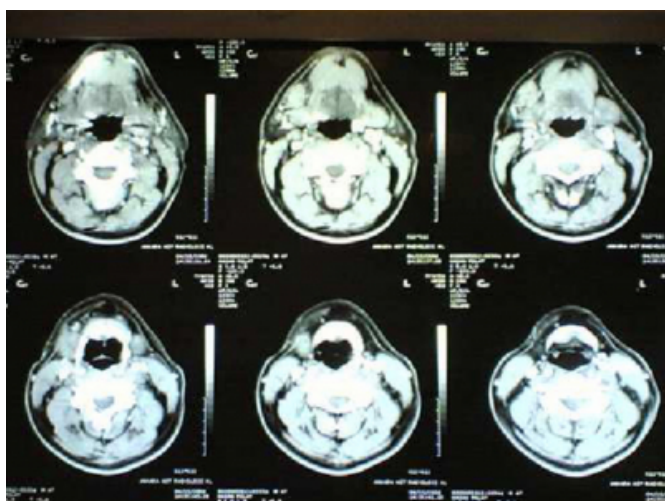
A 47 year old man applied to our ENT clinic with a history of right neck mass for 6 months. He had a wedge resection of lower lip squamous cell carcinoma almost a year ago. It was performed by a plastic surgeon. At this time, he had had a 3x2 cm lesion in the midline on the lower lip. He denied any other complaints such as weight loss, night sweating and difficulty in breathing. He smoked cigarettes for 30 years. He denied any alcoholic beverages consumption and massive sunlight exposure.

On examination, he had a vertical incision on the lower lip and a 3x2 cm fixed mass on the right submandibular region. He did not have any other disease other than this neck mass. All laboratory investigations were within normal limits. His neck scan was presented in Figure 1. The biopsy taken from the neck mass was reported as squamous cell carcinoma metastasis. Right radical neck dissection with left supraomohyoid neck dissection were performed to this patient. The operation took 2 and a half hours with no major complication or bleeding. But, during wake up period after the extubation, the patient started to ooze from the neck incision. An acute neck swelling occurred. At this time his oxygen saturation decreased. He was re-intubated again and all sutures were removed and both neck regions were evaluated for a major bleeding site. At first glance whole neck was covered by a massive, dark coloured hematoma. But there was no active bleeding site. He was hyperventilated for about 15 minutes but there was still no bleeding. His blood count was 13.6 for hemoglobin and 39 for hematocrit at this time. He was not administered any blood or blood products during surgery. This second operation took almost one hour. During wake-up period of the second operation, he could not be able to wake up. His

respiratory efforts was inadequate, his pupils were fixed-midriatic and his whole body was very cold and acral regions were cyanotic. His urine output was almost none. His oxygen saturation could not be able to be measured. His blood tests including aPTT, PT and D- dimer, blood gasses and complete blood count were runned immediately. Meanwhile, he was reentubated and connected to respiratory machine. He had cardiac arrest. He responded to resuscitation. His tests were consistent with disseminated intravascular coagulation (DIC). His PT was 56, aPTT was 198 and D-Dimer was 4695 (0-250). These values were very high. His blood gasses showed both a very deep respiratory and metabolic acidosis. The blood PH was 6.8 which we were told that it was inconsistent with life at medical school. He had a massive bleeding from operation site again and he was treated by fresh frozen plasma and blood products. After this, he had multiple organ failures including liver, kidney and pancreas and sepsis. Acinetobacter was produced on blood cultures. His hb was 6.7, white blood count was 70000 and platelet count was 20000. He did not have any urine output during the 3 week period which he lived. He had multiple peritoneal and hemodialysis during this period which did not work. His blood status and bleeding tests came to normal limits but organ failures continued. The histopathologic investigation of the main specimen showed squamous cell carcinoma metastasis in the 3 lymph nodes in right Level 1, 1 in the Level 2 and one extra-nodular invasion in the right side and 41 reactive lymph nodes in the left side. He died after 3 weeks.

Figure 1

Figure 1: The neck computed tomography of the patient.



DISCUSSION

In this article, a patient with lower lip squamous cell

carcinoma who had an inadequate surgical treatment for primary tumor and came back with a massive neck metastasis and had an unfortunate, uncommon and fatal complication: DIC during surgery was presented. There are a few questions to be discussed in this case:

- What is the treatment for lower lip squamous cell carcinoma and how should be the follow-up?
- How is DIC diagnosed and treated?
- Why did this patient have DIC?

This pateint was one of the patient who had inadequate treatment for lower lip squamous cell carcinoma and applied to our clinic for further treatment last year. We had two other patients who were operated by plastic surgeon with only wedge resection for their lower lip squamous cell carcinoma. One of them had a very massive neck metastasis and he was refered to another clinic for radio-chemotherapy. The other one was even worse than this patient. He was referred to another facility due to his insurance problem. The treatment for squamous cell carcinoma on the lower lip is resection of the lesion with ipsilateral supraomohyoid neck dissection for N0 neck and ipsilateral radical or modified radical neck dissection for N1-N3 at our clinic. If the lesion is in the midline then neck dissection is done on both sides. Neck involvement is very rare in lower lip cancers. But when it is present or when it occurs, the prognosis is very severe. So, supraomohyoid neck dissection is done as a biopsy of neck nodes. If there are positive neck nodes, the patient should be approached aggressively. Three patients applied to our clinic with same problem: neck metastasis. All these patients had had only wedge resection for their lower lip lesions. After that they were not offered a follow-up. To our opinion, the first mistake is just doing a wedge resection of the lesion without any neck dissection. The second mistake is to underlook the lower lip lesions and after resection, to say “that's it, you recovered at all, you don't need to come to follow-up”. These patients should be treated as stated above and followed-up as if other head and neck cancers.

The second question is how is DIC diagnosed and treated?

Once called consumption coagulopathy, DIC is both a bleeding and thrombotic disorder, is not a spesific diagnosis and it is always a complication of another condition such as massive trauma, bacterial sepsis, an obstetric emergency, transfusion reactions or metastatic cancer. The underlying condition triggers proinflammatory cytokines, such as the

interleukines and tumor necrosis factor alpha. These factors, in turn, activate the clotting cascade and cause microclots to form within the capillaries (2, 3). This inappropriate and excessive clotting depletes clotting factors in the circulating blood faster than the liver and bone marrow (which is responsible for platelets) can replace them. As microclots continue to form, circulating clotting factors become so depleted that a stable clot can't form at an injury site, and hemorrhage occurs. Meanwhile, clots continue to obstruct the capillaries, causing tissue and organ hypoperfusion that can lead to ischemia and necrosis. Activated to dissolve the clots, the fibrinolytic system releases fibrin degradation products. These potent anticoagulants trigger more bleeding (2).

DIC is a very rare complication of head and neck surgery. In the literature, we could not be able to find this complication related to lower lip carcinoma or neck dissection performed for lower lip carcinoma. There were cases with tonsil carcinoma and tongue carcinoma who had DIC during or after surgery. In some surgical cases, DIC occurred as a result of massive bleeding or massive transfusion due to severe bleeding. The time of surgery was another determinant in these cases (1). In our case, there were massive metastases in the neck. The surgery itself as a severe trauma or the release of procoagulant molecules from the metastatic tumor cells may have caused the occurrence of DIC.

In a study done by Morimoto et al (1), the authors examined the DIC cases in detail to identify the predictors of onset and prognosis. The clinical records of 8 patients were examined with regard to the patient's background, underlying disease, direct inducers, duration, contents of treatment and outcome. The factors which controlled the onset and prognosis of DIC were examined in cases receiving surgery for malignant neoplasms compared with non-DIC patients. The underlying diseases were 6 malignant neoplasms, one severe infection and one case of multiple fractures of the mandible. Seven patients had pretherapeutic complications and 6 patients recovered. Reduction in platelet counts immediately after the operation revealed high values up to 36%, and patients with more than 2 pretherapeutic complications were more susceptible to DIC when major postoperative complications occurred. The operation time and blood loss may also have affected the outcome (1).

Sallah et al (4) expressed that DIC is a well known hemostatic complication of solid tumors. They evaluated the

occurrence of DIC in 1117 patients with solid tumors. Of these patients, 6.8% were diagnosed with DIC. There were a total of 145 bleeding and clotting episodes reported in these patients. Thrombocytopenia, hypofibrinogenemia, elevated D-dimer and fibrinogen degradation products were the most common coagulation abnormalities encountered in patients in DIC. In multivariate analysis, older age, male gender, advanced malignancies, breast cancer and the presence of necrosis in the tumor specimen, emerged as independent factors significantly related to the occurrence of DIC in patients with solid tumors. Patients with early stage and advanced malignancies who developed DIC had inferior survival when compared with their counterparts without DIC. The occurrence of DIC appears to have an independent effect on survival of patients with cancer (4).

Survival of the patient depends on early identification and treatment of DIC and its underlying cause, so be alert for telltale clinical signs. Keep in mind that DIC doesn't follow a predictable pattern; signs and symptoms vary depending on the severity of bleeding and extent of organ and tissue damage.

Bleeding, which is often the first and the most obvious sign, may begin abruptly and quickly become severe as in our case. Blood may ooze first and frank bleeding may appear in surgical incisions. A less obvious sign of DIC is thrombosis, although clotting of major vessels is rare. More commonly, microclots block the capillaries. The patient's fingers, toes, nose and ears may become cyanotic, reflecting microvascular obstruction and tissue ischemia. If ischemia isn't reversed, it can lead to skin sloughing and other forms of tissue damage. Clotting in glomerular capillaries acute tubular necrosis and renal failure. Respiratory insufficiency, abdominal pain, confusion and seizures indicate that clots are obstructing the blood supply to other organ systems (3).

Laboratory investigation helps for diagnosis of DIC. Although no single test can diagnose DIC, several key lab results from the coagulation panel are strong indicators that the patient has the condition. Prolonged clotting times, low platelet count and fibrinogen level, and elevated D-dimer test are important in this respect.

Management of DIC consists of treating the underlying cause, restoring and maintaining the circulating blood volume, and replacing deficient clotting factors as indicated (3). The first step, as always, is to access the airway, breathing and circulation. Monitorisation of pulse oximetry and arterial blood gas values is important. Ventilatory

assistance should be provided as indicated. Removing the triggering mechanism gives the patient the best chance of recovery. In this patient, it was triggered by surgical trauma or the release of tumor necrosis factor from the surgical field or hypoxia. In these patients, preventing further hypovolemia and hypotension are top priorities by volume replacement with iv fluids and blood products. An infusion of dopamine or another vasopressor may be necessary to maintain cardiac output support organ function. Commonly, ordered therapies include fresh frozen plasma, cryoprecipitate and platelet concentrate. Packed red blood cells restore oxygen carrying capacity. Fresh frozen plasma replaces depleted clotting factors. Cryoprecipitate is indicated when fibrinogen is severely depleted. Platelet transfusion correct thrombocytopenia from ongoing bleeding. In some cases, unfractionated or low molecular weight heparin may be prescribed. It can help to break the cycle of DIC by blocking formation of new microclots. However, heparin is contraindicated in surgery patients. Epsilon- aminocaproic acid, recombinant human activated protein C and anti thrombin concentration are other possible treatment alternatives which is under investigation (2).

The third question was why this patient underwent to this condition. The surgery itself as a severe trauma or the release of procoagulant molecules from the metastatic tumor cells or a hypoxic situation during surgery may have caused the occurrence of DIC in this particular patient.

This patient was diagnosed with DIC at the first bleeding during surgery. But the blood tests results were late

eventhough they run immediately. If we could have administered fresh frozen plasma when he was first oozing, he may not have gone through this severe condition. This condition itself is a fatal condition and we don't know who will go under an easy one or who will undergo a severe fatal condition.

In conclusion, lower lip squamous carcinoma is not a benign and easy disease. It should be treated appropriately including neck dissection. DIC is an unfortunate and uncommon condition. Although it is rare, all surgical team should be familiar with early symptoms, diagnosis and treatment of the this condition.

CORRESPONDENCE TO

İlknur Haberal Can, MD Camlica Bulvar Sitesi F Blok No: 19 06800 Umitkoy Ankara Turkey Email: haberalcan@gmail.com Phone: 905325875338

References

1. Morimoto Y, Ikeuchi M, Yamamoto K, Kirita T, Sigimura M. Clinical disseminated intravascular coagulation in oral and maxillofacial regions- predictors of onset and prognosis. *Oral Diseases*. 2001;7: 291-295.
2. Dressler DK. Coping with a coagulation crisis. *Nursing* 2004;34(5):58-62.
3. Levi M, Schmaher MA. Disseminate intravascular coagulation. *eMedicine*. June 5, 2006.
4. Sallah S, Wan JY, Nguyen NP, Hanrahan LR, Sigounas G. Disseminated intravascular coagulation in solid tumor: clinical and pathologic study. *Thromb Haemost*. 2001 Sep;86(3):828-33.
5. Richey ME, Gilstrap LC 3rd, Ramin SM. Management of disseminated intravascular coagulopathy. *Clin Obstet Gynecol* 1995 Sep;38(3):514-520.

Author Information

?lknur Haberal Can, MD

Instructor, ENT Clinic, Ministry of Health Ankara Education and Research Hospital

Veli Gündüz, MD

Resident, ENT Clinic, Ministry of Health Ankara Education and Research Hospital

Bülent Baltac?, MD

Instructor, Anesthesia Clinic, Ministry of Health Ankara Education and Research Hospital

Ethem Erdal Samim, MD

Chief, ENT Clinic, Ministry of Health Ankara Education and Research Hospital