

# Inhibition Of Tumor Necrosis Factor May Improve Wound Healing And Reduce Scar Formation Following Laminectomy. A Pilot Study In Pigs.

K Olmarker

---

## Citation

K Olmarker. *Inhibition Of Tumor Necrosis Factor May Improve Wound Healing And Reduce Scar Formation Following Laminectomy. A Pilot Study In Pigs..* The Internet Journal of Spine Surgery. 2009 Volume 5 Number 2.

## Abstract

In rats treated with a selective TNF-inhibitor it was accidentally found that wound healing was improved and scar/adhesion formation was reduced. The present pilot study was performed to evaluate if this could be repeated in a controlled setting using a laminectomy model in the pig. Following anesthesia a laminectomy of all sacral vertebrae was performed in 6 pigs. Three pigs were treated with infliximab (a selective TNF inhibitor) and three pigs received saline and served as control. After 7 days the laminectomy site was evaluated by a macroscopical analysis and specimens of skin and muscle tissue over the laminectomy were processed for histology. Skin, fascia, muscle and bone healing was remarkably better in the pigs treated with infliximab. In pigs treated with infliximab there were signs of a partial healing of the laminectomy defect and in the centre of the defect there was a gel-like tissue that allowed for observation of the underlying nervous tissues. The laminectomy defect in saline treated animals had less bone formation and a soft scar in the centre of the defect. The present pilot investigation may thus indicate that an inhibition of pro-inflammatory cytokines may increase wound-healing rate and reduce scar formation/adhesion. However, further studies that evaluate exact mechanisms, when and how long to use anti-inflammatory treatment, long term effects, wound quality, risks for infection, if this may be translated to humans, must be undertaken before any conclusions regarding a clinical use may be drawn. The study nevertheless implies that it might be possible to develop a biological agent that alone or in combination with a mechanical barrier may reduce epidural scarring following spinal surgery.

## ACKNOWLEDGMENTS

This work was supported by grants from the Swedish Research Council (521-2007-2956), the Gothenburg Medical Society, AFA Insurance, the Gothenburg Medical Society, the Ollie and Elof Ericsson Foundation for Scientific Research, Stiftelsen Olle Engkvist byggmästare and the Felix Neubergh Foundation.

## CONFLICT OF INTEREST

The author is part owner and part employee of Pharmasurgics AB, Gothenburg, Sweden, a company that is developing pharmacological compounds for improving post-surgical wound healing.

## INTRODUCTION

It is common that there will be various degrees of scar tissue formation and adhesions following spinal surgery. This may induce problems if repeated surgery is needed and the scar tissue per se has even been suggested to be able to induce compression of the intraspinal nervous tissues per se (1-6).

There have been many recent attempts to control and reduce scar tissue formation. Most common is the intra operative placement of certain barriers, either by other tissues such as fat grafts or by applying specially developed compounds or even using irradiation (7-19). The outcomes have, however, not been entirely satisfactory. When harvesting nervous tissues 3 weeks after performing animal surgery with simultaneous treatment with a selective inhibitor of Tumor Necrosis Factor (TNF) in the rat, it was surprisingly noticed that epidural scar tissue formation and adhesions were remarkably reduced compared to previous experimental experiences. It even seemed that the wound-healing rate had been increased. TNF is a pro-inflammatory cytokine that mediates various inflammatory events. Inflammation is generally considered to be an integral part of the wound healing but this accidental finding thus seemed to imply that inhibition of the inflammation might be beneficial for the healing process. The present pilot study was undertaken in order to study if inhibition of the pro-inflammatory cytokine TNF would induce a reproducible reduction of scar tissue

and adhesion formation as well as to study the effects on wound healing, in a controlled experimental model of laminectomy in the pig in a limited number of animals.

## MATERIAL AND METHODS

Six pigs (body weight app. 25 kg) received an intra muscular injection of 20 mg/kg body weight of Ketalar (ketamine 50mg/ml; Parke-Davis, Morris Plains, New Jersey), an intravenous injection of 20 mg/kg body weight of Hypnodil (methomidate chloride 50 mg/ml; AB Leo, Helsingborg, Sweden), and 0.1 mg/kg body weight of Stresnil (azaperon 2 mg/ml; Janssen Pharmaceutica, Beerse, Belgium).

Anesthesia was maintained by additional intravenous injections of 2mg/kg body weight of Hypnodil and 0.05mg/kg body weight of Stresnil. The pigs also received an intravenous injection of 0.1mg/kg of Stesolid Novum (diazepam, Dumex, Helsingborg, Sweden) after surgery.

Following a midline incision, a laminectomy of the sacral vertebrae was performed. The laminectomy was standardized in the sense that it comprised all sacral vertebrae and was extended laterally to the pedicles. The muscles and skin were sutured. Three pigs received infliximab (Remicade®, Schering-Plough, Stockholm, Sweden; 4mg/kg) intravenously and three pigs received saline. After 7 days the pigs were reanaesthetized and killed and wound healing, scar formation and adhesions were macroscopically graded according to a semi-quantitative scale by a person being unaware of the experimental protocol. Tissue samples of skin and spinal muscles at the incision site were collected and processed for light microscopy.

The experimental protocol was approved by the local animal ethics committee.

## RESULTS

The data from the macroscopic evaluation are shown in table 1. The data clearly demonstrate that skin, fascia, muscle and bone healing was remarkably better in the pigs treated with infliximab. The scar in the laminectomy defect was less hard and less attached to the underlying nerves in the infliximab treated than in the saline treated animals (Table 1).

**Figure 1**

Table 1

	Skin	Fascia	Muscle	Bone h.	Consist.	Scar adh.
Control	++	+	+	++	+	+
	++	++	++	++	++	++
	(+)	++	(+)	+	(+)	0
Infliximab	(+)	(+)	0	+	(+)	0
	(+)	0	0	+	(+)	0
	(+)	(+)	0	(+)	(+)	0

Skin (healing of the skin incision):

0 = good healing, (+) = slight diastasis, + = pronounced diastasis, ++ = pronounced opening and/or infection

Fascia (healing of fascia) and Muscle (healing of muscle):

0 = good healing, (+) = slight diastasis, + = pronounced diastasis, ++ = hematoma or infection with loss of contact

Bone h. (bone healing):

0 = laminectomy healed, (+) = more than 50% of the laminectomy healed, + = 25-50% of the laminectomy healed, ++ = less than 25% healing

Consist. (consistency of the scar in the laminectomy space):

0 = like water, (+) = a gel-like clot that easily breaks, + = gelatinous but could be handled without breaking, ++ soft scar

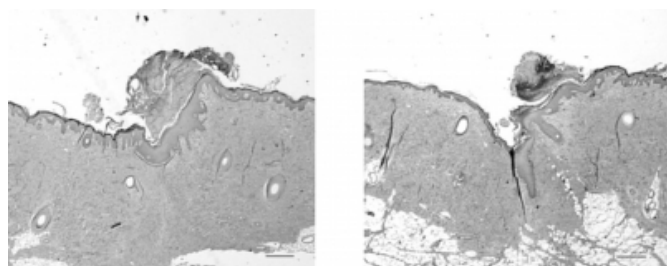
Scar adh. (adhesion of the scar to the spinal dura):

0 = no adhesion, (+) = gel-like adhesion, + = firm adhesion that is easily breakable, ++ = firm adhesion

Light microscopical analysis demonstrated that skin healing was similar between the two groups in the part of the scar where there was no diastasis (Figure 1).

**Figure 2**

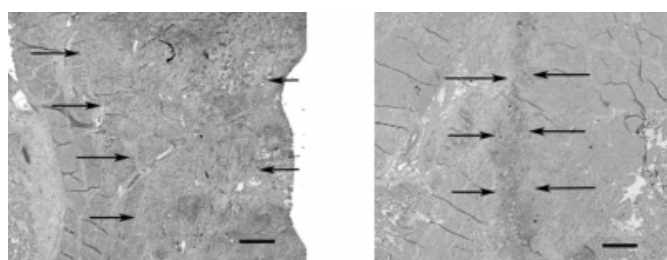
Figure 1 - skin healing: Both displayed specimens were taken where there was no diastasis of the wound. There are no remarkable differences between animals treated with saline (left) and infliximab (right) at this location of the wound. (Bar = 100Åµm, Htx-eosin).



The scar tissue in the underlying muscle was much wider in saline treated than in infliximab treated pigs (Figure 2). In the biopsies obtained from saline treated pigs there was seldom any normal muscle tissue encountered. Instead the biopsies mainly contained scar tissue. However, in infliximab treated pigs the scar was narrower and normal muscle tissue could be found outside the scar within the biopsies.

**Figure 3**

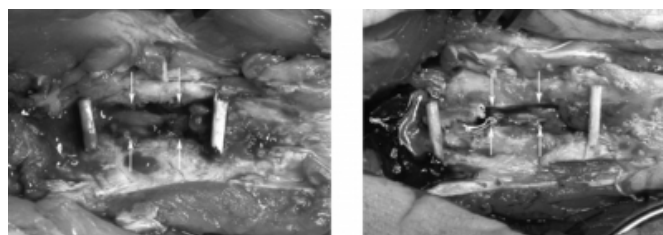
Figure 2 - muscle healing: The scar is much wider in the saline (left) treated animals than in the infliximab treated (right) animals, as indicated by the arrows. Normal muscle tissue is found just lateral to the scar in the infliximab treated animals. (Bar = 100Åµm, Htx-eosin).



The macroscopical appearance of the laminectomy site in pigs treated with saline revealed a laminectomy defect with less bone formation and a soft scar in the centre of the defect (Figure 3). Contrary, in pigs treated with infliximab there were signs of a partial healing of the laminectomy defect and in the centre of the defect there was a gel-like tissue that allowed for observation of the underlying nervous tissue.

**Figure 4**

Figure 3 - laminectomy defect: In saline treated animals (left) there is not so much bone growth and the laminectomy is almost intact. The borders of the bone growth into the laminectomy defect is indicated by white arrows. Contrary, infliximab treated animals (right) there is a clear indication of bone growth and that the former laminectomy defect is partly being overgrown. In the center of the defect there is a gel-like tissue and the nervous tissue of the spinal canal could be seen. (Left is cranial in the pictures).



## DISCUSSION

Data from the present study indicate that a reproducible reduction in scar formation/adhesion and improved wound healing may be obtained in a laminectomy model in the pig after treatment by infliximab, a selective inhibitor of TNF.

In general, wound healing is a positive physiological reaction that may restore anatomy and function of various tissues after trauma. The trauma may be accidental or the result of surgical intervention. The ideal end result of wound healing should be to restore the tissues to the situation before the trauma. One important part of the wound healing process is to form connective tissues or scar tissue that may support the healing tissues during wound healing and regeneration. However, in many cases the newly formed connective tissues (scar tissue) may interfere negatively with the normal function of the healing tissues. Wound healing with formation of new connective tissues may also induce adhesions that may induce pathological conditions per se. Adhesions and scarring may also reduce the possibilities of later surgical intervention of the injured tissue if needed. Examples of adhesions and scarring may be found virtually in any organ or tissue undergoing wound healing after trauma or surgery. Following abdominal surgery and following gynaecological surgery it is not uncommon that the surgical procedure per se may induce adhesions that may both make later surgery more difficult and even induce pathological conditions such as ileus and infertility (20-24). In spinal surgery it is common that surgery per se induces a dense scar formation called epidural fibrosis. This may in certain cases induce significant difficulties for repeated

surgery and has even been suggested to induce compression of the adjacent nerve tissue in certain cases (1-6). A method for controlling the wound healing, particularly the formation of scar tissue and adhesions, would be of a great value in most cases of posttraumatic or post surgical wound healing.

The role of inflammation in wound healing is acknowledged but not fully understood. In general it has been assumed that the inflammatory reaction is beneficial for the healing process since it increases blood flow to the injured site and also the permeability of the blood vessels, thus allowing various cells to invade the injured area. The fact that inflammation is present per se strongly suggests that this is a crucial part of the wound healing and one may suspect that interference could possibly reduce the wound healing rate and also the quality of the healed wound. However, there has been some early attempts to improve wound healing by reducing the inflammation (25, 26) and there is also recent work indicating that monitoring inflammation at the molecular level may be beneficial in certain cases of wound healing (27-29).

The present study is a preliminary pilot study performed in order to see if the accidental observation that wound healing seemed to be improved and that scar formation seemed to be reduced following simultaneous treatment with a selective inhibitor of a pro-inflammatory cytokine, Tumor Necrosis Factor (TNF), could be repeated in a controlled setting. A similar study was recently performed in rats with a non-specific TNF-inhibitor (doxycycline) and showed that 1 week following laminectomy there was less scar formation and adhesions in the doxycycline treated rats than in the control rats (30). In the present pilot study, a selective TNF-inhibitor was selected (infliximab) and administered to a larger animal. The data from the study further support that selective inhibition of the inflammatory response during wound healing may reduce adhesion formation and possibly enhance wound healing. However, the number of animals is too small to allow for any general conclusions. Another limitation is that the study only evaluates the effects after one week. It is therefore questionable if the observed scar tissue is readily transferable to a clinically manifest epidural scar. The wound healing processes is much longer and there are other mechanisms contributing to wound strength and scar formation that may occur later that could not be studied with the duration used in this study. Later studies may also employ various functional tests such as biomechanical testing of wound strength.

In conclusion, the present pilot investigation may indicate that an inhibition of pro-inflammatory cytokines may increase wound-healing rate and reduce scar formation/adhesion. However, further studies that evaluate exact mechanisms, when and how long to use anti-inflammatory treatment, long term effects, wound quality, risks for infection, if this may be translated to humans, must be undertaken before any conclusions regarding a clinical use may be drawn. The study nevertheless implies that it might be possible to develop a biological agent that alone or in combination with a mechanical barrier may reduce epidural scarring following spinal surgery.

## References

1. Benoist M, Ficat C, Baraf P, Massare C, Bard M, Sarre J, et al. [Postoperative sciatica from epidural fibrosis and lumbar arachnoiditis. Results of 38 repeat operations]. *Rev Rhum Mal Osteoartic.* 1979 Nov;46(11):593-9.
2. Biondi J, Greenberg BJ. Redecompression and fusion in failed back syndrome patients. *J Spinal Disord.* 1990 Dec;3(4):362-9.
3. Fiume D, Sherkat S, Callovin GM, Parziale G, Gazzeri G. Treatment of the failed back surgery syndrome due to lumbo-sacral epidural fibrosis. *Acta Neurochir Suppl.* 1995;64:116-8.
4. Robertson JT. Role of peridural fibrosis in the failed back: a review. *Eur Spine J.* 1996;5 Suppl 1:S2-6.
5. Samy Abdou M, Hardy RW, Jr. Epidural fibrosis and the failed back surgery syndrome: history and physical findings. *Neurol Res.* 1999;21 Suppl 1:S5-8.
6. Gambardella G, Gervasio O, Zaccone C, Puglisi E. Prevention of recurrent radicular pain after lumbar disc surgery: a prospective study. *Acta Neurochir Suppl.* 2005;92:151-4.
7. Van Akkerveken PF, Van de Kraan W, Muller JW. The fate of the free fat graft. A prospective clinical study using CT scanning. *Spine.* 1986 Jun;11(5):501-4.
8. Martin-Ferrer S. Failure of autologous fat grafts to prevent postoperative epidural fibrosis in surgery of the lumbar spine. *Neurosurgery.* 1989 May;24(5):718-21.
9. Fischgrund JS. Perspectives on modern orthopaedics: use of Adcon-L for epidural scar prevention. *J Am Acad Orthop Surg.* 2000 Nov-Dec;8(6):339-43.
10. Bora H, Aykol SV, Akyurek N, Akmansu M, Ataoglu O. Inhibition of epidural scar tissue formation after spinal surgery: external irradiation vs. spinal membrane application. *Int J Radiat Oncol Biol Phys.* 2001 Oct 1;51(2):507-13.
11. Rodgers KE, Robertson JT, Espinoza T, Oppelt W, Cortese S, diZerega GS, et al. Reduction of epidural fibrosis in lumbar surgery with Oxiplex adhesion barriers of carboxymethylcellulose and polyethylene oxide. *Spine J.* 2003 Jul-Aug;13(4):277-83; discussion 84.
12. Gorgulu A, Simsek O, Cobanoglu S, Imer M, Parsak T. The effect of epidural free fat graft on the outcome of lumbar disc surgery. *Neurosurg Rev.* 2004 Jul;27(3):181-4.
13. Alkalay RN, Kim DH, Urry DW, Xu J, Parker TM, Glazer PA. Prevention of postlaminectomy epidural fibrosis using bioelastic materials. *Spine.* 2003 Aug 1;28(15):1659-65.
14. Kemaloglu S, Ozkan U, Yilmaz F, Nas K, Gur A, Acemoglu H, et al. Prevention of spinal epidural fibrosis by

recombinant tissue plasminogen activator in rats. Spinal Cord. 2003 Aug;41(8):427-31.

15. Kim KD, Wang JC, Robertson DP, Brodke DS, Olson EM, Duberg AC, et al. Reduction of radiculopathy and pain with Oxiplex/SP gel after laminectomy, laminotomy, and discectomy: a pilot clinical study. Spine. 2003 May 15;28(10):1080-7; discussion 7-8.
16. Gerszten PC, Moossy JJ, Flickinger JC, Welch WC. Low-dose radiotherapy for the inhibition of peridural fibrosis after reexploratory nerve root decompression for postlaminectomy syndrome. J Neurosurg. 2003 Oct;99(3 Suppl):271-7.
17. Schimizzi AL, Massie JB, Murphy M, Perry A, Kim CW, Garfin SR, et al. High-molecular-weight hyaluronan inhibits macrophage proliferation and cytokine release in the early wound of a preclinical postlaminectomy rat model. Spine J. 2006 Sep-Oct;6(5):550-6.
18. Lee JY, Stenzel W, Impekoven P, Theisohn M, Stutzer H, Lohr M, et al. The effect of mitomycin C in reducing epidural fibrosis after lumbar laminectomy in rats. J Neurosurg Spine. 2006 Jul;5(1):53-60.
19. Ozer AF, Oktenoglu T, Sasani M, Bozkus H, Canbulat N, Karaarslan E, et al. Preserving the ligamentum flavum in lumbar discectomy: a new technique that prevents scar tissue formation in the first 6 months postsurgery. Neurosurgery. 2006 Jul;59(1 Suppl 1):ONS126-33; discussion ONS-33.
20. Sparnon AL, Spitz L. Pharmacological manipulation of postoperative intestinal adhesions. Aust N Z J Surg. 1989 Sep;59(9):725-9.
21. Finan MA, Barton DP, Fiorica JV, Hoffman MS, Roberts WS, Gleeson N, et al. Ileus following gynecologic surgery: management with water-soluble hyperosmolar radiocontrast material. South Med J. 1995 May;88(5):539-42.
22. Kimura H, Earashi M, Konishi K, Tsuneda A, Tazawa K,

Inoue T, et al. Strangulation ileus resulting from encasement of a loop of the small intestine by the great omentum, caused by abnormal adhesion. J Gastroenterol. 1996 Oct;31(5):714-6.

23. Liakakos T, Thomakos N, Fine PM, Derveniz C, Young RL. Peritoneal adhesions: etiology, pathophysiology, and clinical significance. Recent advances in prevention and management. Dig Surg. 2001;18(4):260-73.
24. Parker MC, Wilson MS, van Goor H, Moran BJ, Jeekel J, Duron JJ, et al. Adhesions and colorectal surgery - call for action. Colorectal Dis. 2007 Oct;9 Suppl 2:66-72.
25. Spain DM, Molomut N. Effect of cortisone on inflammation in mice; minimum dose required to affect eosinophil count, inflammation, wound healing and size of spleen. Am J Clin Pathol. 1952 Oct;22(10):944-7.
26. Houck JC, Jacob RA, Deangelo L, Vickers K. The inhibition of inflammation and the acceleration of tissue repair by cartilage powder. Surgery. 1962 May;51:632-8.
27. Wagner W, Wehrmann M. Differential cytokine activity and morphology during wound healing in the neonatal and adult rat skin. J Cell Mol Med. 2007 Nov-Dec;11(6):1342-51.
28. Mori R, Shaw TJ, Martin P. Molecular mechanisms linking wound inflammation and fibrosis: knockdown of osteopontin leads to rapid repair and reduced scarring. J Exp Med. 2008 Jan 21;205(1):43-51.
29. Oh JY, Kim MK, Shin MS, Lee HJ, Ko JH, Wee WR, et al. The Anti-inflammatory and Anti-angiogenic Role of Mesenchymal Stem Cells in Corneal Wound Healing Following Chemical Injury. Stem Cells. 2008 Jan 10.
30. Olmarker K. Reduction of adhesion formation and promotion of wound healing after laminectomy by pharmacological inhibition of pro-inflammatory cytokines: an experimental study in the rat. Eur Spine J. 2010 Dec;19(12):2117-21.

**Author Information**

**Kjell Olmarker, MD PhD**

Department of Medical Chemistry and Cell Biology, Institute of Biomedicine, University of Gothenburg