

Disseminated Tuberculosis In A Immunocompetent Patient Involving Lungs, Intestines, Brain, Bone And Soft Tissue

N Gupta, P Garg, N Hadke

Citation

N Gupta, P Garg, N Hadke. *Disseminated Tuberculosis In A Immunocompetent Patient Involving Lungs, Intestines, Brain, Bone And Soft Tissue*. The Internet Journal of Tropical Medicine. 2008 Volume 5 Number 2.

Abstract

Tuberculosis is extremely common in Indian subcontinent. It may involve virtually any system of the body. We are presenting a case of 21 years old immunocompetent female who presented to us with features of abdominal koch's. Subsequent investigations revealed tubercular involvement of lungs, intestines, brain, bone and soft tissue. Patient responded very well to antitubercular therapy.

CASE REPORT

A 21 years old female presented to surgical emergency ward, Lok Nayak hospital, Delhi in February 2007 with colicky pain abdomen, occasional vomiting, fever, productive cough and weight loss. Laboratory reports reveal hemoglobin as 10 gram%, Total leukocyte count as 12000/cu.mm, Differential count as neutrophils 40% and lymphocytes 60%. ESR was 60, Mantoux reading was 20mm after 48 hours, serum albumin was 2 g%, blood sugar, blood urea, serum Bilirubin were normal. Elisa for HIV was negative. Chest x ray revealed bilateral patchy opacities. Contrast enhanced CT scan was carried out which showed matted bowel loops with inter loop fluid collection, enlarged Para aortic lymph nodes (figure 1), lytic lesion in D 12 vertebrae with Para vertebral collection in soft tissue (figure 2).

Figure 1

Figure 1: CT abdomen showing matted bowel loops and interloop fluid.

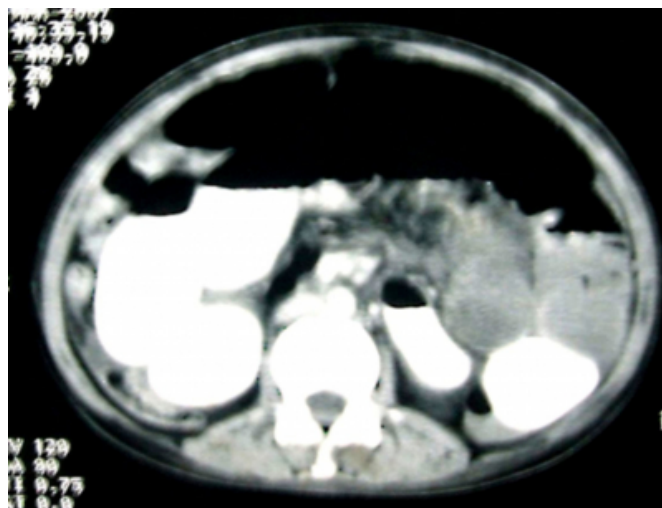
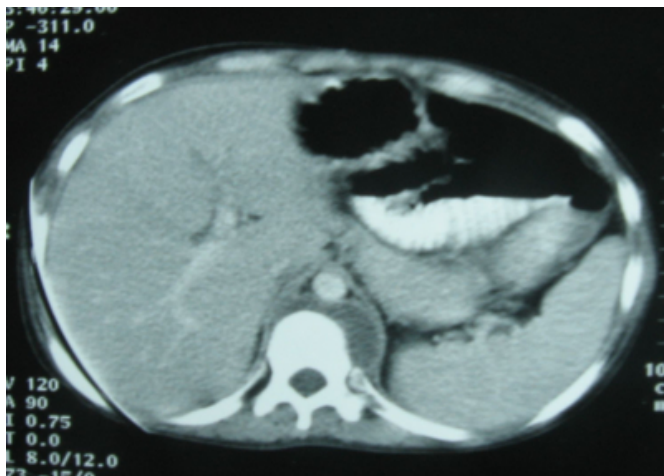

Figure 2

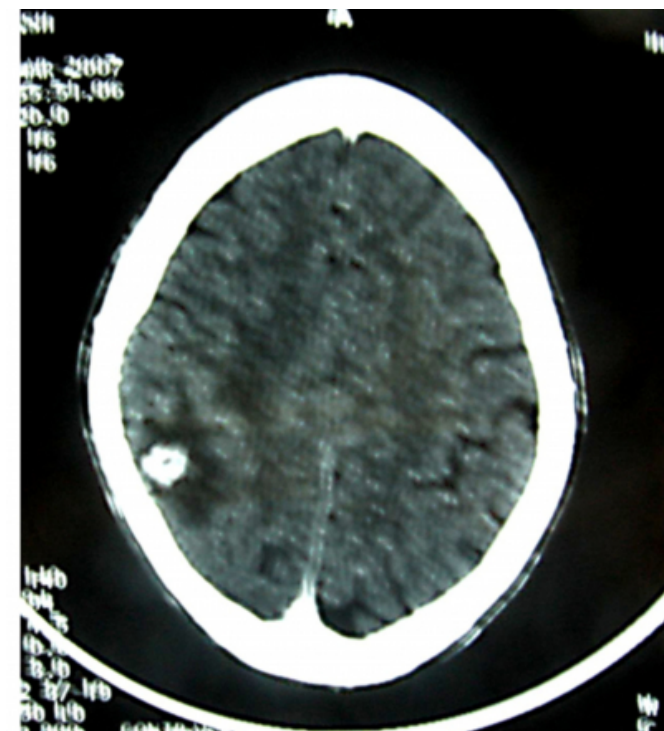
Figure 2: CT abdomen showing lytic lesion in D 12 vertebrae with paravertebral collection.



USG guided tap from abdominal fluid collection as well as from Para vertebral collection was performed which showed acid fast bacilli. Patient was managed conservatively. Antitubercular therapy was started from the next day. Patient had a seizure in the wards on the 3rd day. CT scan of the brain showed tuberculoma in right parietal region (figure 3).

Figure 3

Figure 3: CT head showing tuberculoma in right parietal region.



Prednisolone and Phenytoin was added to the treatment and patient responded well.

REVIEW OF LITERATURE

Tuberculosis is a contagious bacterial infection caused by bacterium mycobacterium tuberculosis. It is “disseminated” if it has spread from the lungs to other organs of the body by the blood or lymph system. Predisposing factors for development of disseminated tuberculosis include advanced age, HIV infection, malnutrition, diabetes mellitus, chronic renal failure, organ transplantation, corticosteroids, silicosis, connective tissue disease, immunosuppressive therapy and pregnancy [1]. Disseminated tuberculosis remains a diagnostic challenge because the presentations are nonspecific. Poor prognostic factors include hypoalbuminemia, hyperbilirubinemia, renal insufficiency and delayed anti tuberculosis treatment [2]. Various studies have shown involvement of one or two extra pulmonary sites with or with out pulmonary involvement [3,4]. We tried to search such cases (involving 4-5 systems of body) on PUBMED under title of “disseminated Tuberculosis” or “Miliary Tuberculosis” but failed to do so. Therefore we find this case worth mentioning.

References

1. Bobbak Vahid, Neil Mushlin. Miliary tuberculosis presenting as septic shock. Chest Medicine on-line.
2. Wang JY, Hsueh PR, Wang SK, Jan IS, Lee LN, Liaw YS, Yang PG, Luh KT. Disseminated tuberculosis: a 10 years experience in a medical centre. Medicine (Baltimore) 2007; 86(1):39-46.
3. Farid Z, Kamal M, Karam M, Mousa M, Sultan Y, Antosek LE. Extrapulmonary tuberculosis in patients with fever of unknown origin: clinical features and diagnosis. J Egypt Public Health Assoc. 1999; 74(5-6): 473-84.
4. Shahab T, Zoha MS, Malik A, Malik A, Afzal K. Prevalence of human immunodeficiency virus infection in children with tuberculosis. Indian Pediatrics 2004; 41: 595-99.

Author Information

Nikhil Gupta, MS, MRCS

Registrar, Department of Surgery, Maulana Azad and associated Lok Nayak hospital

Pankaj Kumar Garg, M.S.

Registrar, Department of Surgery, Maulana Azad and associated Lok Nayak hospital

N.S. Hadke

Professor, Department of Surgery, Maulana Azad and associated Lok Nayak hospital