

Cancerous Colonic Obstruction at Hepatic Flexure Relieved by Herbs: A Case Study

C Teo, C Im-Teo

Citation

C Teo, C Im-Teo. *Cancerous Colonic Obstruction at Hepatic Flexure Relieved by Herbs: A Case Study*. The Internet Journal of Alternative Medicine. 2004 Volume 3 Number 1.

Abstract

An 82-year-old female was diagnosed with colon cancer. A large mass was found obstructing the colonic passage at the hepatic flexure. The family declined surgery and opted for herbal treatment. Within two weeks, the patient's condition was restored to normacy.

INTRODUCTION

Colorectal cancer is the most common internal malignancies and is the second largest cause of death in the Western world (1, 2). Approximately 5% of Americans will develop colorectal cancer and 40% of them will die of it. The incidence of colorectal cancer increased sharply after age 40 and 90% of colorectal cancer occurred in patients above age 50. The vast majority of patients suffered from moderately differentiated to well-differentiated adenocarcinoma (3, 6).

About 16 % to 20% of patients diagnosed with colorectal cancer or acute abdomen pains presented with intestinal obstruction. The early symptom of obstruction is protracted diarrhea leading to constipation and mild abdominal pains. In acute situation, the pains could be severe. Acute colonic obstruction is a surgical emergency that must be dealt as expeditiously as possible to avoid the high fatality rate due to colonic perforation (4, 5).

It is said that 80% to 90% of all cases of colorectal cancer is due to dietary factors (6). The prevalence of colorectal cancer is mainly due to diet – high intake of meat products and animal fat and relatively low in dietary fiber (1, 7).

Surgical resection is the first line modality for treatment of all patients with colorectal cancer but of course is confined only to those who can tolerate general anesthesia only (1, 8).

CASE PRESENTATION

It was one late evening in mid-July 2005, that our friend, Chai and his wife came to our house.

Chai's 82-year old mother-in-law (let us refer to her as SK),

came down with colon cancer. She lost weight, was anaemic and could hardly walk. She was admitted into a hospital for investigation. The blood test results done on 12 July 2005, showed high white cell count, low red cell count and high platelet count (Table 1). The gastroenterologist performed a colonoscopy and found a large mass, obstructing the passage of the colonoscope, at the hepatic flexure (Fig. 1). The biopsy report of 16 July 2005, indicated infiltrating, moderately differentiated adenocarcinoma (Plate 1).

Figure 1

Table 1: Results of blood test done on 12 July 2005.

Parameters	Value
White cell count	14.6 High
Neutrophils	11.4 High
Red cell count	3.26 Low
Haemoglobin	5.5 Low
Haematocrit	18.1 Low
MCV	55.3 Low
MCH	16.8 Low
MCHC	30.3 Low
RDW	21.7 High
Platelets	499 High

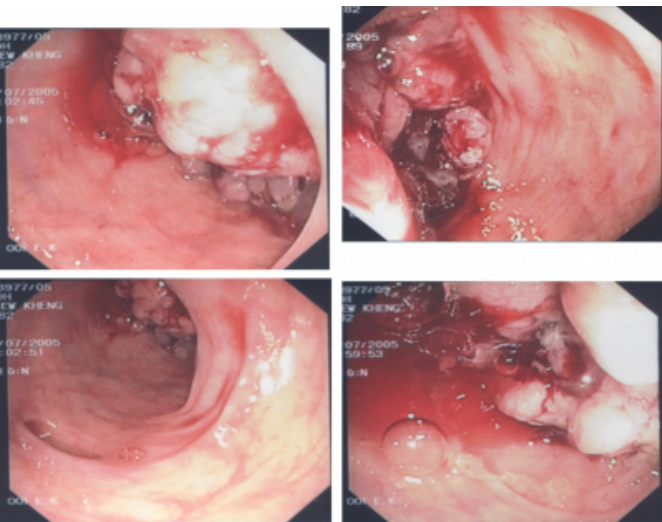
Figure 2

Figure 1: Gastroenterologist's report on the colonoscopy done on 16 July 2005

ANUS / RECTUM	Normal	<i>Bowel Prep: 8 Fleet + Fortra → Satisfactory. Insertion to Hepatic flexure</i>
LEFT COLON		
TRANSVERSE COLON		
RIGHT COLON / CAECUM		
<i>Large fungating mass, obstructing passage of colonoscope was seen at the hepatic flexure. Anastomosis biopsies taken.</i>		<i>noted just distal to the mass</i>
Reason for HPE	Therapeutic Procedure	
<i>Colon small</i>		
DIAGNOSIS		
<i>Hepatic flexure tumour</i>		
TREATMENT / COMMENTS / FOLLOW-UP		
<i>Close HPE Endo review</i>		
Doctor's Signature & Chop		
DR OOI ENG KEAT		
MBBS (Queensland), FRACP, MACA (JGTA), AM		
Consultant Gastroenterologist		
Glenagles MEDICAL CENTRE		
TEL: 2202113		

Figure 3

Plate 1: Cancerous obstruction at the hepatic flexure as seen through the colonoscope.



The doctor painted a gloomy prognosis and wanted to operate on SK immediately. On hearing the bad news, Chai's wife broke down while in the hospital. Then both Chai and his wife came to seek our opinion.

To most people, common sense dictates that there is no other option except to go for surgery – even if surgery does not cure, at least it relieves the blockage in the colon. But Chai and his wife were very hesitant to put their mother through

surgery. They asked: What if she did not undergo surgery? Our answer then was: Well, the stools will be blocked and accumulate within the colon. With time the intestine may just burst. They then asked: Can your herbs do something. Our answer was: We just don't know. We cannot see how the herbs can ever clear the blockage at all. After a lengthy discussion, we came to a compromise. We shall prescribe her herbs – Capsule A, GI 1 and GI 2. SK shall take them for at most a week or two. If there was no improvement then a surgery has to be done without further delay. At the same time, SK must immediately switch to a healthy, diet. She is to abstain from eating meat, dairy products, any food with white sugar, table salt and oil (except coconut or olive oils).

Chai and his wife took a calculated risk. Two weeks on the herbs, the health of SK was back to normal. She regained her strength and her bowel movement was good, with well formed stools. She could help with cooking and drying the family's clothes, etc. In short, she became well and was able to lead a normal life.

CURRENT SITUATION AND COMMENTS

After two months, Chai brought his mother-in-law, SK to meet us. She was a sweet 82-year-old grandmother and was so full of life. On 22 October 2005, SK came to our centre again for the second time. She told us: I am so full of strength now. I can jump and dance. The last time I saw you, my skin was flabby. Now you see, I have put on a bit of weight and my arm is rounder.

Granted, the cancer may still be there, but at least as of now, SK is leading a happy, pain-free life. She is getting used to her diet and does not grumble even though she does not take meat, milk, egg, etc., anymore. In spite of the fruit and vegetable diet that she was on, she had put on weight and had regained her health to the fullest.

One evening, we had a chat with Chai. We wondered why he and his wife family was so against going for surgery. This is the reason. Not long ago, Chai's mother had cancer of the larynx. Since there are so many siblings in the family, Chai could not make any decision by himself as regards to his mother's treatment. His brothers decided that medical treatment was what she needed. She underwent an immediate surgery, followed by radiotherapy. She suffered severe pains after the operation. The radiation treatment made her throat dry and sore. She could hardly eat and was on meager soft diet most of the time. The many sessions of radiotherapy weakened her and she could hardly walk by herself. Chai had to carry her up and down the stairs. Chai

told us: I could still remember the agony on my mother's face and the sufferings that she had to go through. It was a nightmarish experience for me. One and half years later, she died without any recovery. The family spent about RM 70,000 (about US\$ 20,000) on all the medical bills.

To Chai and his wife, modern medicine is no more the answer to their 82-year old mother's cancer. They wanted to spare her from the agony that Chai's mother had experienced.

CORRESPONDENCE TO

Chris K.H. Teo Fax: 604-6580422 Email: chris@cacare.com
Website: <http://www.cacare.com>

References

1. Tobias, J. & Eaton, K. 1996. Living with cancer. Boomsbury Publishing, London.
2. Harms, B. et al. 1999. Colon and rectum. In: Abelloff, M. et al. Clinical oncology (2nd Ed.) Harcourt Asia, Singapore.
3. McQuid, K & Fiedman, L. 2000. Diseases of digestive system. In: Tierney, L. et al. 2000. Current medical diagnosis & treatment. McGraw Hill.
4. Ali Nawaz Khan, 2004. Small-Bowel Obstruction. <http://www.emedicine.com/radio/topic781.htm>
5. Phillips K. S. et al.. Malignant large bowel obstruction. British J. Surg. 1985;72: 296.
6. Engstrom, P. 2001. Colorectal cancer. In: Lenhard R. E. et al. 2001. Clinical oncology (3rd Ed.). The American Cancer Society, Atlanta, Georgia, USA.
7. Gunderson L., et al., 2001. Alimentary cancer. In Rubin, P & Williams, J. 2001. Clinical oncology - a multidisciplinary approach for physicians and students (8th Ed.) Health Science Asia, Elsevier Science.
8. McQuid, K & Fiedman, L. 2000. Diseases of digestive system. In: Tierney, L. et al. 2000. Current medical diagnosis & treatment. McGraw Hill.

Author Information

Chris K. H. Teo, Ph. D.

CA Care Project, Teo Herbal Centre

Ch'ng Beng Im-Teo, B.Sc.(Hons).

CA Care Project, Teo Herbal Centre