

Simultaneous Fractures Involving The Metacarpal, Proximal And Distal Phalanges Of The Thumb Ray

R Botchu, R Sathyanarayana, N Gopalakrishnan, V Kakar, K Ravikumar

Citation

R Botchu, R Sathyanarayana, N Gopalakrishnan, V Kakar, K Ravikumar. *Simultaneous Fractures Involving The Metacarpal, Proximal And Distal Phalanges Of The Thumb Ray*. The Internet Journal of Orthopedic Surgery. 2005 Volume 3 Number 1.

Abstract

Fractures of the hand are a common injury. We report the case of a forty year old man who sustained three separate fractures of his right thumb, following a fall. One of the fractures required stabilisation with 2 kirschner wires. He made a full recovery. Such an uncommon injury re-emphasizes the need for a holistic approach to hand injuries.

INTRODUCTION

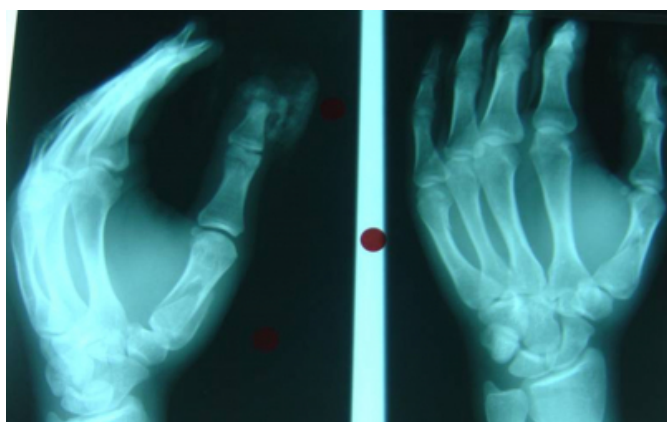
Fractures of the hand are a common injury. We report a rare case of simultaneous fractures of the metacarpal, distal and proximal phalanges of the thumb ray.

CASE REPORT

A forty year old right handed male presented with a swollen right hand after coming off a bike. Examination revealed diffuse swelling, bruising and tenderness over first metacarpal, proximal and distal phalange with a laceration at the base of the nail without any distal neuro-vascular deficit. Radiographs showed fractures of the first metacarpal, head of proximal and distal phalanges of the thumb (figure 1).

Figure 1

Figure 1: Antero-posterior and lateral radiographs of the right hand showing fractures of the first metacarpal, proximal and distal phalanges of the first ray

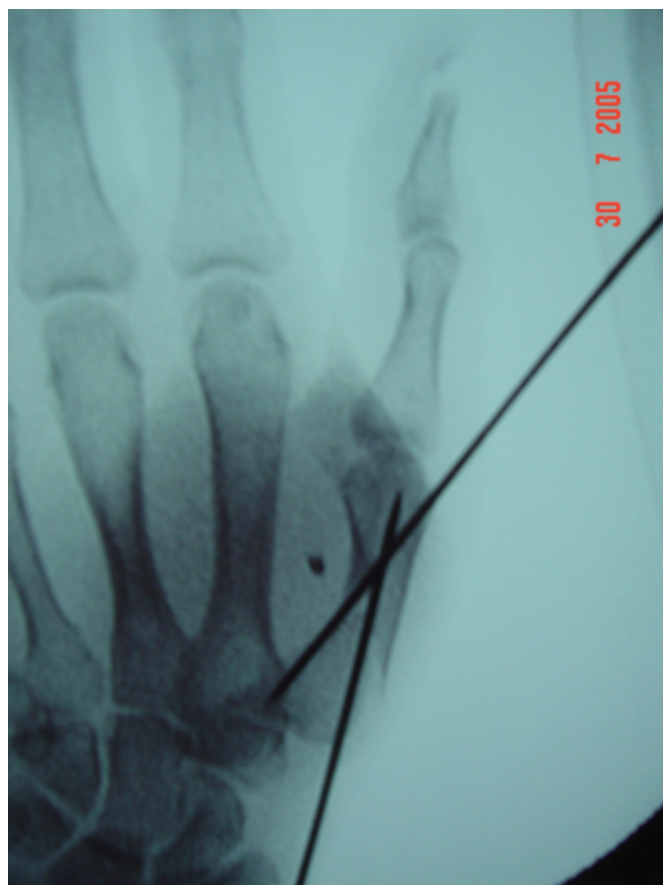


He had extensive debridement of the wound, primary closure of the laceration and stabilization of the fracture of the first

metacarpal with two 1.6mm Kirschner wires (figure 2). Thumb spica was applied for 3 weeks. A full functional recovery followed.

Figure 2

Figure 2: Post operative radiograph showing fixation of the first metacarpal fracture with two 1.6mm Kirschner wires



DISCUSSION

Multiple finger fractures involving phalanges or metacarpals of adjacent rays have been described in the literature¹. There has been no reported case of injury involving more than two bones of the same ray following a fall. Hove LM in the series of one thousand consecutive fractures involving hand reported that the fractures of metacarpals and phalanges accounted for 36% and 46% respectively². Liew and colleagues have reported that metacarpal fractures can be treated with k-wires with good functional result³.

Multiple fractures involving phalanges and metacarpals of the same ray are very rare. This case emphasizes the need to carefully exclude fractures of the adjacent bones of the same ray.

CONCLUSION

Multiple fractures involving phalanges and metacarpals of the same ray are very rare. This case emphasizes the need to carefully exclude fractures of the adjacent bones of the same ray.

CORRESPONDENCE TO

Mr R Botchu 5 Magnolia House Springwood Close
Maidstone ME16 9PB Ph 0044 7967505057 Email –
drbrajesh@yahoo.com

References

1. Fischer MD, McElfresh EC. Physeal and periphyseal injuries of the hand. *Hand Clinics*; 1994, 10(2):287-301
2. Hove LM. Fractures of the hand. Distribution and relative incidence; *Hand Clinics* .1994 May; 10(2):287-301.
3. Liew KH, Chan BK, Low CO. Metacarpal and proximal phalangeal fractures-fixation with multiple intramedullary Kirschner wires; *Hand Surg*. 2000 Dec; 5(2):125-30

Author Information

R. Botchu

R. Sathyanarayana

N. Gopalakrishnan

V. Kakar

K. J. Ravikumar