

# Splenic Infarct – An Unusual Complication Of Gastrectomy For Cardia Carcinoma

A Ring, E Stein, J Stern

## Citation

A Ring, E Stein, J Stern. *Splenic Infarct – An Unusual Complication Of Gastrectomy For Cardia Carcinoma*. The Internet Journal of Surgery. 2008 Volume 21 Number 1.

## Abstract

A case of splenic infarct secondary to gastrectomy for cardia carcinoma is reported. Insufficient perfusion via atherosclerotic splenic artery under the condition of absent collateral flow through short gastric arteries is supposed as the cause for postoperative development of splenic infarction.

## INTRODUCTION

Surgery still remains the only proven curative treatment modality for gastric cancer. The R0-resection of the tumour is the most important prognostic factor. At present there is no consensus about the optimal extent of lymph node dissection [1]. Removal of splenic hilar lymphnodes by prophylactic splenectomy is generally not recommended because of the uncertain impact on survival and the high morbidity rates. As a matter of fact, the spleen-preservation demonstrated shorter operation times, a lower incidence of perioperative transfusion, and shorter postoperative hospital stay. The D2 lymphadenectomy with spleen preservation was shown to be an effective method for radical surgery in locally advanced proximal gastric cancer [2, 3]. Currently, gastrectomy with preservation of the spleen is the standard procedure.

Here, we report an unusual case of 59-year-old man who developed an infarct of the spleen secondary to spleen-preserving gastrectomy.

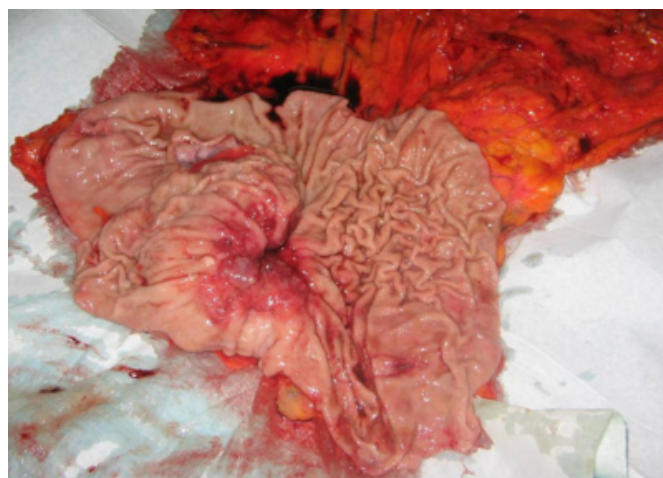
## PATIENT AND METHODS

The patient underwent total gastrectomy for Lauren diffuse-type adenocarcinoma of proximal cardia Siewert type III (Fig. 1). Apart from that, his clinical history was uneventful. Reconstruction was performed by stapled terminolateral oesophagojejunostomy and Y-Roux. Prior to surgery, the patient underwent chemotherapy consisting of 5-FU, epirubicin and cisplatin. Postoperative histology showed minor regression of the adenocarcinoma. The TNM staging was pT2 pN3 M0 R0 (UICC stage IV). The initial postoperative course was uneventful. However, on day 10

after surgery the patient developed chills and fever. The clinical examination showed no abdominal affection. Laboratory test revealed elevation of leukocytes and C-reactive protein.

## Figure 1

Figure 1: The preparation shows the carcinoma lesion of the cardia.



## RESULTS

Gastrografin swallow excluded a late disruption of the oesophagojejunal anastomosis. However, a CT scan of the abdomen revealed an extended, wedge-shaped, lesion within the splenic parenchyma suggestive of splenic infarct (Fig. 2A,B). A filiform perfused splenic artery with segmental calcified atherosclerosis was detected (Fig. 3).

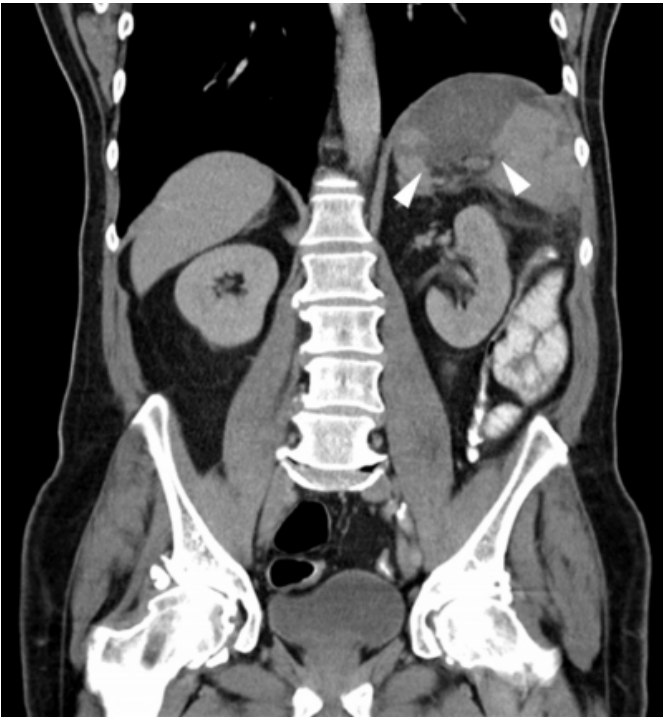Intraabdominal abscess formation was not found. The patient was started on ceftriaxone and metronidazol. Immunization against pneumococcus was performed.

The further course was complicated by the development of splenic abscess (Fig. 4A,B). Relaparotomy for splenectomy and lavage was performed. Unfortunately, the patient died from a fulminant pulmonary embolism two days later.

Figure 2: CT scans of the abdomen. Frontal (A) and transversal (B) CT scan depicting a wedge-shaped splenic infarct (arrowhead)

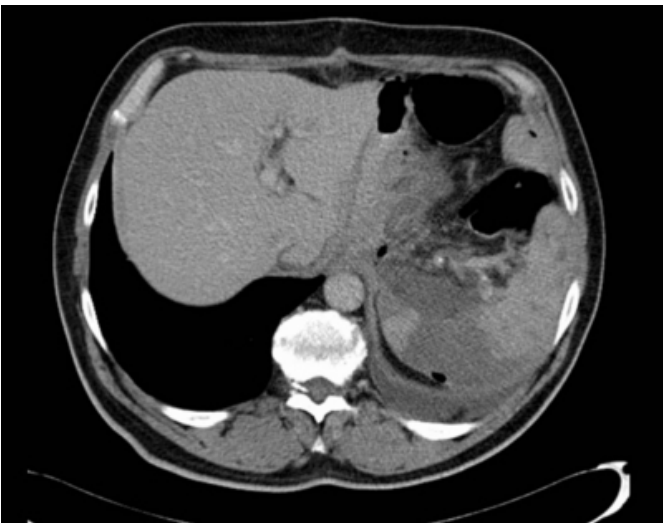**Figure 2**

Figure 2A



**Figure 3**

Figure 2B



**Figure 4**

Figure 3: Transversal CT scan demonstrating calcified plaques in the atherosclerotic splenic artery (arrows)

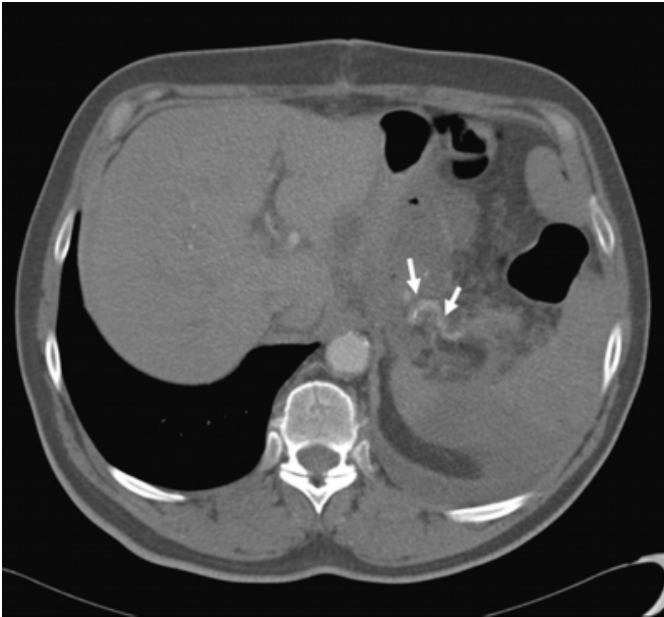
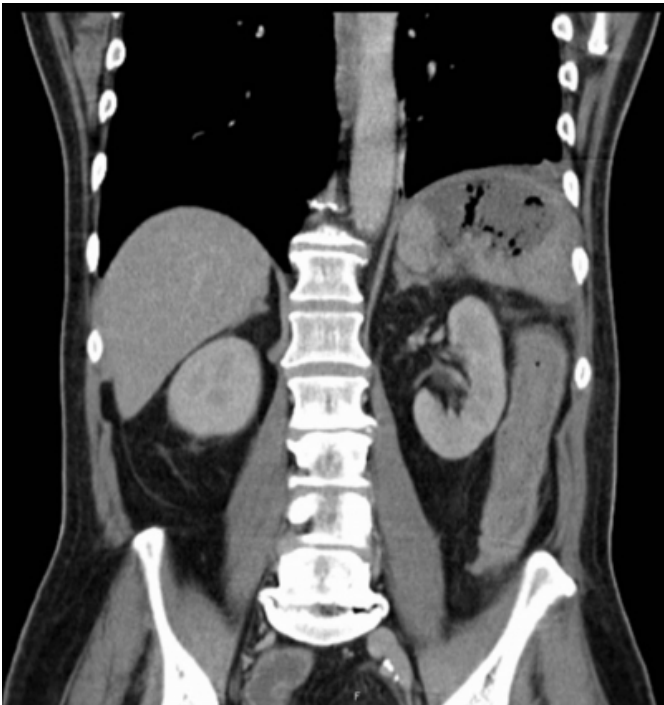


Figure 4: The frontal (A) and transversal (B) CT scans of the abdomen show the splenic abscess with gas-enclosures.

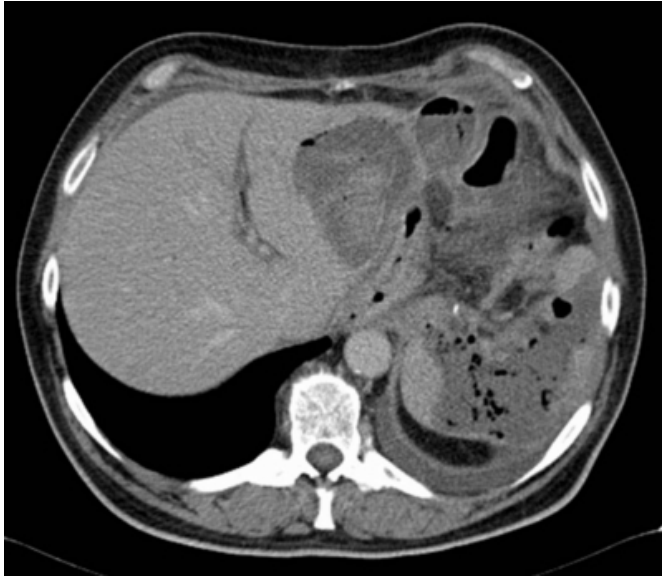**Figure 5**

Figure 4A



**Figure 6**

Figure 4B



## DISCUSSION

Splenic infarction refers to occlusion of the splenic vascular supply. It is the result of arterial or venous compromise and is associated with a heterogeneous group of diseases. Usually, haematological and myeloproliferative disorders like sickle haemoglobinopathy, polycythemia vera, leukaemia, lymphomas and myelofibrosis are associated causes for splenic infarction. These diseases can cause congestion of the splanchnic circulation by abnormal cells or thromboembolic conditions that produce vascular occlusion. Further associated causes are autoimmune collagen and vascular diseases, e.g. a systemic lupus erythematoses, Kawasaki disease, Wegener granulomatosis and polyarteritis nodosa. Also infections like meningococcaemia, infectious mononucleosis, malaria and salmonellosis were associated with splenic infarct. In addition, cardiac embolic disorders in atrial fibrillation, endocarditis or valvular failure were reported to cause splenic infarction [4-8].

Blunt abdominal trauma is also a rare traumatic aetiology of splenic infarction [9]. Similarly, the splenic infarct is known as complication of catheter embolisation in non-operative management of blunt splenic trauma [10].

A surgical condition in which splenic infarct occurs is in recipients of living donor liver transplantation with hyperdynamic splanchnic circulation resulting in graft hyperperfusion and increased portal vein flow. Here, the ligation of the splenic artery, as a method to prevent occurrence of the small-for-size syndrome, may cause splenic infarct [11].

Similarly to splenic artery embolisation in trauma, embolisation of the splenic artery for arterial steal syndrome in patients with impaired liver function after liver transplantation may also lead to infarct of spleen [12].

Besides, other interventional conditions as transluminal coeliac artery stenting, endoscopic cyanoacrylate injection for oesophageal varices, and laparoscopic Nissen fundoplication were reported to be associated with splenic infarction. In all these cases the pathophysiological mechanism is the breakdown of blood supply to the spleen resulting from a lesion of the splenic artery [13-15].

In the case reported, an incident of a postoperative thromboembolic event may be the most reasonable pathophysiological explanation. The main arterial supply to the spleen is through the splenic artery. However, the arterial supply is also augmented by the short gastric vessels that branch from the left gastroepiploic artery. The mobilizing of the greater curve of the stomach includes division of the short gastric vessels, which are usually believed to be of subordinate value for the blood supply of the spleen [16]. We suppose that most likely, a plaque rupture and subtotal occlusion of the atherosclerotic splenic artery by plaque embolism may have occurred. In the absence of collateral flow via short gastric arteries that may have caused the splenic infarct.

Splenic infarction after gastrectomy is an unusual pathological finding. However, it should be considered as a possible complication in patients with atherosclerosis of the splanchnic area undergoing gastrectomy. Although total gastrectomy combined with splenectomy for lymph node dissection in proximal gastric cancer is associated with poor surgical outcome, in a case of a preoperatively recognized significant atherosclerosis of the splenic artery this procedure should be discussed.

## CONCLUSION

Splenic infarction should be taken into account as a rare complication in patients with splenic atherosclerosis undergoing gastrectomy.

Treatment strategies in case of splenic infarction may include a trial of conservative management with close follow-up. Splenic infarction alone is not an indication for surgery. However, splenectomy is indicated in the presence of complications resulting from infarction such as secondary abscess formation.

## References

1. Roukos DH. Current status and future perspectives in gastric cancer management. *Cancer Treat Rev* 2000;26(4):243-55
2. Cheong O, Kim BS, Yook JH, Oh ST, Park YK, Ryu SY. Modified radical lymphadenectomy without splenectomy in patients with proximal gastric cancer: comparison with standard D2 lymphadenectomy for distal gastric cancer. *J Surg Oncol* 2008;98(7):500-4
3. Oh SH, Hyung WJ, Li C, Song J, Kang W, Rha SY, Chung HC, Choi SH, Noh SH. The effect of spleen-preserving lymphadenectomy on surgical outcomes of locally advanced proximal gastric cancer. *J Surg Oncol* 2009;99(5):275-280
4. Jaroch MT, Broughan TA, Hermann RE. The natural history of splenic infarction. *Surgery* 1986;100(4):743-50
5. O'Keefe JH Jr, Holmes DR Jr, Schaff HV, Sheedy PF 2nd, Edwards WD. Thromboembolic splenic infarction. *Mayo Clin Proc* 1986;61(12):967-72
6. Nores M, Pilleps EH, Morgenstren L. The clinical spectrum of splenic infarction. *Ann Surg* 1998;64(2):182-8
7. Ting W, Silverman NA, Arzouman DA, Levitsky S. Splenic septic emboli in endocarditis. *Circulation* 1990;82(5 Suppl):IV105-9
8. Sheikha A. Splenic syndrome in patients at high altitude with unrecognized sickle cell trait: splenectomy is often unnecessary. *Can J Surg* 2005;48(5):377-81
9. Kluger Y, Paul DB, Townsend RN. Enhanced rim around infarcted, traumatized spleen on computed tomographic scans: case report. *J Trauma* 1994;36(3):436-7
10. Wu SC, Chen RJ, Yang AD, Tung CC, Lee KH. Complications associated with embolization in the treatment of blunt splenic injury. *World J Surg* 2008;32(3):476-82
11. Balci D, Taner B, Dayangac M, Akin B, Yaprak O, Duran C, Uraz S, Hayzaran S, Ayanoglu O, Killi R, Senturk H, Yuzer Y, Tokat Y. Splenic abscess after splenic artery ligation in living donor liver transplantation: a case report. *Transplant Proc* 2008;40(5):1786-8
12. Vogtl TJ, Pegios W, Balzer JO, Lobo M, Neuhaus P. Arterial steal syndrome in patients after liver transplantation: transarterial embolisation of the splenic and gastroduodenal arteries. *Rofo* 2001;173(10):908-13
13. Almeida JA, Riordan SM. Splenic infarction complicating percutaneous transluminal coeliacal artery stenting for chronic mesenteric ischemia: a case report. *J Med Case Reports* 2008;6(2):261
14. Martins Santos MM, Correia LP, Rodrigues RA, Lenz Tolentino LH, Ferrari AP, Della Libera E. Splenic artery embolization and infarction after cyanoacrylate injection for oesophageal varices. *Gastrointest Endosc* 2007;65(7):1088-90
15. Wilkinson NW, Edwards K, Adams ED. Splenic infarction following laparoscopic Nissen fundoplication: management strategies. *JSLS* 2003;7(4):359-65
16. Roth H, Zachariou Z, Daum R. [Arterial blood supply of the upper pole of the spleen in main artery occlusion.] *Chirurg* 1987;58(12):828-30

**Author Information**

**Andrej Ring, MD**

**Erwin Stein, MD**

**Josef Stern, MD, PhD**