

# Pneumothorax necessitans as a complication of closed tube thoracostomy

R Garg, S Singhal, P Srivastava

## Citation

R Garg, S Singhal, P Srivastava. *Pneumothorax necessitans as a complication of closed tube thoracostomy*. The Internet Journal of Radiology. 2006 Volume 7 Number 2.

## Abstract

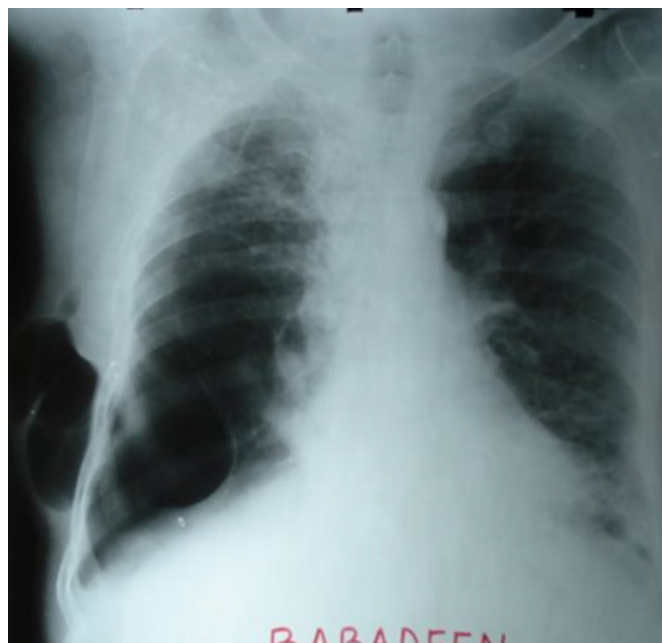Localized "pneumothoracocoele" formed due to air entrapment from a subsequent pneumothorax is termed as "pneumothorax necessitans". Only one other case of pneumothorax necessitans developed as a complication of sternoclavicular joint infection has been reported<ENDNOTENUMBER>1</ENDNOTENUMBER>.

## CASE REPORT

A 70 year old male, farmer by occupation presented with the complaint of increased breathlessness and cough with minimal expectoration for 5 days. He was a chronic smoker (28 pack years) with no alcohol and drug abuse. The patient was also a known case of chronic obstructive pulmonary disease (COPD) for last 5 years for which he was taking irregular bronchodilator therapy. Physical examination revealed a soft, crepitant bulge in the right infra-axillary region with volume of the bulge increasing during coughing or Valsalva's maneuver. Previously, he had tuberculous empyema on the same side which was drained with chest tube along with adequate antitubercular treatment. On auscultation rhonchi were audible on left side with decrease in breath sound on right side. Examination of other systems was unremarkable. A chest radiograph showed loculated pneumothorax on right side communicating with a large subcutaneous air collection which was also confirmed by computed tomography scan (figure1-3).

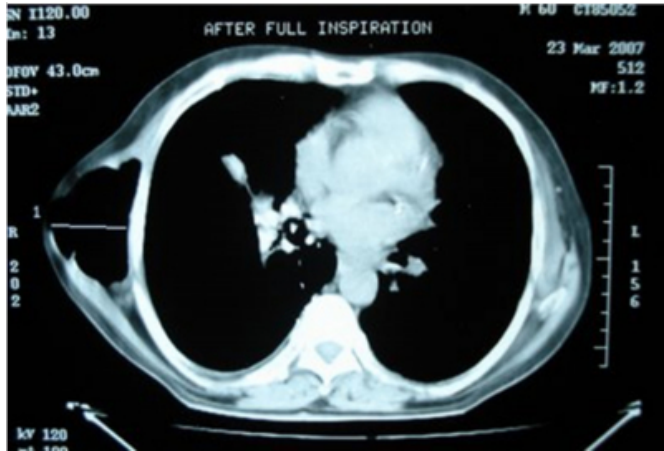## Figure 1

Figure 1: Chest radiograph showing loculated pneumothorax along with subcutaneous air collection



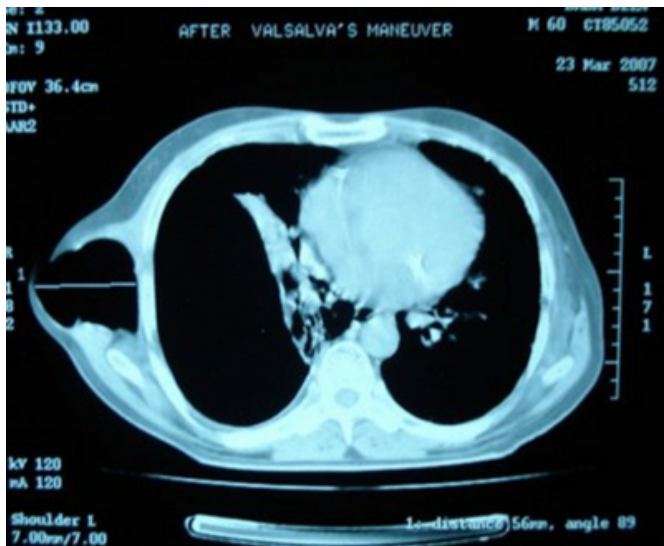
## Figure 2

Figure 2: CT thorax showing pneumothorax necessitans in full inspiration



### Figure 3

Figure 3: CT thorax showing increase in size of pneumothorax necessitans after Valsalva's maneuver



He was given inhaled bronchodilator to control COPD exacerbation. After controlling symptoms of COPD exacerbation, the patient was referred to the department of surgery.

## DISCUSSION

Pleural thickening<sub>2</sub>, empyema thoracic and empyema necessitans<sub>3</sub> are the well known complication of tuberculous pleural effusion and the Intercoastal hernia<sub>4</sub> are the known complication of tuberculous empyema drained with chest tube, but pneumothorax necessitans as a complication of tuberculous empyema drained with chest tube has not been reported previously. Decreased resistance of the thoracic wall as a result of previous intercostal chest tube drainage and abnormally high intrathoracic pressure as a result of uncontrolled COPD may be the cause of pneumothorax necessitans in our case.

## References

1. Tripathi SP, Massad MG, Mehta VK, Benedetti E, Geha AS. Pneumothorax necessitans presenting as a presternal pneumatothoracocoele. *Ann Thorac Surg* 2000; 69: 266-7.
2. Barbas CSV, Cukier A, de Varvalho CRR, Barbas Filho JV, Light RWL. The relationship between pleural fluid finding and the development of pleural thickening in patients with pleural tuberculosis. *Chest* 1991; 100: 1264-7.
3. Glicklich M, Mendelson DS, Gendel ES, Teirstein AS. Tuberculous empyema necessitans. *Clin Imaging* 1990; 14: 23-5.
4. Bhalla M, Leitman BS, Forcade C, Naidich DP, McCauley DI. Lung Hernia: Radiographic features. *AJR* 1990; 154: 51-3.

**Author Information**

**Rajiv Garg**

Assistant Professor, Department of Pulmonary Medicine, King George's Medical University

**Sanjay Singhal**

Department of Pulmonary Medicine, King George's Medical University

**Piyush Srivastava**

Ex-resident, Department of Pulmonary Medicine, King George's Medical University