

The Effect Of Amodiaquine On The Histomorphology Of The Spleen Of Wistar Rats

M Ekong, A Igiri, O Mesembe, Q Ojohu

Citation

M Ekong, A Igiri, O Mesembe, Q Ojohu. *The Effect Of Amodiaquine On The Histomorphology Of The Spleen Of Wistar Rats*. The Internet Journal of Health. 2008 Volume 8 Number 2.

Abstract

This study was to ascertain the effect of the administration of amodiaquine (AQ) on the histomorphology of the spleen of Wistar rats. Twenty adult Wistar rats weighing between 150-180g were divided into four groups (A, B, C and D) of eight animals each. Group A served as the control and the animals received distilled water, while groups B, C and D were the experimental groups. The drug was administered as 17.50mg/kg, 8.75mg/kg and 8.75mg/kg for groups B, C and D respectively. The administration lasted three days for groups B and C, while group D administration lasted six days. Histomorphological sections showed increased size of the white pulp, hypertrophied and hyperplastic red pulp parenchymal cells in group C, while groups B and D showed decreased white pulp sizes, and hypertrophied red pulp parenchymal cells. This is an indication of lymphocyte destruction. Thus, these results suggest that over-dose and chronic doses of AQ is detrimental to the spleen, therefore excess dosage should not be taken especially as a prophylactic.

The study was carried out in the Laboratory of Anatomy Department, Faculty of Basic Medical Sciences University of Calabar, Calabar-Nigeria

INTRODUCTION

Malaria is the leading cause of morbidity and mortality and remains a major health problem in the sub-Saharan Africa ¹. In the 19th century, quinine and the quinolones including amodiaquine were the drugs of choice due to their cheap nature and high efficacy. But their use was soon short-lived due to the different adverse effects, as well as, the parasites resistance ².

Amodiaquine (AQ), a 4-aminoquinoline antimalarial agent, was introduced because of its effectiveness against both resistant and sensitive strains of *Plasmodium falciparum*, the cause of cerebral malaria ³. However, a number of cases of fatal agranulocytosis, as well as hepatotoxicity in patients during prophylactic administration, led to its withdrawal from use ^{4,5,6}.

The rise in the resistance to current antimalarial drugs by the malarial parasites led to the recommendation by the World Health Organization that conventional drugs be combined with artemisinin derivatives due to the fact that artemisinin drugs have high efficacy and low resistance ⁷. This proclamation led to the re-introduction of old drugs like

AQ.

One of such artemisinin-based combinations is Larimal, a combination of artesunate (AS) and AQ ⁸. Though the efficacy of the combined drugs is better compared to monotherapy, the effect of these combined drugs is usually seen in their individual components as each component acts independently of each other ⁹.

AQ, is commonly known as camoquine is a potent inhibitor of histamine N-methyltransferase ¹⁰, it acts by accumulating in the lysosomes of the parasites bringing about loss of its function, and also binds to their nucleoproteins inhibiting the DNA and RNA polymerase which end up generating free radicals ^{11,12}. It was withdrawn from general use because of reports of severe and often fatal agranulocytosis and hepatotoxicity ^{4,5,6,13}. The withdrawal of this drug really limited further research on its effects on other parts of the body. A study carried out has shown that this drug does not only have antimalarial properties, but also has antipyretic and anti-inflammation properties ¹⁴. The drug has also been established to elevate histamine level and partially suppresses increases of tumor necrosis factor (TNF)- α in the serum and TNF- α mRNA expression in the liver ¹⁰. Though this has really increased the use of the drug both in combination with other drugs or as single therapy for malaria, agranulocytosis and severe neutropenia has been a source of worry ¹⁵. The

spleen being a lymphoid organ related to the production of lymphocytes, as well as, the filtration and storage of blood ¹⁶ may be affected. Thus, this study was to ascertain the effect of AQ on the histomorphology of the spleen of Wistar rat.

MATERIALS AND METHODS

After approval by the Ethics Committee of the University of Calabar, Calabar-Nigeria of the research proposal, a total number of thirty-two adult Wistar rats used for the experiment were bred in the animal house of the Department of Anatomy, University of Calabar, Calabar, Nigeria. They were housed in well-ventilated cages and kept in the animal house of the Department of Anatomy. They were fed with Growers Mash obtained from Guinea Feeds Limited, Uyo, Nigeria. The feed was provided in stainless steel troughs to minimize spillage, whereas water was provided in plastic containers fitted with stainless steel nozzles.

When their weight ranged between 150-180g, the experimentation began. The rats were then grouped into A, B, C and D with each cage containing eight rats. The drug, amodiaquine (AQ) was obtained from a reputable pharmacy in Calabar. The drug being in tablet form was dissolved in distilled water. The drug dosage was weight dependent; hence it was interpreted to the physiologic weight of man which is 70kg, with the recommended dose of the average physiologic weight man being 153.1mg per day. The drug administration is shown in Table 1.

Figure 1

Table 1: The drug administration

| Group (n=8) | Treatment/Dosage per day | Duration (days) |
|-------------|--------------------------|-----------------|
| A | Distilled water | 3 |
| B | 17.50mg/kg | 3 |
| C | 8.75 mg/kg | 3 |
| D | 8.75 mg/kg | 6 |

The administration was done once a day in the morning hours. At the end of the experiment, the rats were weighed again and then sacrificed using humane killing with chloroform. The spleen were dissected out and preserved in neutral formal saline, for a period of seven days for subsequent routine tissue processing by haematoxylin and

eosin method.

RESULTS

The control (group A) section of the spleen showed lymphoid aggregation called white pulps. These surrounded blood vessels called the central artery. Surrounding the white pulps were red pulp parenchymal cells, which made up the bulk of the organ, as well as, pulp vessels (Plate 1).

Group B that received 17.50mg/kg of AQ for 3 days showed reduced white pulp size/population, but the red pulp parenchymal cells were hyperplastic and hypertrophied with its vessels being prominent compared to the control (Plate 2).

In group C that received 8.75 mg/kg of AQ for 3 days, there were numerous prominent red pulp parenchyma. There was increased size of the white pulp, as well as, prominent central and pulp arteries compared to the control (Plate 3).

The section of group D animals that received 8.75 mg/kg of AQ for 6 days showed greatly reduced white pulp size, while the red pulp parenchymal cells appeared like the control (Plate 4).

Figure 2

Plate 1: The control section that received distilled water. The red pulp (RP), white pulp (WP) and central artery (CA) are very prominent. Mag. x400 H&E

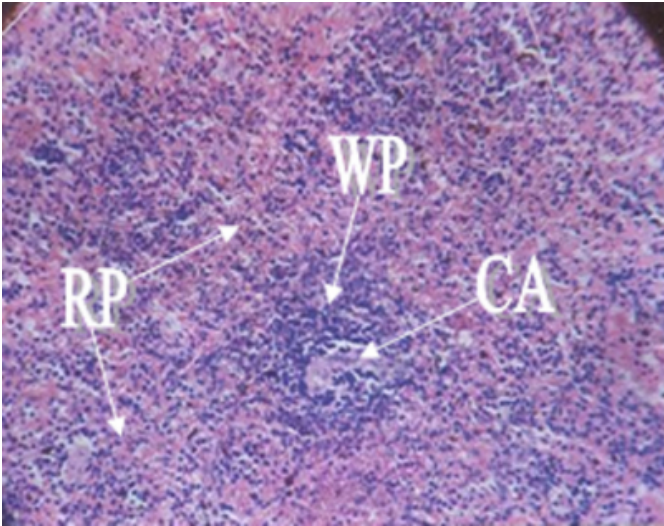


Figure 3

Plate 2: Group B that received 17.50mg/kg of AQ for 3 days. The section revealed decreased white pulp (WP) size, and prominent red pulps (RP) and the pulp vessels (PV). Mag. x400 H&E

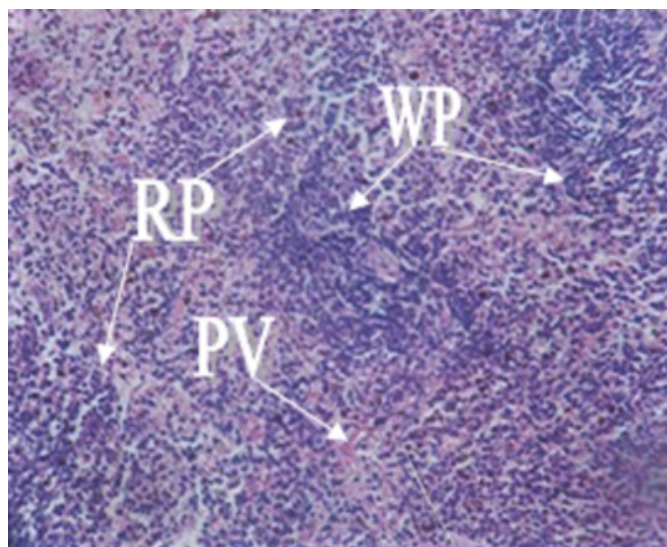


Figure 4

Plate 3: Group C that received 8.75 mg/kg of AQ for 3 days. The section showed prominent red pulps (RP), increased white pulp (WP) size and prominent central artery (CA) and pulp vessels (PV). Mag. 400 H&E

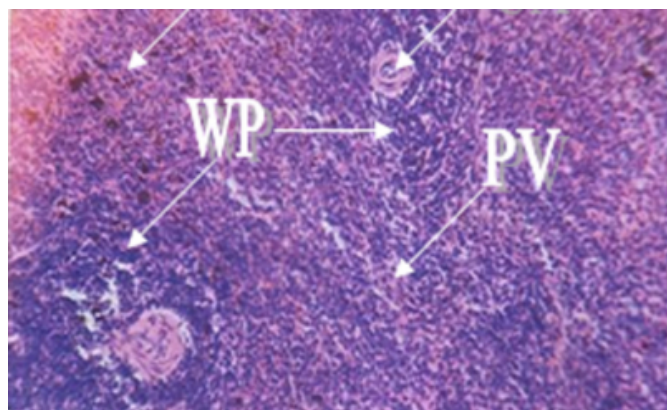
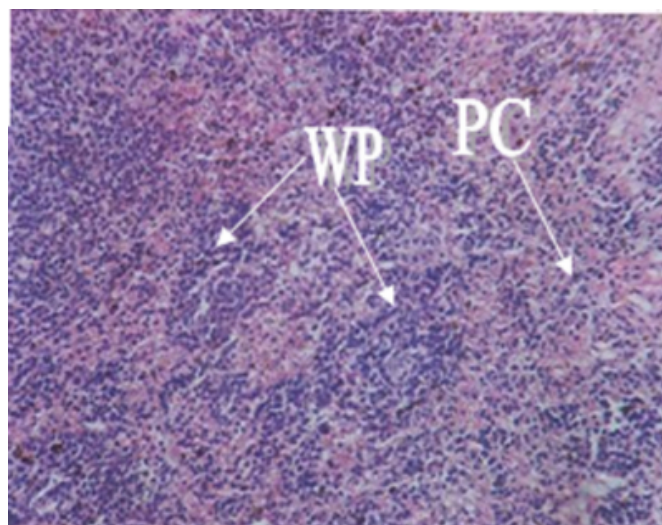


Figure 5

Plate 4: Group D that received 8.75 mg/kg of AQ for 6 days. The section showed reduced white pulp (WP) size with hypertrophied red pulp parenchymal cells (PC). Mag. x400 H&E



DISCUSSION

The spleen is a large organ responsible for the production of immunological responses against blood-borne antigens and the removal of particulate matter, aged or defective blood cells, especially the red blood. The structure of the spleen allows intimate contacts between the general blood and lymphocytes¹⁶. Amodiaquine (AQ) carried in the blood therefore reaches the spleen with its free radicals.

The white pulp of the spleen consists of lymphoid aggregations which when stimulated produce antibodies^{16,17}. The production of antibodies may have resulted in the increased size of the white pulp in the section of group C animals treated with 8.75 /kg of AQ for 3 days. This is in line with the normal physiological response to insults on the body^{16,17}. When once the body system is exposed to adverse reaction from an endogenous substance, there is proliferation of the T-lymphocytes either directly by cytotoxic activity or indirectly by activation of B-lymphocytes or macrophages. The activation of the lymphocytes by AQ may have been a reason^{15, 18} reported that the adverse reactions of AQ were immune mediated.

Groups B and D sections that received 17.50mg/kg and 8.75 mg/kg of AQ for 3 and 6 days respectively revealed decreased white pulp sizes, and hypertrophied red pulp parenchymal cells. The quantities of the drug taken was higher than normal, hence the reduced white pulp sizes as seen in this study may be due to the toxic effect of AQ on

the lymphoid tissue, an indication of lymphocyte destruction. AQ generates free radicals in the forms of AQ quinone imine and semi quinone imine and these have been implicated in lipid peroxidation in the membranes of hepatocyte¹¹. Since the spleen is the site of synthesis of T and B-lymphocytes, this may result in leucopenia¹⁹.

Our report is in line with a previous report²⁰. He reported severe splenic atrophy and/or lymphoid depletion in boars sustained on dietary fumonisin B₁, while there was already a report that subcutaneous injections of synthetic serum thymic factor caused depletion of small lymphocytes in the T-cell-dependent areas of the spleen of mice²¹.

In conclusion, these results suggest that over-dose and chronic doses of AQ is detrimental to the spleen, therefore AQ should not be taken as prophylaxis and a higher dose than normal should not be contemplated.

CORRESPONDENCE TO

MOSES B EKONG, M.Sc Department of Anatomy, Faculty of Basic Medical Sciences, University of Calabar, Calabar-Nigeria mbe_flashpoint@yahoo.com

References

1. Whitty CJM, Rowland M, Sanderson F, Mutabingwa TK. Malaria. *Br Med J* 2002; 325: 1221-1224.
2. Oliaro PL, Bloland PB. Clinical and public health implications of antimalarial drug resistance. In Rosenthal PJ editor *Antimalarial chemotherapy: mechanisms of action, resistance, and new directions in drug discovery*. Totowa, N. J.; Humana Press. 2001; 65-83.
3. Watkins WM, Sixsmith DG, Spencer HC, Boriga DA, Kariuki DM, Kipingor T, Koech DK. Effectiveness of amodiaquine as treatment for chloroquine-resistant *Plasmodium falciparum* infections in Kenya. *Lancet* 1984; 1: 357-359.
4. Hatton CSR, Peto TEA, Bunch C, Pasvol G. Frequency of severe neutropenia associated with amodiaquine prophylaxis against malaria. *Lancet* 1986; 1: 411-413.
5. Larrey D, Castot A, Pessayre D, Merigot P, Machayekhy JP, Feldamn G, Lenoir A, Ruelt B, Benhamov JP. Amodiaquine-induced hepatitis. *Ann Intern Med* 1986; 104: 801-803.
6. Neftel KA, Woodtly W, Schmid M, Frick PG, Fehr J. Amodiaquine induced agranulocytosis and liver damage. *Br Med J* 1986; 292: 721-723.
7. WHO (2001). *Antimalarial Drug Combination Therapy*. Report of a WHO Technical Consultation, World Health Organization. Geneva.
8. Ipca Laboratories Limited. 2004. 48, Kandivi Ind. Estate, Mumba; 400067.
9. Oliaro P, Mussano P. Amodiaquine for treating malaria. *The Cochrane Database of System Reviews*. In the Cochrane Library. Chichester: John Wiley and Sons, Ltd. 2003.
10. Yokoyama A, Moria S, Takahashia HK, Kankea T, Wakea H, Nishibori. M. Effect of amodiaquine, a histamine N-methyltransferase inhibitor, on, *Propionibacterium acnes* and lipopolysaccharide-induced hepatitis in mice. *Eur J Pharmacol* 2007; 558 (1-3): 179-184.
11. Maggs JL, Tingle MD, Kitteringham NR, Park BK. Drug-protein conjugates-XIV. Mechanisms of formation of protein-aryllating intermediates for amodiaquine, a myelotoxin and hepatotoxin in man. *Biochem Pharmacol* 1988; 37(2): 303-311.
12. O'Neill PM, Bray PG, Hawley SR, Ward SA, Park BK. 4-aminoquinolines-past, present, and future; a chemical perspective. *Pharmacol Ther* 1998; 77: 29-58.
13. World Health Organization. *Practical chemotherapy of malaria*. Report of a WHO Scientific Group. Geneva. WHO Technical Report Series, 1990; 805.
14. Tagbor H, Bruce J, Browne E, Randal A, Greenwood B, Chandramohan D. Efficacy, safety, and tolerability of amodiaquine plus sulphadoxine-pyrimethamine used alone or in combination for malaria treatment in pregnancy: a randomized trial. *Lancet*. 2006; 14; 368(9544): 1349-1356.
15. Christie G, Breckenridge AM, Park BK. Drug-protein conjugates-XVIII: detection of antibodies its quinone imine metabolite in man and rat. *Biochem Pharmacol* 1989; 38(9): 1451-1458.
16. Young B, Heath JW. Immune system. In Young B, Heath JW, editors. *Wheater's Functional Histology: a text and colour atlas*. Hong Kong: Churchill Livingstone. 2004. 193-221pp.
17. Guyton MD, Hall JE. *Textbook of Medical Physiology*. London. S. W. Saunders Company. 2000
18. Clarke JB, Maggs JL, Kitteringham NR, Park BK. Immunogenicity of amodiaquine in the rat. *Int Arch Allergy Appl Immunol* 1990; 91(4): 335-342.
19. McPherson RA, Pincus MR. *Henry's Clinical Diagnosis and Management by Laboratory methods*. Philadelphia, Pa: WB Saunders. 2007; 461-462pp.
20. Gbore FA. Effect of dietary fumonisin B₁ on histomorphology and histopathology of organs of pubertal boars. *Am-Eur J Sc Res* 2007; 2(2): 75-77.
21. Mendlowski B, Field AK. Histomorphologic assessment of serum thymic factor treatment of NZB/NZW mice. *Clin Immunol Immunopathol* 1980; 15(2): 144-161

Author Information

Moses B. Ekong, M.Sc.

Department of Anatomy, Faculty of Basic Medical Sciences, University of Calabar

Anozeng O. Igiri, M.Sc.

Department of Anatomy, Faculty of Basic Medical Sciences, University of Calabar

Otu E. Mesembe, M.Sc.

Department of Anatomy, Faculty of Basic Medical Sciences, University of Calabar

Queen I. Ojohu, B.Sc.

Department of Anatomy, Faculty of Basic Medical Sciences, University of Calabar