

The Use of Interscalene Block Prior to Shoulder Arthroscopy: Implications for Postoperative Pain Management

P Phillips, H Cagle, H Herrera

Citation

P Phillips, H Cagle, H Herrera. *The Use of Interscalene Block Prior to Shoulder Arthroscopy: Implications for Postoperative Pain Management*. The Internet Journal of Anesthesiology. 1996 Volume 1 Number 1.

Abstract

OVERVIEW OF BRACHIAL PLEXUS BLOCKS

The development of the brachial plexus block began in 1884 when Halsted performed the first brachial plexus by injecting exposed roots of the brachial plexus with cocaine ¹. It was not until 1911 that Hirschel and Kulenkampff reported a percutaneous brachial plexus block. The axillary technique was developed first, followed by a supraclavicular approach ^{2,3}. In 1919, Mully developed the interscalene approach to brachial plexus block in order to avoid pneumothorax ⁴. The modern interscalene approach was developed by Winnie using the level of the sixth cervical transverse process as the reference point for needle insertion

⁵.

The interscalene brachial plexus block is ideal for the proximal upper extremity but less reliable for neural blockade of the wrist and hand. Most patients have readily identifiable landmarks, allowing easy access to the brachial plexus via the interscalene approach. The use of a nerve stimulator to guide proper needle placement rather than relying solely on paresthesias, can increase the rate of a safe and successful block.

In an effort to initiate early postoperative physical therapy, our Acute Pain Management Service was asked to provide brachial plexus blocks for all patients having shoulder surgery at a newly opened orthopedic specialty hospital. The block was performed prior to surgery. While our pain management service had been in existence for four years providing epidural analgesia and IV PCA at a large teaching hospital, we had almost no experience with brachial plexus blocks for postoperative pain. Therefore, a Continuous Quality Improvement (C.Q.I.) monitor was initiated to determine the efficacy, effectiveness and efficiency of this

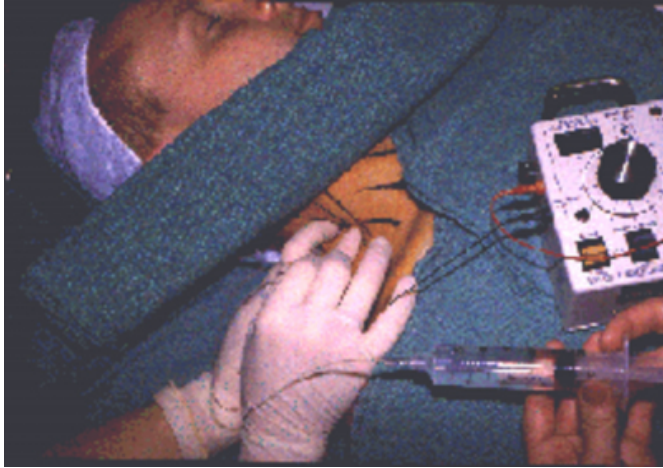
new procedure on our patient population. Indicators were established to capture possible complications (see CQI monitor). In addition, a follow-up patient satisfaction survey was done.

METHOD

After obtaining informed consent, the patient was placed in the supine position and EKG, blood pressure and oxygen saturation monitoring were initiated. Oxygen via face mask was applied and intravenous sedation with midazolam was administered. The nerve stimulator used for guidance was grounded to the patient. The patient's head was turned at approximately a 45 degree angle away from the operative side. The neck was then prepped and draped in a sterile fashion. A twenty-two gauge insulated needle designed with two ports was used connecting to a nerve stimulator and extension tubing. The needle was connected to the nerve stimulator and the remaining port was connected to a syringe filled with 0.375% bupivacaine with epinephrine. In addition to the anesthesiologist, this technique requires an assistant to manipulate the nerve stimulator and inject the local anesthetic. The interscalene groove was then identified and the needle was inserted at the site of the groove level to the cricoid cartilage. Once the needle pierced the skin, the nerve stimulator was turned on and set to a low voltage, one second interval stimulation and an output of approximately 1.3 mA. The needle was inserted perpendicular to the skin and then angled slightly caudad. The needle was then advanced slowly, and stimulation of the extremity, diaphragm, sternomastoid and trapezius was observed. The brachial plexus lies between the course taken by the phrenic nerve anteriorly and the cervical plexus posteriorly. If diaphragmatic stimulation (phrenic nerve) occurred, then the needle direction was considered to be too anterior and was

redirected. If muscles of the neck or trapezius (cervical plexus) were stimulated, then the needle was considered too posterior and was redirected.

Figure 1



Only biceps stimulation, or stimulation of a muscle group located distal to the biceps was accepted prior to injection of the local anesthetic. Deltoid contraction can be confused with neck or trapezius muscle stimulation. If the needle is not located within the sheath containing the brachial plexus, muscle contraction will cease at approximately 0.9 mA. The local anesthetic was only injected when muscle contraction was achieved with less than 0.5 mA of stimulator output. Therefore, biceps contraction was used as a marker for proper needle placement. When stimulation of the extremity was observed, the nerve stimulator output was gradually reduced. The local anesthetic dose was injected following appropriate muscle stimulation with the proper mA. After negative aspiration, a 2 cc test dose was given followed by 30 - 40 cc, depending on the size of the patient. The syringe was intermittently aspirated throughout the injection of the local anesthetic. The needle was then withdrawn and the patient was taken to the operating room.

CONTINUOUS QUALITY IMPROVEMENT PROGRAM/SAFETY ISSUES

The C.Q.I. monitor was completed whenever a patient developed one of the following complications:

1. seizure,
2. respiratory insufficiency,
3. total spinal block,
4. pneumothorax,

5. infection,
6. nerve injury,
7. hematoma, and
8. inadequate pain relief.

Data was collected on 100 % of the patients undergoing interscalene block (N = 352).

During the initial evaluation period of the first 149 patients, there was one reported seizure (0.7%). Despite negative aspiration for blood, the patient experienced seizure-like activity, apnea and bradycardia. She was treated with Propofol and bag-mask ventilation for approximately 5 minutes at which time she awakened and was determined to be neurologically intact. Surgery proceeded as planned and the patient awakened in the PACU in severe pain. The interscalene block was successfully repeated and the patient was discharged the following day.

There were also two incidents of respiratory insufficiency (1.3%) during this period. The first case involved the patient becoming short of breath in the PACU, presumably from the phrenic nerve block. A chest radiograph showed unilateral diaphragmatic paralysis. The patient was treated with oxygen and placed in a sitting position. The symptoms resolved in two and one half hours and the patient was discharged.

The second patient was unable to be extubated for one hour due to, presumably, phrenic nerve block. After extubation, her chest radiograph revealed a unilateral diaphragmatic paralysis. Daily chest x-ray showed persistent paralysis for three days. This resolved by the fourth day and she was discharged to home.

One common denominator in all three of these cases was the patients weight. Landmarks tend to be more difficult to locate in the obese patient. Additionally, it may become more difficult for an obese patient to breath with a partial paralysis of the diaphragm than it would be for a weight/height proportionate person.

TOTAL INCIDENCE OF COMPLICATION IN 352 PATIENTS

- Seizure - 0.3 %
- Respiratory Insufficiency - 0.6 %

- Total Spinal Block - 0.0 %
- Pneumothorax - 0.0 %
- Infection - 0.0 %
- Nerve Injury - 0.0 %
- Hematoma - 0.0 %
- Inadequate Pain Relief - 0.0 %

CLINICAL IMPLICATIONS

The use of interscalene block has brought about important clinical implications regarding patient safety, patient satisfaction, patient education, analgesic requirements, and recovery time. Based on the CQI data of complications/risks interscalene block was found to be a safe procedure for this patient population. A patient satisfaction questionnaire was developed and used for follow-up evaluation and showed that patients did not experience undue discomfort during the placement of an interscalene block. Additionally, patients reported a delayed frequency to the first dose of analgesic medication following discharge, which ranged from 4-12 hours. The patients have minimal pain upon awakening, and therefore have a delayed need for postoperative analgesics following interscalene block. The surgeons had the impression that their patients are more likely to have a positive psycho-emotional response to their experience and begin the process of coping with their recovery and rehabilitation more effectively because of the comfortable postoperative period provided by interscalene block.

The implementation of interscalene block has also lead to the development of a patient information brochure. The brochure includes:

- the purpose of brachial plexus nerve block,
- an explanation of the procedure,
- patient eligibility,
- instructions on using a visual analog scale to rate pain,
- discussion of potential side effects/complications of the procedure,
- cost information, and
- a picture of the brachial plexus nerves.

The brochure is provided to the patient preoperatively at the surgeons office.

FUTURE CLINICAL IMPLICATIONS: THE PROGRESSION TO CONTINUOUS INFUSION

Interscalene blocks for shoulder surgery have been so successful in this institution, that we have begun implementing a program to provide continuous brachial plexus analgesia via a brachial plexus catheter. Our program is still in its infancy, but already shows great promise. Currently, we are using an eighteen gauge, two inch catheter placed with the aid of a nerve stimulator. The angle of insertion is approximately 120 degrees and the needle is inserted at a site slightly higher than the level of the cricoid cartilage. The catheter is then sutured into place and a 2 X 2 clear dressing is applied.

After the catheter is placed, the patient is given a general anesthetic. The infusion of Bupivacaine 0.125% at 5-8 cc/hr is begun immediately postoperatively. The infusion is continued for the duration of the hospital stay, usually 1 - 2 days. Initial success rates are running approximately 50%. The failures are attributed strictly to catheter problems as they tend to become dislodged fairly easily. The patients whose infusions have been successful, however, do extremely well, even with total joint replacement. This program continues to evolve and will, likely, be a permanent part of our Acute Pain Management Service.

References

1. Crile GW: Anesthesia of nerve roots with cocaine Cleve Med J, 1897; 2: 355.
2. Hirschel G: Die Anaesthesierung des Plexus Brachialis fuer die Operationen der oberen Extremitaet Muenchen Med Wochenschr, 1911; 58: 1555.
3. Kulenkampff D: Die Anaesthesierung des Plexus Brachialis. Zentralbl Chir, 1911; 38: 1337.
4. Barash P: Clinical Anesthesia. Philadelphia Lippincott, 1989: page 13.
5. Winnie A: Plexus Anesthesia; Vol 1: Perivascular techniques of brachial plexus blocks. Philadelphia, WB Saunders Co, 1984.

Author Information

Peggy Phillips, R.N., BSN, CPAN

Heather Cagle, MSN, R.N., CCRN

Hector Herrera, M.D.