

Closed reduction and internal fixation of fractures of the shaft of the femur by the Titanium Elastic Nailing System in children.

S Navdeep, P Kanav, V Suhail, D Harish

Citation

S Navdeep, P Kanav, V Suhail, D Harish. *Closed reduction and internal fixation of fractures of the shaft of the femur by the Titanium Elastic Nailing System in children..* The Internet Journal of Orthopedic Surgery. 2009 Volume 17 Number 1.

Abstract

Femoral shaft fractures account for 1.6% of all bony injuries in children, usually caused by assault or fall during normal play. Common methods of treatment include, traction followed by hip spika, dynamic compression plate, external fixator, and IM nailing. Though the fracture union is rapid in children chances of mal union still exists. Taking this into view, we did this study. Materials and methods-A series of 25 patients with femoral shaft fracture with ages between 6 to 14 years were treated from May 2007 to August 2008 is reviewed. Patients were treated with TENS. Male to female ratio was 2.6:1. mode of injury was RTA in 80%. open fractures were excluded from the study. 60% were transverse, 24% short oblique, 16% had short spiral. Flynn et al, criteria was used while evaluating final result. Results-Average hospital stay was 9 days post operative. Average duration of callus formation was 3.5 weeks. Average duration of fracture union was 8.5 weeks. Two cases had over growth of 5 and 4mm respectively. One had shortening of 2cm. Conclusion-TENS is a safe and satisfactory mode of treatment and is relatively easy to perform. It avoids the chances of pin tract infections and long scars. Long term immobilization leading to fracture disease or spika immobilization is avoided.

INTRODUCTION

Femoral shaft fractures account for 1.6% of all bony injuries in children. Male female ratio being 2.6:1. These fractures have bimodal age distribution with peak at 2 and 17 years. Fractures are mostly caused by fall during play (30%) or abuse. Low velocity trauma leads to transverse fractures and high speed causes comminuted or segmental fractures⁽¹⁾.

In recent past Traction and or Hip spika was the standard treatment of all femoral fractures⁽²⁾, which involved long duration of treatment. More recently variety of therapeutic alternatives such as flexible intramedullary nails like Enders nail and TENS have become available to decrease morbidity, increase convenience and decrease cost of care.

Fractures are classified as-

1. Transverse, spiral or oblique
2. Comminuted
3. Open or close
4. Fractures of proximal, middle or distal third.

In proximal shaft and subtrochanteric fractures, the proximal fragment usually is in a position of flexion, abduction, and external rotation because of the unopposed pull of the iliopsoas, abductor, and short external rotator muscles. The adductors and extensors are intact in midshaft fractures, and the distal fragment usually is in satisfactory alignment except for some external rotation. In supracondylar fractures, the distal fragment is in a position of hyperextension because of the over pull of the gastrocnemius. The muscle imbalances are important when aligning the distal fragment to the proximal fragment in traction or a spica cast⁽³⁾.

The most common femoral fractures in children (50%) is a closed transverse in middle third of femoral shaft. At this site anterolateral bowing is maximum and is subjected to maximum trauma⁽⁴⁾.

The commonly used methods of treatment are-

- Traction followed by hip spika
- Intramedullary nailing
- Dynamic compression plating

- External fixator.

Traction followed by hip spika has been a standard treatment for most of pediatric femoral shaft fractures. Appropriate traction is maintained for some time till fracture becomes sticky. This is followed by hip spika till fracture unites. Most of the femoral shaft fractures heal without significant complications with conservative treatment in this age group (5-10).

Some authors have recommended external fixator as primary treatment of femoral shaft fractures particularly in 6 to 12 years of age. It has been used in patients with multiple trauma, vascular compromise, and open fractures (11-13). However their use in closed injuries is not palatable to all.

One effective alternative is use of flexible intramedullary nails such as Ender's and Titanium Elastic Nails. In these procedures complete healing with return to pre injury level occurs early. Decreased hospitalization, low cost of implants, less potential damage to growth centers, decreased blood loss and operative time suggest that TENS has a merit over procedures. The biomechanical principal of TENS is based on the symmetrical bracing action of two elastic nails inserted into the metaphysis, each of which bears against the inner bone at three points.

Hence we took up this study to

To study the result of operative treatment in fracture shaft of femur by TENS

To study the complications of above said method.

The results were evaluated Flynn et al scoring criteria (14).

SUBJECTS AND METHODS

Study was conducted in PG Deptt. Of Orthopaedics GMC , Jammu during period of May 2007 to Aug 2008.

INCLUSION CRITERIA

25 patients of fractures SOF both male and female in age group of six to fourteen years were included.

EXCLUSION CRITERIA

1. Unstable fractures (long oblique /spiral) and multifragmentary.
2. Compound fractures.

Patients were admitted and examined. Any life threatening injury was ruled out. Necessary first aid, IV fluids, analgesics, adequate splintage was given. Radiographs of local parts, all routine investigations for anesthesia were done.

IMPLANT AND SURGICAL TECHNIQUE

There are two standard techniques viz. ascending and descending depending on location of fractures. TENS is available in five diameters: two mm, two and a half mm, three mm, three and a half mm, four mm, and are 440 mm in length. Nails are coloured coded for easy identification and rounded tip ensures smooth and easy insertion. Proper nail diameter is no more than 40% of the width of the canal. The following sizes are used acc. To age

1. six – eight year old –three mm nail.
2. nine to eleven year old—three and a half mm
3. 12-14 year old—four mm nail.

The patient is positioned on fracture table, closed reduction achieved with image intensifier. Prepare and drape the part. Contour both nails into bow shaped with nail tip pointing to the concave side of nail, apex of bow should be at level of fracture. Entry point is 3cms above the distal femoral physis on lateral and medial side. Select largest drill bit relative to the diameter of the nail. Use double drill sleeve to protect the tissues. Align the nail tip so that convex side glances the far cortex. Attach inserter with universal chuck with the nail. Using controlled blows hammer the nail. Use small f tool to reduce the fracture. Insert second nail in similar way. Two nail are divergent. Cut nail 10-20 mm outside bone for easy retraction. Close skin over drains. Third gen. cephalosporins are given post op. Full knee immobilizer was given for comfort. The patient was discharged around the 10th day. The nail was removed around 9-12 months after operation.

RESULTS

Most cases were in nine to twelve age group. RTA was the most common mode of trauma. Most fractures were in the middle third. Average hospital stay was 9 days post operative. Average duration of callus formation was 3.5 weeks. Average duration of fracture union was 8.5 weeks. Two cases had over growth of 5 and 4mm respectively. One had shortening of 2cm. None had refracture during one year of follow up. No case had infection, varus or valgus malformation. None had physeal injury, migration of nail or

rotational deformity. Results. Evaluated using Flynn et al scoring criteria ⁽¹⁴⁾.

Figure 1

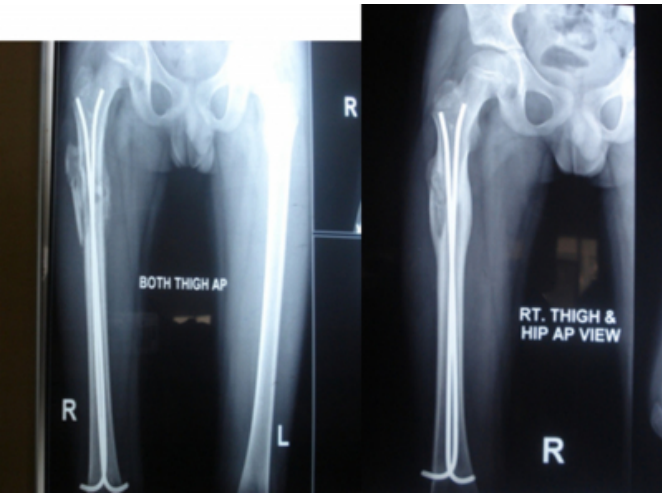
	excellent	good	poor
Limb length discrepancy	<1 cm	<2 cm	>2 cm
Angulations' in degrees	<5	5-10	>10
pain	absent	absent	present
complications	absent	mild	Major/extended period for resolvable morbidity.

Figure 2

Results.	No. of cases
Excellent.	24(96%)
Good.	1(4%)
Poor.	0.

Figure 3

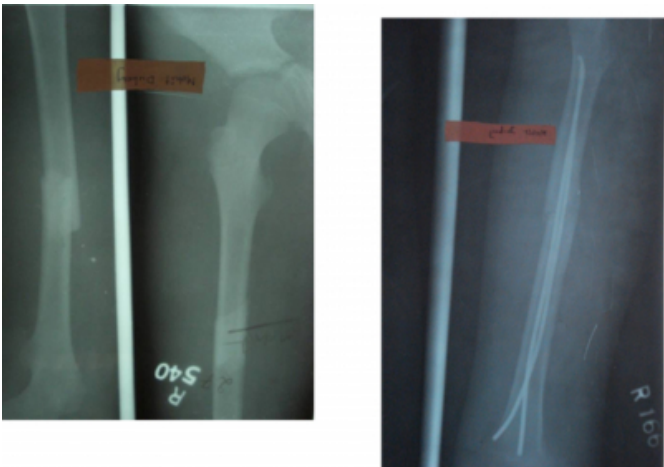Fig 1- showing immediate post operative and follow up x-rays after 6 weeks.



Note the abundant callus formation.

Figure 4

Figure 2- pre operative and immediate post operative x-rays.



Note three point fixation of TENS nail.

DISCUSSION

The ideal treatment of femoral shaft of fractures in children is defined as one that controls the length and alignment, does not compress or elevate the extremity excessively, and is comfortable for child and convenient for family and cause the least physiological impact possible ⁽¹⁵⁾. Hip spika cast application produces a satisfactory result in patients younger than 6 yrs of age. Historically children over 6 years of age have been treated with non operative methods, but the children of this age group cannot tolerate the prolonged immobilization of traction for different reasons. By internal fixation, the management of multi-trauma has become easier. This procedure satisfies many patients who insisted upon a perfect fracture alignment at initial treatment and will not accept any overriding of the bones even when reassured ⁽¹⁶⁾.

Earlier the operative treatment was mostly used for polytrauma patients, head injury patients and in patients where there was difficulty in maintaining reduction. Recently indications of operative treatment have been expanded to include simple isolated femoral fractures. The closed TENS nailing appears to be an ideal technique. Stabilization with technique is safe without danger to growth plate and device is easily inserted and removed. The slight motion permitted with this allows abundant callus formation not seen with rigid fixation. It has been shown that external callus provides the most rapid restoration of continuity and strength of fractured diaphysis ⁽¹⁷⁾.

CONCLUSION

TENS is a safe and satisfactory mode of treatment and is relatively easy to perform. It avoids the chances of pin tract

infections and long scars. Long term immobilization leading to fracture disease or spika immobilization is avoided.

References

Author Information

Singh Navdeep, MS Orthopaedics

Post graduate Department Of Orthopaedics, Government Medical College Jammu, Jamp;K. INDIA.

Padha Kanav, PG Student

Post graduate Department Of Orthopaedics, Government Medical College Jammu, Jamp;K. INDIA.

Vakil Suhail, PG Student

Post graduate Department Of Orthopaedics, Government Medical College Jammu, Jamp;K. INDIA.

Dang Harish, MS (PGI)

Associate Professor Orthopaedics, Post graduate Department Of Orthopaedics, Government Medical College Jammu, Jamp;K. INDIA.