

# Thrombotic Thrombocytopenic Purpura-Hemolytic Uremic Syndrome In Pregnancy: A Successful Outcome

G Pratish, P Basant, S Blessy, M Kavita

## Citation

G Pratish, P Basant, S Blessy, M Kavita. *Thrombotic Thrombocytopenic Purpura-Hemolytic Uremic Syndrome In Pregnancy: A Successful Outcome*. The Internet Journal of Gynecology and Obstetrics. 2007 Volume 9 Number 1.

## Abstract

Thrombotic Thrombocytopenic Purpura- Hemolytic Uremic Syndrome (TTP- HUS) occurs rarely in pregnancy. It is a diagnostic dilemma to the treating obstetrician with a clinical spectrum that often cannot be differentiated from pre eclampsia and HELLP syndrome. It has an unfavorable maternal and fetal outcome if it is unrecognized or sub optimally managed early during disease presentation. A successful outcome and management of TTP-HUS in pregnancy is discussed.

## INTRODUCTION

Thrombocytopenia complicates up to 10% of all pregnancies. [1] It occurs in gestational thrombocytopenia, idiopathic thrombocytopenic purpura, pre eclampsia, malignant hypertension, HELLP (Hemolysis, Low Platelets, Elevated Liver Enzymes) syndrome, sepsis with disseminated intravascular coagulation and Thrombotic Thrombocytopenic Purpura (TTP) - Hemolytic Uremic Syndrome (HUS). Often this poses an immense diagnostic and management dilemma to the treating obstetrician. The overlap of clinical and laboratory parameters with some of the fore mentioned conditions makes an early diagnosis of TTP-HUS difficult, which is imperative owing to the high morbidity and mortality associated with delayed initiation of treatment.

## CASE REPORT

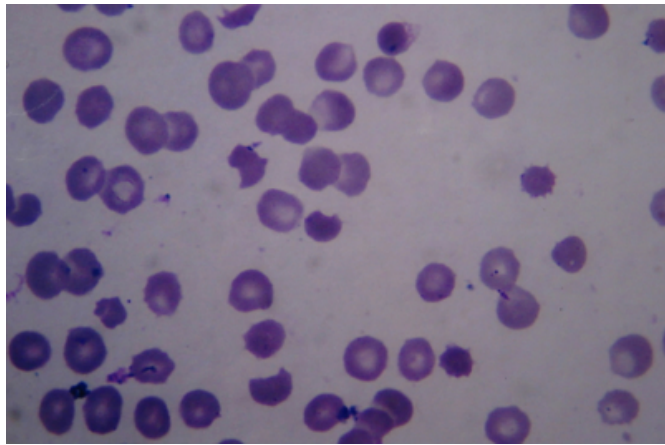
A 20 year old lady primi gravida at 37 weeks gestation presented with three days of jaundice, high colored urine and clay colored stools. A week earlier she had been prescribed azithromycin for a respiratory tract infection. No history of indigenous medication intake, oral contraceptive use prior to pregnancy or blood transfusion was present. Headache and blurring of vision with blood pressure of 140/90 mm Hg was recorded a day prior to referral. The antenatal period was otherwise uneventful. On examination she was drowsy, had mild pallor, icterus and pedal edema. Systemic examination was normal. The uterus was palpated as for a full term pregnancy with normal fetal heart auscultation. Examination of the optic fundi was normal.

Investigations were suggestive of microangiopathic hemolytic anemia as evidenced by hemoglobin 8.1gm/dL, schistocytes in peripheral blood smear (Figure 1), reticulocytosis [2.5%], raised lactate dehydrogenase (LDH) [786 IU/L] and thrombocytopenia [platelet count 96000/ cu mm.] Coagulopathy and hyperbilirubinemia with normal liver enzymes was observed. Acute renal failure (serum creatinine 1.6 mg/dL) was present at admission. Abdominal ultrasonography showed minimal ascites and normal kidneys. After admission she developed fetal distress and Lower Segment Caesarean Section (LSCS) was done immediately. A healthy male child was delivered with no complications. Post LSCS the renal function deteriorated with serum creatinine rising to 2.1mg% over the next 24 hours. The hemoglobin and platelets dropped to 5.2 gm/dL and 39000/mm<sup>3</sup> respectively. An infectious disease screen was negative. Thrombotic Thrombocytopenic Purpura (TTP)-Hemolytic Uremic Syndrome (HUS) was diagnosed and plasma exchange done immediately with 40ml/kg plasma exchanges. Ten once daily sessions of plasma exchange were done. She also underwent intermittent hemodialysis because of oliguria and fluid overload for a week post LSCS. Methyl prednisolone [500mg/day for five days] was initiated after the third plasma exchange, as she continued to have persistent thrombocytopenia and hemolysis. On the second day post LSCS a swelling was noticed in the hypogastric region with a drop of hemoglobin level and an emergency laparotomy was done to evacuate a rectus sheath hematoma. The inferior epigastric artery was ligated. Renal functions and urine output normalized after a week of in hospital stay. The hemoglobin stabilized after the

seventh plasma exchange and platelet count, reticulocyte count and serum LDH showed an improving trend after the ninth plasma exchange. It was discontinued after normalization of platelet count for two consecutive days thereafter. She was discharged in an excellent condition. However, she did not follow up in the out patients.

### Figure 1

Figure 1: Peripheral blood film of the patient post partum shows fragmented red blood cells (schistocytes) and thrombocytopenia.



## DISCUSSION

Thrombotic microangiopathy is defined by vessel wall thickening and intra luminal platelet thrombosis with partial or complete obstruction of the vessel lumen. Two pathologically indistinguishable but somehow clinically different entities have been described, depending on predominantly renal or neurological lesions, as HUS and TTP respectively. [2] TTP was earlier diagnosed by a clinical pentad constituted by fever, neurological symptoms, renal failure, hemolytic anemia and thrombocytopenia. Considerable advances in understanding the pathogenesis and effective early life saving management, with plasma exchange, has led to revision of this definition to the current dyad of thrombocytopenia with microangiopathic hemolytic anemia (without another apparent cause.) This is adequate reason to diagnose and treat TTP- HUS. [3] TTP- HUS is now used to describe this condition owing to an inability to distinguish TTP and HUS on clinical or pathological grounds. [4] It is a rare disease with an estimated incidence of 2-11/million population. [5] and 10% of TTP cases have been reported to occur in pregnancy. [1] The greatest risk for TTP-HUS appears to be at term or in the immediate post partum period. [6] Pregnancy is identified as a possible trigger for TTP- HUS, with a higher frequency in women

having suffered from the disease pre pregnancy. Pre eclampsia and related syndromes, hypercoagulable state and progressively decreasing concentration of ADAMTS13 in late pregnancy increase the risk of TTP- HUS.

Diagnosing TTP- HUS in pregnancy is often a clinical dilemma due to a similar spectrum of presentation in pre eclampsia, eclampsia and HELLP syndrome. This may often delay recognition and treatment of TTP- HUS. An important distinguishing feature may be an improvement in these conditions post delivery. [5] Improvement after delivery rules out TTP- HUS.

To a large extent management of TTP- HUS continues to be empirical and guided by clinical experience. At present there is no absolute consensus on management, but survival rates in TTP- HUS have improved with early management from 10% to between 75 and 92%. This emphasizes the need for early diagnosis and urgent initiation of treatment measures. [6] Clinical suspicion of TTP- HUS necessitates urgent plasma exchange. [5] Plasma infusion may be appropriate till plasma exchange is available. [9] The British Committee for Standards in Hematology guidelines recommend continuation of plasma-exchange therapy for a minimum of two days after the platelet count returns to normal ( $>150,000/\text{cu. mm}$ ), normal neurological status, rising hemoglobin and normal LDH. It also recommends the use of glucocorticoids for all patients with TTP.

Ten percent of mortality (15/155) with TTP- HUS in the Oklahoma Registry during the period 1989-1997 was associated with pregnancy emphasizing the need for early recognition and appropriate consultation and referral.

Anxious women may be reassured as no association of TTP- HUS in subsequent pregnancies in women presenting with TTP- HUS in an earlier pregnancy can be made. [10]

## ACKNOWLEDGEMENT

Dr Naveen Kakkar, MD(Pathology), Reader, Christian Medical College, Ludhiana for the peripheral blood film review.

## CORRESPONDENCE TO

Dr. Pratish George, MD Department of Internal Medicine  
Christian Medical College & Hospital, Brown Road  
Ludhiana- 141 008, Punjab, India Phone-+9198880-11147  
Fax no- (0161) 2609958 E mail: pratishgeorge@gmail.com

## References

1. K. McCrae. Thrombocytopenia in pregnancy: differential diagnosis, pathogenesis, and management. *Blood Reviews* 2003; 17(1): 7-14
2. Ruggenenti P, Noris M, Remuzzi G. Thrombotic microangiopathy, hemolytic uremic syndrome, and thrombotic thrombocytopenic purpura. *Kidney Int* 2001; 60: 831-46
3. George JN. Evaluation and Management of Patients With Thrombotic Thrombocytopenic Purpura. *J Intensive Care Med* 2007; 22: 82-91
4. George JN, Vesely SK. Thrombotic thrombocytopenic purpura - hemolytic uremic syndrome: Diagnosis and treatment. *Cleveland Clin J Med* 2001; 68(10): 857-78
5. Terrell DR, Williams LA, Vesely SK, Lammle B LA, Hovinga JAK, George JN. The incidence of thrombotic thrombocytopenic purpura-hemolytic uremic syndrome: all patients, idiopathic patients, and patients with severe ADAMTS-13 deficiency. *J of Thromb and Haemost* 2005; 3:1432-6
6. George JN. The association of pregnancy with thrombotic thrombocytopenic purpura-hemolytic uremic syndrome. *Curr Opin Hematol* 2003; 10: 339-44
7. George JN. How I treat patients with thrombotic thrombocytopenic purpura- hemolytic uremic syndrome. *Blood* 2000; 96(4):1223-9
8. McMinn JR, George JN. Evaluation of women with clinically suspected thrombotic thrombocytopenic purpura-hemolytic uremic syndrome during pregnancy. *J Clin Apher* 2001; 16: 202-9
9. Vesely SK, George JN: Response: Thrombotic thrombocytopenic purpura-hemolytic uremic syndrome (TTP-HUS): treatment, mortality, and the frequency of HIV infection. *Blood* 2003; 102(10): 3848-9
10. Vesely SK, Li X, McMinn JR, Terrell DR, George JN. Pregnancy outcomes after recovery from thrombotic thrombocytopenic purpura-hemolytic uremic syndrome. *Transfusion* 2004; 44:1149-58

**Author Information**

**George Pratish, MD**

Lecturer, Department of Internal Medicine, Christian Medical College and Hospital

**Pawar Basant, MD, DM, DNB (Nephrology)**

Professor, Department of Nephrology, Christian Medical College and Hospital

**Sehgal Blessy, MBBS**

Resident, Department of Internal Medicine, Christian Medical College and Hospital

**Mandrelle Kavita, DGO, MD**

Reader, Department of Obstetrics, Christian Medical College and Hospital