

# Pulmonary Capillaritis In A Classical Polyarteritis Nodosa

A Taj, S Kanjwal, R Assaly, J Hammersley

## Citation

A Taj, S Kanjwal, R Assaly, J Hammersley. *Pulmonary Capillaritis In A Classical Polyarteritis Nodosa*. The Internet Journal of Pulmonary Medicine. 2008 Volume 11 Number 2.

## Abstract

**Introduction:** Pulmonary involvement in classical polyarteritis nodosa is very uncommon. A 65 year old woman with well documented, classical polyarteritis nodosa was found to have pulmonary capillaritis presenting as alveolar hemorrhage. Patient responded well to the treatment for alveolar hemorrhage. **Methods:** We report a case of polyarteritis nodosa with diffuse alveolar hemorrhage due to pulmonary capillaritis. **Discussion:** We describe a case of Polyarteritis nodosa who presented with pulmonary hemorrhage due to pulmonary capillaritis and hence might represent an overlap of polyarteritis nodosa with Microscopic Polyangiitis (MPA) or other unclassified collagen vascular disease. **Conclusion:** We conclude that pulmonary capillaritis can coexist with "classical" polyarteritis nodosa.

## INTRODUCTION

Pulmonary involvement in classical polyarteritis nodosa (PAN) is uncommon (1, 2). Cases with pulmonary involvement have been seen mostly in patients with microscopic polyangiitis or Churg-Strauss syndrome. Pulmonary involvement though rare in PAN is more frequent in patients with Hepatitis B related PAN, and endothelial cell damage by immune complexes is thought to play a role (3,4). Pulmonary manifestations include alveolar hemorrhage or diffuse alveolar damage which could be fatal.

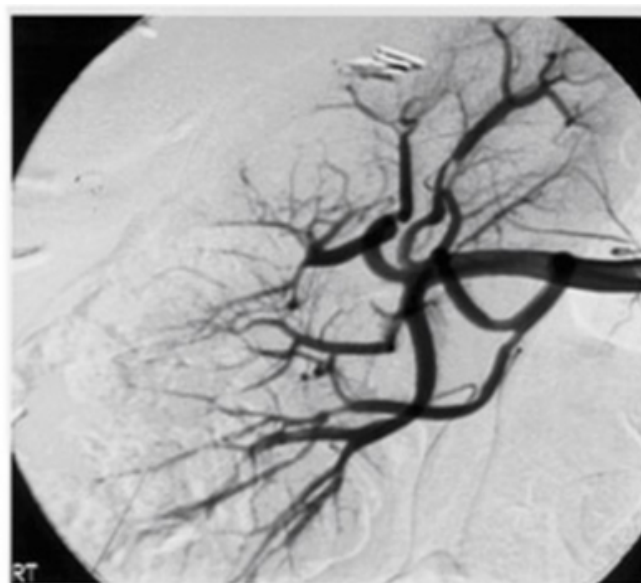
Pulmonary capillaritis has been described in microscopic polyangiitis, but till date there has been no report of pulmonary capillaritis in classical PAN (5).

We report a case of classical PAN presenting with alveolar hemorrhage due to pulmonary capillaritis.

## CASE REPORT

Sixty five year old Caucasian female presented to the University of Toledo Medical centre (UTMC) with acute respiratory failure, patchy pulmonary infiltrates, and abnormal renal function. The patient had been evaluated two months prior for severe hypertension with a renal angiogram, as her blood pressure was refractory to medication and the angiogram revealed right renal artery micro-aneurysms consistent with findings seen in polyarteritis nodosa.

Figure 1



On presentation to the emergency room at UTMC, she was in severe respiratory distress. She had a respiratory rate of 30/minute, with use of accessory muscles, BP 190/105, pulse 110 regular, Temp 37.9°C. Skin exam revealed no rashes or other abnormalities suggestive of collagen vascular

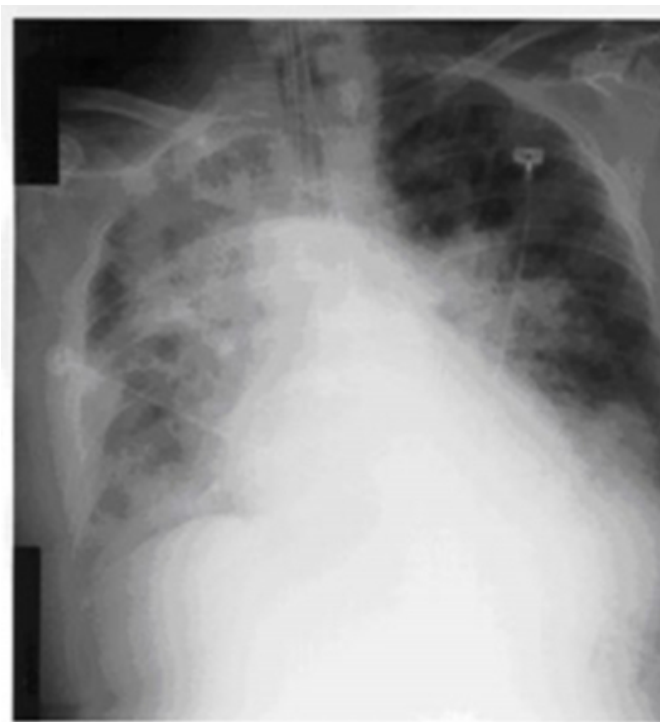disease. Head, ears, eyes, nose and throat - no clinical evidence of sinusitis, septal perforation, or ear abnormalities. No lymphadenopathy. Respiratory examination revealed vesicular breath sounds with mid-inspiratory crackles and wheezing.

Cardiovascular examination revealed regular  $S_1$ - $S_2$ , no  $S_3$ , no murmur. Abdomen was soft without any organomegaly. Extremity examination showed no edema. Neurological exam was normal. Initial laboratory evaluation was as follows:

WBC 16.8 with 70% Neutrophils. Hemoglobin 10.3g/dl. Hematocrit 31.2. Platelets 341000/mm<sup>3</sup>. Arterial blood gases on 50% FiO<sub>2</sub> shows pH of 7.47, PCO<sub>2</sub> 31, PaO<sub>2</sub> 52 mm Hg. Urinalysis - Microscopic hematuria with the presence of hyaline and red blood cell casts consistent with glomerulonephritis, blood urea nitrogen 42 and creatinine was 2.1 mg/dl.

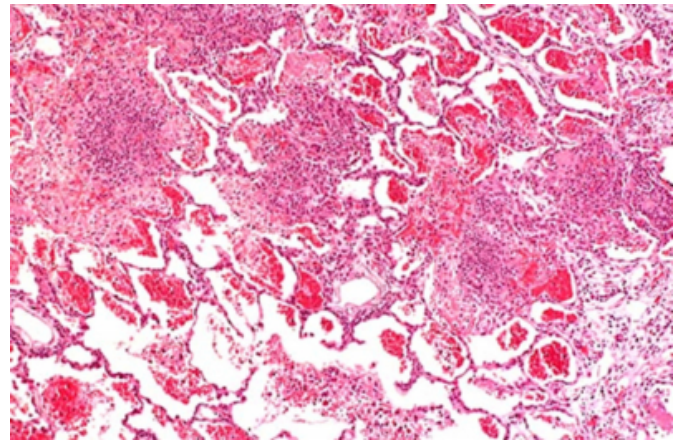
Erythrocyte sedimentation rate was 125 mm/hr. Antinuclear antibodies, antineutrophil cytoplasmic antibodies, double stranded DNA, Hepatitis B antibodies, Hepatitis C antibodies, Complement (C3-C4), antibasement membrane antibodies were negative. The admission chest x-ray showed diffuse alveolar infiltrates.

**Figure 2**



Fiberoptic and transbronchial biopsies performed on the day of admission showed alveolar hemorrhage and fibrinous exudates with abundant interstitial neutrophils consistent with the diagnosis of pulmonary capillaritis.

**Figure 3**



Smears and cultures of bronchial washings were negative for any bacteria, fungi, and mycobacteria. Bronchial cytology was negative for malignant cells.

On second day of admission, the patient was started on pulse methylprednisone. Patient continued to require higher concentration of oxygen and her kidney function deteriorated. Creatinine increased to 5.3 mg/dl, when pulse therapy with cyclophosphamide at 750 mg/m<sup>2</sup> was started.

On day four, the patient showed signs of improvement with decrease in her oxygen requirements. Her chest x-ray started to clear and her creatinine decreased to 3.3 mg/dl. The patient continued to improve and was extubated successfully on day twelve. Patient's stay was complicated by lower gastrointestinal bleeding requiring blood transfusions and was shown to be due to ulcerative lesions at the rectosigmoid junction. Biopsy of the lesion taken did not show any evidence of vasculitis.

Patient's condition improved and on day 30 she developed symptomatic AV node block. A pacemaker was inserted. The cardiac profile was consistent with acute myocardial infarction and on day 32 the patient expired. Patient developed ventricular fibrillation and could not be resuscitated back. Autopsy was not granted.

## **DISCUSSION**

Classic polyarteritis nodosa involves both small and medium vessels and is associated with hypertension, but pulmonary capillaritis does not occur. Our patient fulfilled the criteria of classical polyarteritis nodosa by the American College of Rheumatology 1990. These criteria have a reported sensitivity of 82.2% and a reported specificity of 86.6% for the classification of polyarteritis nodosa compared with other vasculitides (6). Our patient had weight loss of 10 kgs

since the illness began, elevated BUN and creatinine, worsening of hypertension and renal arteriogram showing classical findings of microaneurysms consistent with Polyarteritis nodosa. This time our patient presented with respiratory failure due to alveolar hemorrhage and pulmonary capillaritis. Pulmonary capillaritis is a histopathologic diagnosis that is not pathognomonic of a specific disorder, it usually signals the presence of an underlying systemic vasculitis or collagen vascular disease. Patients with pulmonary capillaritis usually present with bilateral infiltrates on chest radiographs and can be acutely ill with diffuse alveolar hemorrhage that may be life threatening. Therapy depends on diagnosis of the underlying disease that gave rise to the capillaritis (7)

Pulmonary capillaritis has been reported with variable frequency and severity as a manifestation of Wegener's granulomatosis, microscopic polyarteritis, systemic lupus erythematosus, Goospasteur's syndrome, idiopathic pulmonary renal syndrome, Behcet's syndrome, Henoch-Scholein purpura, IgA nephropathy, antiphospholipid syndrome, progressive systemic sclerosis and diphenylhydantoin use(8).

Amongst Collagen vascular diseases, SLE is the most frequent cause of diffuse alveolar hemorrhage and pulmonary capillaritis(9). It has been seen in few cases of polymyositis(10) and systemic sclerosis(11,12). Cases of diffuse alveolar hemorrhage due to pulmonary capillaritis has been seen to complicate Rheumatoid arthritis and Mixed connective tissue disease. It is not a part of systemic vasculitis but rather isolated small vessel vasculitis.(13)

Our patient did not have clinical or immunological criteria to support the diagnosis of lupus, antibasement membrane disease, or a collagen vascular disease.

In Wegener's, the sole histologic finding of pulmonary capillaritis was described in 3 out of 122 patients. (14) The lack of histologic features and more typical respiratory tract lesions makes Wegener's less likely.

Microscopic polyangiitis can be a good possibility in our patient. It is a form of necrotizing small vessel vasculitis that affects venules, capillaries, arterioles. It is the most common cause of pulmonary renal vasculitic syndrome(15). Our patient this time presented with pulmonary capillaritis as well as glomerulonephritis.

Ten patients were prospectively studied who had features of systemic vasculitis that could not be classified into one of the well-defined vasculitic syndromes. Since many of these syndromes had overlapping features of several distinct vasculitides, they were classified as the polyangiitis overlap syndrome(16).

We describe a case of Polyarteritis nodosa which overlaps with Microscopic Polyangiitis (MPA) or other unclassified collagen vascular disease. We conclude that pulmonary capillaritis can coexist with "classical" polyarteritis nodosa.

### References

1. Moskowitz et al. Histopath. Classification of Periarthritis nodosa. A study of 56 cases confirmed at necropsy. Mayo Clin. Proc. 38: 345-352.
2. Rose et al. Polyarteritis nodosa Q.J. Med. 26: 43-81, 1952.
3. Bocanegra TS, Espinoza LR, Vasey FB. Pulmonary hemorrhage in systemic necrotizing vasculitis associated with hepatitis B. Chest 1981;80, 102-103.
4. Nick J, Tuder R, May R .Polyarteritis nodosa with pulmonary vasculitis.Am J Respir Crit Care Med 1996;153,450-453.
5. Savage CO et al. Microscopic polyarteritis; Presentation, pathology, and prognosis. QJ Med 1985; 56:467-83.
6. Lightfoot et al. The American College of Rheumatology 1990, Criteria for the Classification of polyarteritis nodosa. Arthritis and Rheumatism Vol. 33, No. 8, August 1996,1088-1093
7. Franks TJ, Koss MN. Pulmonary capillaritis. Curr Opin Pulm Med. 2000 Sep;6(5):430-5.
8. Ronald J, Stephen J, Sally A et al. Pulmonary Capillaritis and Alveolar Hemorrhage. Update on Diagnosis and Management. Chest 1996; 110, 1305-1316.
9. Zamora MR, Warner ML, Tuder R et al. Diffuse alveolar hemorrhage and systemic lupus erythematosus: Clinical presentation, histology, survival and outcome. Medicine 1997; 76: 192- 201.
10. Schwarz MI, Sutarik JM, Nick JA et al. Pulmonary capillaritis and diffuse alveolar hemorrhage: a primary manifestation of polymyositis. Am J Respir Crit Care Med.1995;151:2037-40.
11. Griffin MT, Robb JD, Martin JR. Diffuse alveolar hemorrhage associated with progressive systemic sclerosis. Thorax 1990; 45: 903-04.
12. Kallenbach J, Priasloo I, Zwi S. Progressive systemic sclerosis complicated by diffuse alveolar hemorrhage. Thorax. 1977; 32:767-70\13.
13. Schwarz MI, Zamora MR et al. Isolated pulmonary capillaritis and Diffuse Alveolar Hemorrhage in Rheumatoid Arthritis and Mixed Connective Tissue disease. Chest. 1998;113;1609-1615.
14. Mark EG et al. The pulmonary biopsy in early diagnosis of Wegener's. Human Path.1988; 9:1065-71.
15. Jennette JC, Thomas DB, Falk RJ.Microscopic polyangiitis.Semin Diagn Pathol.2001 Feb;18: 3-13.
16. Leavitt et al. Polyangiitis overlap syndrome. Classification and prospective clinical experience. Am. J. Med. 1986; 81-, 79-85.

**Author Information**

**Asma Taj, MD**

Department of Internal Medicine University of Toledo Medical Centre 3000 Arlington Avenue Toledo Ohio 43614

**Shaffi Kanjwal**

Department of Pulmonary Critical Care and Sleep Medicine University of Toledo Medical Centre 3000 Arlington Avenue Toledo Ohio 43614

**Ragheb A. Assaly**

Professor of Medicine Program Director Internal Medicine Residency Program. University of Toledo Medical Centre 3000 Arlington Avenue Toledo Ohio 43614

**Jeffrey R. Hammersley**

Professor of Medicine Department of Pulmonary Critical Care and Sleep Medicine University of Toledo Medical Centre 3000 Arlington Avenue Toledo Ohio 43614