

# Acalculous cholecystitis in a septate gallbladder

I Wani, Z Bhat, A Charak, R Sofi

## Citation

I Wani, Z Bhat, A Charak, R Sofi. *Acalculous cholecystitis in a septate gallbladder*. The Internet Journal of Third World Medicine. 2008 Volume 7 Number 2.

## Abstract

A case of septate gall bladder, a rare entity, is presented . The patient was diagnosed incidentally during evaluation of pain right upper abdomen. Diagnosis was septate gallbladder with acalculous cholecystitis. The patient was managed conservatively and had cholecystectomy after 6 weeks.

## INTRODUCTION

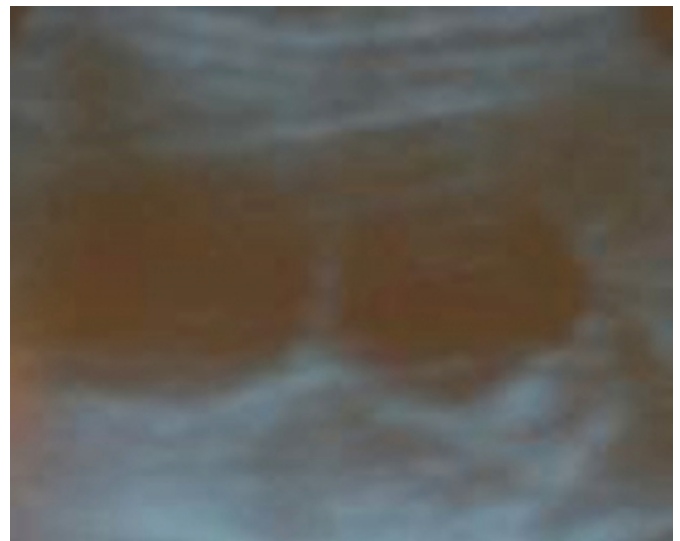
A number of congenital anomalies are reported with gallbladder affecting its shape, size, position and number. They may be detected incidentally or when they become symptomatic .Septate gallbladder is one of congenital anomalies which is rare. This anomaly run asymptomatic course in most of cases. Ultrasonography of the abdomen makes diagnosis early and avoids future complications.

## CASE REPORT

A 46 year old female presented with pain right upper abdomen and vomiting of 6 hours duration .She had similar episodes previously for the last 2 year for which she used to take pain killers and had relief but never had ultrasonography done. General physical examination was normal. Abdominal examination revealing tenderness in the right upper quadrant . Serum chemistry was normal and liver function tests did not show any increased level of bilirubin.X-ray abdomen was normal. Ultrasonography showed a septate gallbladder, septae dividing gallbladder longitudinally resulting in bilobed gall bladder, with thickened wall 8 mm having no gall stones suggestive of acalculous cholecystitis (Fig.1,2) .

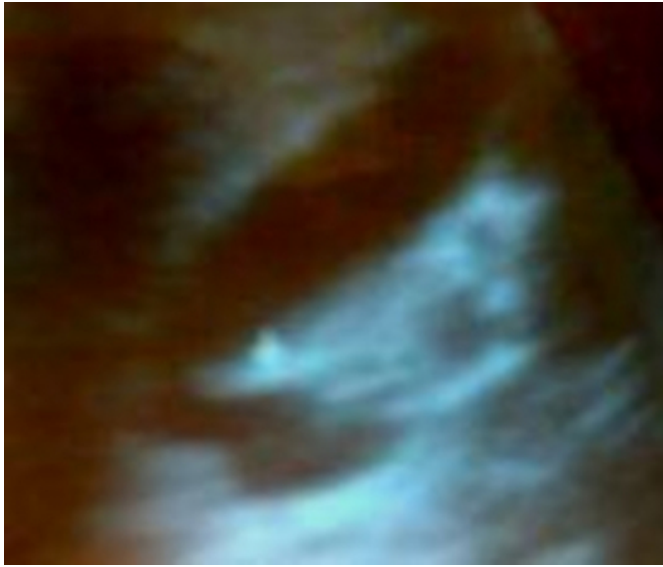
## Figure 1

Figure 1: showing a septum dividing gallbladder in two compartment with thickened wall



**Figure 2**

Figure 2: showing septum dividing gallbladder on longitudinal section



The patient was managed conservatively and had cholecystectomy done after 6 weeks and a longitudinal septum was dividing gallbladder in two cavities. The septum was extending from fundus to the neck of the gallbladder. Histopathology of the specimen was showing features of cholecystitis. Follow up period for one year was unremarkable.

**DISCUSSION**

The reported incidence of gall bladder anomalies is 0.1%<sub>1</sub>. Septate gall bladder is a congenital anomaly which is rarely reported, as they are usually asymptomatic and are found as a part of an evaluation for jaundice or rarely as a cause for recurrent abdominal pain<sub>2</sub>. Septate gallbladder is characterized by presence of septum that divides gallbladder into two chambers. Depending on the lay of septum, gallbladder is either bilobed or hour glass gallbladder. There is always presence of potential opening between two chambers making communication possible rarely this may be absent<sub>3</sub>. Septum dividing gallbladder can be single or multiple resulting in multi chamber cavity. Abberations in complete resolution of solid stage in its development result in septate gallbladder. Rarely post inflammatory adhesions

and compartmentalization resulting in septate gallbladder have been reported<sub>4</sub>, as in our case. When diseased, either one or both lobes of gallbladder may be diseased. Rarely due to septation there may be stone formation, which might lead to recurrent abdominal pain<sub>5</sub>. Septa of gall bladder induces stone formation. It is proposed that calculi are found to be more frequent in septate gallbladders than in unsegmented ones. Sometimes there may be associated anomalies with septate gallbladder like choledochal cyst or accessory hepatic duct. Misjudgment in such cases often leads to an unnecessary prolongation of the interval between diagnosis and operative treatment. Ultrasonography, computed tomography scan, <sup>99m</sup>TcIDA scintigraphy, endoscopic retrograde cholangiopancreatography (ERCP) and magnetic resonance cholangiopancreatography MRCP makes diagnosis definite and early preventing possible complications. Cholecystectomy is advocated in symptomatic patients of septate gallbladder, even when gallstones are not present.

**CONCLUSION**

In our case postinflammatory adhesions and compartmentilisation could have lead to septae of gallbladder as she had previous episodes of undiagnosed acute attack of cholecystitis.

**CORRESPONDENCE TO**

Imtiaz Wani Shodi Gali, Amira Kadal, Srinagar, Kashmir. India, 190009. Phone No. +9419904864 e-mail: imtazwani@yahoo.com

**References**

1. Johnson SR Development of the liver and biliary apparatus In Cunninghams Text Book of Anatomy, 12th edn Ed Romanes GJ Oxford, Oxford University Press, 1987, p 485.
2. Martinoh C, Derchi LE, Pastronno C, Cittadim G Imaging of a bilobed gall bladder Br J Radiol 1993; 66: 734-736.
3. St-Vil D, Luks FI, Hancock BJ, et al. Diaphragm of the gall bladder: case report. J Pediatr Surg 1992;27:1301-1303.
4. Ahear H, Barki Y. Multiseptate gallbladder in a child.: Incidental diagnosis on sonography. Pediatr Radiology 1990;20:192.
5. Flannery MG, Caster MP. Congenital hour-glass gall bladder. South Med J 1957;50:1255-8

**Author Information**

**Imtiaz Wani**

Post graduate Scholar, Dept. of Surgery, S.M.H.S Hospital

**Zubair Bhat**

Post graduate Scholar, Dept. of Surgery, Stephen's Hospital

**Akshay Charak**

Post graduate Scholar, Dept. of Surgery, S.M.H.S Hospital

**Rayees Sofi**

Resident, SKIMS Medical College