

# Right Supraclavicular Ectopic Thyroid: An Unusual Site Of Presentation

S Sahu, P Agarwal, M Husain, M Harsh, N Chauhan, P Sachan

## Citation

S Sahu, P Agarwal, M Husain, M Harsh, N Chauhan, P Sachan. *Right Supraclavicular Ectopic Thyroid: An Unusual Site Of Presentation*. The Internet Journal of Surgery. 2006 Volume 13 Number 1.

## Abstract

Ectopic thyroid glands are rare entities commonly found in the neck and reported in different parts of the body. Defects in the embryological development, implantation of thyroid fragments and abnormal migration of the thyroid gland usually result in this ectopic presentation. The ectopic thyroid is predisposed to a spectrum of inflammatory and neoplastic abnormalities similar to what may develop in a normal pretracheal gland. Surgical treatment of a symptomatic ectopic thyroid usually depends on the presence or absence of a normal pretracheal functioning thyroid.

## INTRODUCTION

The first endocrinal gland to appear during embryonal life is the thyroid gland, commencing its development at around 3 weeks of gestation. It arises as a midline endodermal swelling from the primitive pharynx between the first and second branchial arches just caudal to the tongue bud. The developing gland then descends into the neck, connected to the base of the tongue by the thyroglossal duct and reaches the final pretracheal site by the 7<sup>th</sup> week of gestation after which there is obliteration of the thyroglossal duct.<sup>1</sup>

## CASE REPORT

A 32-year-old male noticed a slowly progressive swelling in the right supraclavicular region since the last few years. There was no history of pain and fever associated with the swelling. There was no positive contributory history or significant family history. On examination, there was a single, non-tender, firm, mobile swelling situated in the right supraclavicular region measuring approximately 5x3cm with a well-defined margin. There was no associated lymphadenopathy in the rest of the cervical region. Examination of the thyroid was normal. Systemic examination was within normal limits.

On investigation, hemoglobin was 11.5gm/dl and total leukocyte count 6700/cu.mm with differential count: neutrophils 65%, lymphocytes 26%, eosinophils 7% and monocytes 2%.

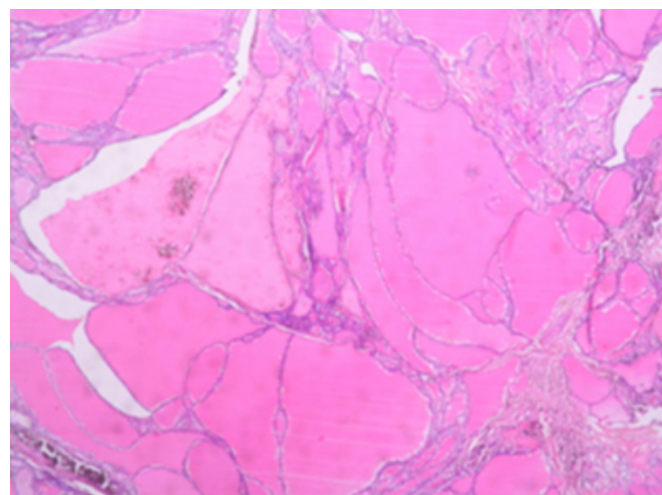
Excision of the lesion was done under local anaesthesia.

Histopathology of the lesion showed multiple large pieces of thyroid tissue with thyroid follicles of varying size and shape, lined by uniform cuboidal cells filled with colloid with some follicles showing cystic macrophages in the lumen. Intervening fibrous stroma showed large areas of hemosiderin deposition. These features were suggestive of ectopic thyroid with multinodular goitre (Fig-1 and Fig-2). However, the patient was lost on follow-up.

Ectopic thyroid. Histopathology of the lesion showed multiple large pieces of thyroid tissue with thyroid follicles of varying size and shape, lined by uniform cuboidal cells filled with colloid with some follicles showing cystic macrophages in the lumen.

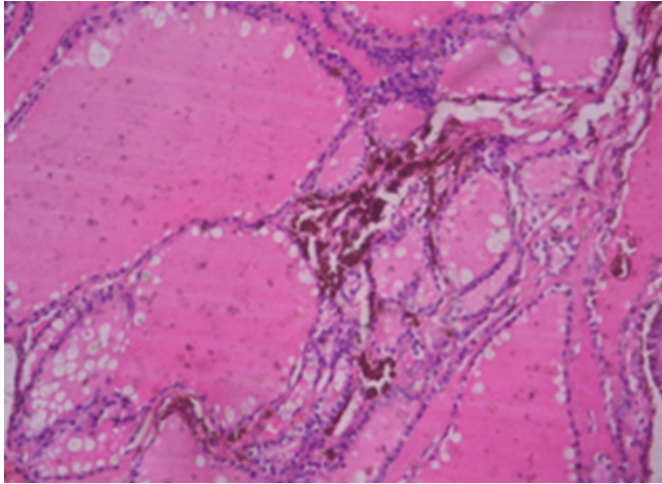
## Figure 1

Figure 1



**Figure 2**

Figure 2



Ectopic thyroid. Description see Fig. 1. Intervening fibrous stroma shows large areas of hemosiderin deposition.

### DISCUSSION

The incidence of ectopic thyroid gland is reported to be around 7-10%. Thyroid ectopia has been described in the lateral neck since the 18<sup>th</sup> century. It is commonly found along the course of the thyroglossal duct or around the two lobes of the gland. Lingual thyroid is the most common ectopic thyroid encountered at the base of the tongue, just posterior to the foramen caecum, followed by sublingual positions and locations in the anterior midline of the neck at or below the level of the hyoid bone. Thyroid ectopia has been described in the anterior tongue, submandibular region, larynx, trachea, parotid gland, posterolateral area of the neck, within the branchial cysts and at the carotid bifurcation. Esophagus, mediastinum, pericardium, lateral wall of heart (right ventricle), lungs, diaphragm and axilla are the sites described in the chest. In the abdomen, ectopic thyroids are reported in the liver, gallbladder, pancreas, duodenum, porta hepatis and adrenal gland. Pelvic ectopic thyroids are seen in the vagina.<sup>2, 3, 4, 5, 6, 7, 8, 9, 10, 11, 12, 13, 14,</sup>

<sup>15, 16, 17, 18, 23, 31</sup>

Thyroid ectopia is commonly encountered in females and is noticed in any age group. The pathogenesis of ectopic thyroid is still an enigma. On reviewing the literature, it was found that most of the early cases reported were detected in the neck and contained malignant thyroid tissues. Hence, they were termed as lateral aberrant thyroid tumors. Some of the authors attributed these to metastatic deposits of primary thyroid carcinoma (papillary) while others concluded that these are primary tumors of an aberrant thyroid gland. Later

benign ectopic thyroid tissues were reported by different authors who concluded that not all ectopic thyroids are malignant. Failure of migration of the developing thyroid gland anywhere along the path of the midline thyroglossal duct can result in a midline neck ectopic thyroid. Migration of the thyroglossal duct into the mediastinum or even abdomen can result in a mediastinal or intraabdominal ectopic thyroid. It has been postulated that ectopic thyroid glands are a result of embryological rests which have failed to fuse with the main thyroid tissue during development. They are also thought to be implants of thyroid fragments resulting from mechanical disruption of the gland secondary to any prior surgical procedure, trauma to the gland or sequestration of a nodule in the gland involved by a diffuse process such as thyroiditis or nodular hyperplasia.<sup>18, 19, 20, 21,</sup>

<sup>22, 24, 25, 26</sup>

Thyroid ectopia may present as the only functioning gland or may coexist along with a normal pretracheal thyroid. It usually presents as an asymptomatic mass and tends to increase in size when hormone demands increase, like in puberty, pregnancy and stress. Local symptoms such as obstruction, hemorrhage and other complications depend upon the site of the ectopic thyroid. Hypothyroidism is commonly associated with this rare entity.<sup>10, 27</sup>

The ectopic thyroid is predisposed to a spectrum of inflammatory and neoplastic abnormalities similar to what may develop in a normal pretracheal gland. Calcification, benign hyperplasia and multinodular goiter of an ectopic thyroid are some of the pathologic conditions reported by authors. Both follicular and papillary carcinomas have been described in ectopic thyroid glands.<sup>23, 28, 29</sup>

Ultrasonography with color Doppler imaging is the most sensitive imaging for detection of this rare entity. Scintigraphic studies may show Iodine I<sup>123</sup> or Technetium Tc<sup>99m</sup>-pertechnetate uptake by ectopic thyroid tissues. Computed tomography and magnetic resonance imaging are sometimes nonspecific in distinguishing ectopic thyroid from soft tissue masses or lymph nodes. Imaging may be used to guide fine-needle aspiration from the tissues.<sup>1, 30</sup>

Surgical management of a symptomatic ectopic thyroid depends upon the presence or absence of a normal thyroid gland. If the latter is present, simple excision of the ectopic tissue may be done. If the ectopic thyroid is the only gland present, the symptomatic gland may be excised and autotransplanted in the muscles of the neck, in the rectus abdominis muscle or in the lateral cervical gutter.

Radioiodine therapy is also an effective treatment for this rare entity. 10\* 16

## **CORRESPONDENCE TO**

Dr. Shantanu Kumar Sahu Assistant Professor, Department of General Surgery Himalayan Institute of Medical Sciences Swami Ram Nagar Post: Doiwala Dehradun Uttanchal Mob.: 0-9412933868 E-mail: Intshantanu@yahoo.co.in

## **References**

1. Taylor C, Kruskal J, Kane RA. Sonographic Detection of Synchronous Occurrence of Benign Nodules in Orthotopic and Ectopic Thyroid Tissue. *J Ultrasound Med* 2006; 25:137-140.
2. Yildiz K, Koksall H, Ozoran Y, Muhtar H, Telatar M. Papillary carcinoma in a thyroglossal duct remnant with normal thyroid gland. *Laryngol Otol*. 1993; 107:1174-1176.
3. Fellar KU, Marvos A, Gaertner HJ. Ectopic submandibular thyroid tissue with a coexisting active and normally located thyroid gland: case report and review of literature. *Oral Surg Oral Med Oral Pathol Oral Radiol Endo* 2000; 90:618-23.
4. Hari CK, Brown MJ, Thompson I. Tall cell variant of papillary carcinoma arising from ectopic thyroid tissue in the trachea. *J Laryngol Otol* 1999; 113:183-5.
5. Sand J, Pehkonen E, Mattila J, Seppanen S, Salmi J. Pulsating mass at the sternum: a primary carcinoma of ectopic mediastinal thyroid. *J Thorac Cardiovasc Surg* 1996; 112:833-5.
6. Casanova JB, Daly RC, Edwards BS, Tazelaar HD, Thompson GB. Intracardiac ectopic thyroid. *Ann Thorac Surg* 2000; 70:1694-6.
7. Bando T, Genka K, Ishikawa K, Kuniyoshi M, Kuda T. Ectopic intrapulmonary thyroid. *Chest* 1993; 103:1278-9.
8. Takahashi T, Ishikura H, Kato H, Tanabe T, Yoshiki T. Ectopic thyroid follicles in the submucosa of the duodenum. *Virchows Arch A Pathol Anat Histopathol* 1991; 418:547-50.
9. Shiraishi T, Imai H, Fukutome K, Watanabe M, Yatani R. Ectopic thyroid in the adrenal gland. *Hum Pathol* 1999; 30:105-8.
10. RT Ramesh, R Balakrishnan, S Prakashchandra, R Suresh. Ectopic thyroid tissue with a rare vascular anomaly. *Int. J. Morphol* 2007; 25:121-124.
11. Harach, H. R. Ectopic thyroid tissue adjacent to the gallbladder. *Histopathology*, 1998; 32:90-1.
12. Ghanem, N.; Bley, T.; Althoefer, C.; Hogerle, S., Langer, M. Ectopic thyroid gland in the porta hepatic and lingua. *Thyroid* 2003; 13:503-7.
13. Haruko A. Kuffner, Barry M. McCook, Rajendiran Swaminatha, Eugene N. Myers, Jennifer L. Hunt. Controversial Ectopic Thyroid: A Case Report of Thyroid Tissue in the Axilla and Benign Total Thyroidectomy. *Thyroid* 2005; 15:1095-1097.
14. Sambalo-Cabrer, I. F.; Real, J. M.; Ricart, W.; Barbas, J. F.; Olle, M. & Ternel, J. Ectopic thyroid tissue presenting as a submandibular mass. *Head Neck* 1996; 18(1):87-90.
15. Mysorekar VV, Dandekar CP, Sreevathsa MR. Ectopic thyroid tissue in the parotid salivary gland. *Singapore Med J* 2004; 45:437-438.
16. Sandhya Salain, Gabriel Rodrigues, Sampath Kumar: Sublingual Thyroid: A Case Report with Literature Review. *The Internet Journal of Surgery* 2007. Volume 11 Number 1.
17. Hollander EJ, Visser MJ, van Baalen JM. Accessory thyroid gland at carotid bifurcation presenting as a carotid body tumor: case report and review of the literature. *J Vasc Surg* 2004; 39:260-262.
18. Angela Fumarola, Pierpaolo Trimboli, Rossana Cavaliere, Iolanda Coletta, Alessandra Veltri, Agnese Di Fiore, Antonio Ciardi, Francesca Piccirilli. Thyroid papillary carcinoma arising in ectopic thyroid tissue within a neck branchial cyst. *World J Surg Oncol* 2006; 4:24.
19. Moses DC, Thompson NW, Nishiyama RH, Sisson JC. Ectopic thyroid tissue in the neck: benign or malignant? *Cancer* 1976; 38:361-365.
20. Rosai J, Carcangiu ML, Delellis RA. Tumors of the thyroid gland. In: *Atlas of Tumor Pathology*. 3rd series. Fascicle 5 ed. Washington, DC: Armed Forces Institute of Pathology; 1992; 317-324.
21. Sissons JC, Schmidt RW, Beierwaltes WH. Sequestered nodular goiter. *N Engl J Med* 1964; 270:927-932.
22. Clay RC, Blackman SS Jr. Lateral aberrant thyroid: Metastasis to lymph node from primary carcinoma of the thyroid gland. *Arch Surg* 1944; 48:223-8.
23. Agrawal R, Agrawal SR, Gupta DC, Gupta A. Ectopic multinodular goitre - An unusual case. *Indian J Otolaryngol Head Neck Surg* 2005; 57:350-352.
24. Sweeney EC, McDonnell L, O'Brien C. Medullary carcinoma of the thyroid presenting as tumours of the pharynx and larynx. *Histopathology* 1981; 5:263-75.
25. Arriaga MA, Meyers EN. Ectopic thyroid tissue in the retroesophageal superior mediastinum. *Otolaryngol Head Neck Surg* 1988; 99:338-340.
26. Gungor B, Kebat T, Ozaslan C, Akilli S. Intra-abdominal ectopic thyroid presenting with hyperthyroidism: report of a case. *Surg Today* 2002; 32:148-150.
27. Kumar R, Khullar S, Gupta R, Mawah A, Drm MA. Dual thyroid ectopy: case report and review of literature. *Clin Nucl Med* 2000; 25:253-254.
28. Subramony C, Baliga M, Lemos LB. Follicular carcinoma arising in ectopic thyroid tissue: case report with fine-needle aspiration findings. *Diag Cytopathol* 1997; 16:39-41.
29. LiVolsi VA, Perzin KH, Savetsky L. Carcinoma arising in median ectopic thyroid (including thyroglossal duct tissue). *Cancer* 1974; 34:1303-1315.
30. Ohnishi H, Sato H, Noda H, Inomata H, Sasaki N. Color Doppler ultrasonography: diagnosis of ectopic thyroid gland in patients with congenital hypothyroidism caused by thyroid dysgenesis. *J Clin Endocrinol Metab* 2003; 88:5145-5149.
31. Maino K, Skelton H, Yeager J, Smith KJ. Benign ectopic thyroid tissue in a cutaneous location: a case report and review. *Journal of Cutaneous Pathology* 2004; 31:195-198.

**Author Information**

**Shantanu Kumar Sahu, MS (General Surgery)**

Assistant professor, Surgery, Department of General Surgery, Himalayan Institute of Medical Sciences

**Puneet Kumar Agarwal, MS (General Surgery)**

Assistant professor, Surgery, Department of General Surgery, Himalayan Institute of Medical Sciences

**Musharraf Husain, MS (General Surgery), DNB (General Surgery), MRCS (Edin)**

Assistant professor, Surgery, Department of General Surgery, Himalayan Institute of Medical Sciences

**Meena Harsh, MD (Pathology)**

Professor, Pathology, Department of General Surgery, Himalayan Institute of Medical Sciences

**Neena Chauhan, MD (Pathology)**

Assistant Professor, Pathology, Department of General Surgery, Himalayan Institute of Medical Sciences

**Praveendra Kumar Sachan, MS (General Surgery)**

Professor and Head, Department of General Surgery, Himalayan Institute of Medical Sciences