

# Rare case of Hem-o-Lok clip Migration after Robotic Radical Prostatectomy

S Allaparthi

## Citation

S Allaparthi. *Rare case of Hem-o-Lok clip Migration after Robotic Radical Prostatectomy*. The Internet Journal of Urology. 2009 Volume 6 Number 2.

## Abstract

Hem-o-Lok clip usage is well described in robotic radical prostatectomy (RRP) for control of lateral pedicles. We report a rare case of intravesical migration of Hem-o-Lok clips after robotic radical prostatectomy that resulted in bladder calculus. A literature review done with Food and Drug Administration Manufacturer and User Facility Device Experience (MAUDE) database showed reporting of similar cases.

## INTRODUCTION

The Da Vinci Surgical Robotic System® (DSRS) is been increasingly used to perform robotic radical prostatectomy (RRP) for prostate cancer (1). During robotic radical prostatectomy multiple modalities are used for hemostasis and Hem-o-lok clips® (HOLC) (Weck Surgical Instruments, Teleflex Medical, Durham, NC) usage was well documented for lateral pedicles. A thorough literature search for HOLC migration and intravesical foreign bodies showed multiple case reports and reviews, the most common cause was iatrogenic in nature(2). Although the frequency of such cases is uncommon, it should be considered in patients who complain of unexplained urinary tract symptoms. There have been reports of retained catheter tips, migration of intrauterine contraceptive devices into the urinary bladder, and physicians should always be aware of the possibility when investigating patients with recurrent urinary sepsis(3, 4). Foreign bodies in bladder act as a nidus for bladder stone formation due to a persistent chronic inflammation. Kosan et al.(5) investigated the tissue reaction to different suture materials in the bladder wall of rats, their role in stone formation and found it was the duration of time from having a foreign body in the bladder that was the greatest predictor of stone formation on suture material. We report a case of intravesical migration of HOLC resulting in calculus formation after robotic radical prostatectomy.

## CASE REPORT AND MANAGEMENT

A 65-year-old gentle man presented to our institution with a diagnosis of stage T2A prostate cancer. His serum prostate-specific antigen (PSA) was 5.6 ng/mL and a transrectal

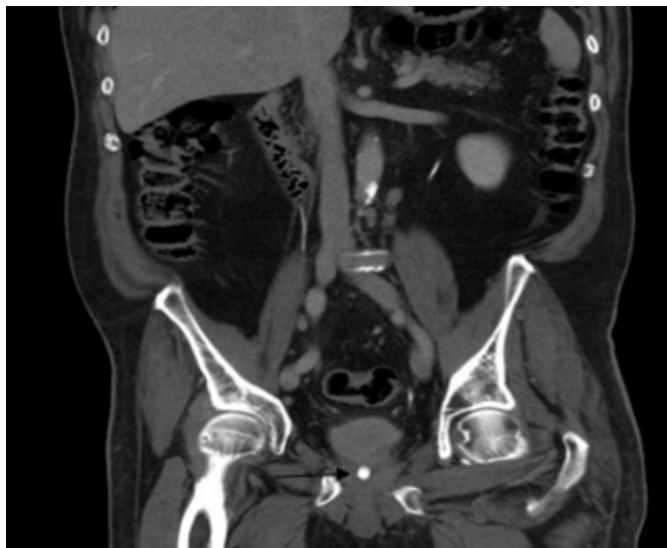biopsy demonstrated Gleason 3+3=6 in 70% to 100% of cores from the left base, apex, and mid gland. After discussion of treatment options, he had endorectal MRI done as a part of metastatic workup. Under general anesthesia, the patient was placed in low lithotomy and steep head down position after securing to the table using 2-inch tape. All pressure points were fully padded and the entire abdomen, external genitalia and perineum prepped and draped in a standard fashion. We used standard 5-port transperitoneal approach. Intra operatively the patient had a prominent median lobe, which was included in the dissection, and the posterior wall of the bladder incised. We met with considerable difficulty dissecting the ampulla and the seminal vesicles in this area that seemed to be totally scarred, and the anatomy was less than obvious. With considerable difficulty, we were able to identify the vas and transect both the vas. The deep dorsal venous complex secured using a figure-of-eight 2-0 Vicryl and divided. An excellent urethral length obtained, and the urethra divided sharply. To achieve hemostasis a combination of meticulous dissection, bipolar cautery and HOLC used judiciously. Intracorporeal running 3-0 monocril suture was used for vesicourethral anastomosis. Post operative pathology showed Gleason 3+4=7 with negative lymph nodes, margins, no seminal vesicle invasion or angiolymphatic invasion. His postoperative recovery course was unremarkable.

Eighteen months after the surgery the patient presented with irritative lower urinary tract symptoms (LUTS) predominantly urgency and frequency with minimal post void residual. A computed tomography (CT) scan of the

abdomen demonstrated calculus in the bladder (Figure-1). Rigid Cystoscopy confirmed a 1-cm calculus around the HOLC at bladder neck region (Figure-2). Holmium laser cystolithopaxy was used to fragment the stone and HOLC was successfully removed, using an alligator grasper. Patient had no residual lower urinary tract symptoms at end of 3 months.

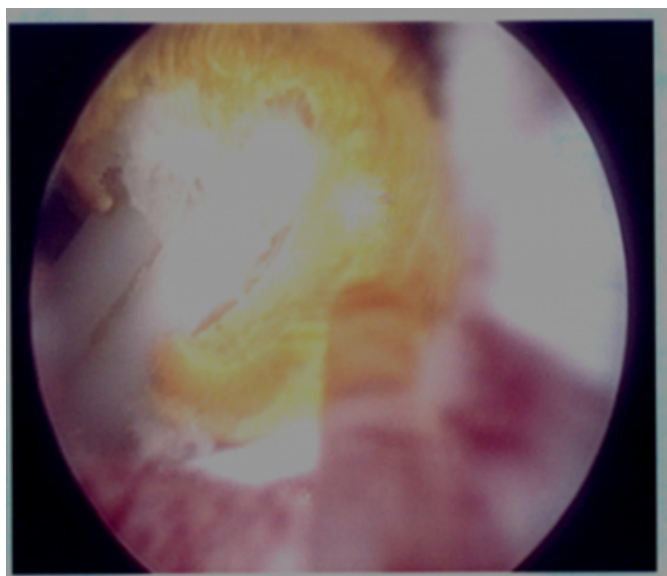
### Figure 1

Figure 1. CT scan demonstrates the presence of a calculus in the region of the bladder neck. (Arrow)



### Figure 2

Figure 2- Hem-o-lok clip with stone formation on cystoscopy. Clip (white) and stone (yellow)



## DISCUSSION

Robotic assisted radical prostatectomy has been widely

accepted and used in the treatment of prostate cancer (1). First described in 1997, it has been shown to have similar oncologic efficacy, and low peri-operative morbidity compared with open radical retro pubic prostatectomy. During this minimally invasive procedure, several methods were used to ensure adequate hemostasis. A commonly used device is the HOLC, which was shown to be safe and reliable for vascular control in laparoscopic procedures. To date, there have been some reports of intravesical migration of these clips causing urethral erosion, bladder neck contractures and subsequent calculus formation (6) (7) (8) (9). However, calculus formation on sutures after vesicourethral anastomosis was reported.

To our knowledge, we report the first case of HOLC migration after robotic radical prostatectomy resulting in bladder calculus formation. Although these types of cases are well reported in literature, our experience brings to light questions regarding the use of foreign bodies in close proximity to the vesicourethral anastomosis during RALP. Using a search of the MAUDE database, Meng (10) identified 27 reports of failure pertaining to the nonabsorbable polymer Hem-o-Lok clip. Of these, 48% (N=13) were during urological laparoscopic surgery, of which bleeding was the primary problem in 77%. No clear etiologies were found to account for the events. Nearly all (96%) occurred during laparoscopic procedures, and 44% of the operations were for removal of the kidney (10).

A search of the MAUDE database for complications during laparoscopic prostatectomy when using the Hem-o-Lok device found a report on a bilateral nerve-sparing robotic-assisted laparoscopic prostatectomy in which a patient presented 3 months after surgery complaining of urethral pain (7). In addition, clip migration after other laparoscopic procedures were blamed for stone formation in the bladder. However, these clips are a useful adjunct in laparoscopy, techniques like hydro dissection and usage of transient bulldog clamping and suturing described in literature (11). We have modified our surgical technique, adapting these techniques with minimal usage of HOLC and minimal electrocautery in this region.

## References

1. Badani KK, Kaul S, Menon M. Evolution of robotic radical prostatectomy: assessment after 2766 procedures. *Cancer*. 2007 Nov 1;110(9):1951-8.
2. Rafique M. Intravesical foreign bodies: review and current management strategies. *Urol J*. 2008 Fall;5(4):223-31.
3. Maskey C, Rahman M, Sigdar T, Johnsen R. Vesical calculus around an intra-uterine contraceptive device. *Br J Urol*. 1997;79(4):654-5.

4. Guvel S, Tekin M, Kilinc F, Peskircioglu L, Ozkardes H. Bladder stones around a migrated and missed intrauterine contraceptive device. *International Journal of Urology*. 2001;8(2):78.
5. Kosan M, Gonulalan U, Ozturk B, Kulacoglu S, Erguder I, Akdemir O, et al. Tissue reactions of suture materials (polyglactine 910, chromed catgut and polydioxanone) on rat bladder wall and their role in bladder stone formation. *Urological Research*. 2008;36(1):43-9.
6. Tunnard GJ, Biyani CS. An Unusual Complication of a Hem-o-Lok Clip((R)) Following Laparoscopic Radical Prostatectomy. *J Laparoendosc Adv Surg Tech A*. 2009 Jun 2.
7. Moser RL, Narepalem N. Erosion of Hem-o-Lok clips at the bladder neck after robot-assisted radical prostatectomy. *J Endourol*. 2009 Jun;23(6):949-51.
8. Blumenthal K, Sutherland D, Wagner K, Frazier H, Engel J. Bladder neck contractures related to the use of Hem-o-Lok clips in robot-assisted laparoscopic radical prostatectomy. *Urology*. 2008;72(1):158-61.
9. Tugcu V, Polat H, Ozbay B, Eren GA, Tasci AI. Stone formation from intravesical Hem-o-lok clip migration after laparoscopic radical prostatectomy. *J Endourol*. 2009 Jul;23(7):1111-3.
10. Meng M. Reported failures of the polymer self-locking (Hem-o-Lok) clip: Review of data from the Food and Drug Administration. *Journal of Endourology*. 2006;20(12):1054-7.
11. Gill IS, Ukimura O. Thermal energy-free laparoscopic nerve-sparing radical prostatectomy: one-year potency outcomes. *Urology*. 2007 Aug;70(2):309-14.

**Author Information**

**Satya Allaparthi, MS, MRCS (Edin), MD**

Division of Urology, Department of Surgery, University Of Massachusetts Medical School