

A Case of Testicular Regression Syndrome

A Desai, R Verma, M Parab

Citation

A Desai, R Verma, M Parab. *A Case of Testicular Regression Syndrome*. The Internet Journal of Surgery. 2008 Volume 21 Number 2.

Abstract

The non-palpable absent testicle is a problem that confounds urologists and pediatric surgeons alike. This entity, when associated with a blind-ending spermatic cord is referred to as the “vanishing testis syndrome” in the urologic literature or “testicular regression syndrome” (TRS) in the pathologic literature. Up to one half of non-palpable cryptorchid testes are found on exploration to be “vanished” and such tissue shows characteristic histopathological findings. We would like to present such a case of testicular regression syndrome at our institute.

CASE REPORT

A 16-year-old male came to our hospital with the complaint of having a small-sized testicle on the left side. The patient noticed this finding accidentally, while he was playing and a ball hit him on the scrotum. He did not have any scrotal swelling or any other complaint.

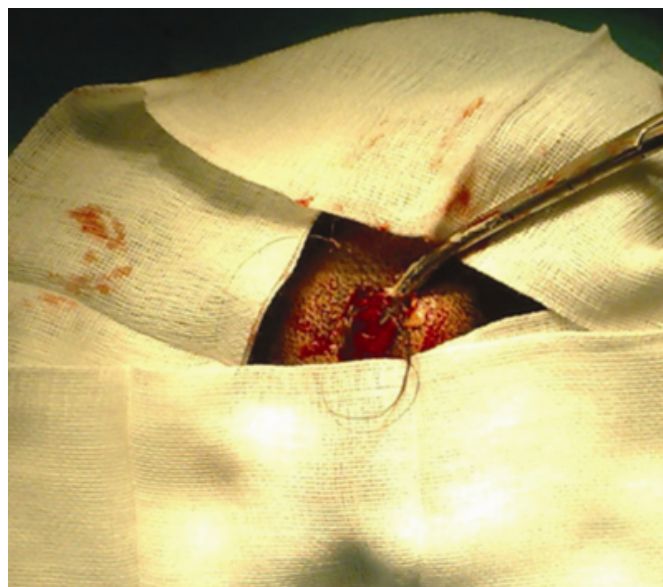
On examination, he was averagely built and averagely nourished. All secondary sexual characters were developed. His right testicle appeared normal. His left testicle was palpated at the root of the scrotum. It was small in size, i.e. about 0.3 x 0.4 x 0.3cm. It was soft and flabby. There was no impulse on coughing in any of the hernial sites. No other genital abnormality was noted.

Ultrasonography revealed the presence of a left-sided atrophic testis. His semen analysis showed the presence of decreased sperm counts. He was subjected to left sided orchidectomy after counseling the patient and the relatives.

Histopathology showed presence of atrophy with dystrophic calcification and hemosiderin-laden macrophages, thus suggesting the diagnosis of testicular regression syndrome.

Figure 1

Figure 1 Histopathology of testis showing hemosiderin-laden macrophages



DISCUSSION

The vanishing testis may be better known as testicular regression syndrome in the pathologic literature. Such individuals are genetically male (46, XY), presenting with unilateral or bilateral absence of recognizable testis structures and absence of the Müllerian duct system. In actuality there is a spectrum of syndromes characterized as TRS, the exact categorization depending on the stage of fetal or early neonatal life at which testicular function ceased.[1,2] Within this range of syndromes, only the vanished testis is associated with late fetal/early neonatal regression.

One fifth of the 0.7% to 1.0% of males who present with cryptorchidism at age 12 months or older are found to have a non-palpable gonad.[3] Forty per cent of this subpopulation are thought to harbor a vanished testis.[4] In the majority of these cases, a fibrous nubbin of tissue is found at the terminus of the spermatic cord. The pathologic findings, where reported [5,6], show consistent and distinctive features, including discrete fibrosis, dystrophic calcification and hemosiderin deposition. These features, especially when associated with spermatic cord structures, render pathologic recognition of testicular regression accurate.

Failure to discover the gonad at the time of exploration in a patient with spermatic cord duct structures occurs in 1 of 2 situations: (1) the gonad has undergone regression, or (2) the surgeon has not yet localized it. The pathologist may play a pivotal role in the management of these patients. Since 95% of testes are localized at or below the internal inguinal ring, pathologic evaluation of the spermatic cord and confirmation of the testis as regressed on tissues removed at primary inguinal exploration can reassure the surgeon and the patient's family of the proper diagnosis. It can also eliminate the necessity for further surgical intervention or for radiologic evaluation in a majority of cases

There are cases in which the testis was thought pathologically absent while the surgical impression was that of atrophic or degenerative testis. In contrast, all but one of the prior pathologic reviews of TRS in the literature were limited to cases selected to show features of TRS supported by surgical findings. Fibrosis is reported as the finding most

frequently or universally present in TRS in other studies.[5,6]

The surgical literature regarding TRS emphasizes the importance of identification of vasculature supplying and draining the gonad. This is due to the fact that a testis cannot be present in a location with absent gonadal vein and because the vein and the pampiniform plexus almost always indicate the location of the testis [7,8], regardless of the presence of vas deferens and epididymis. This feature has not been emphasized in the pathology literature.

References

1. Selby DM. Sexual maldevelopment syndromes. In: Stocker JT, Dehner LP, eds. *Pediatric Pathology* Philadelphia, Pa: JB Lippincott Co. 1992:117–159.
2. Naffah J. Familial testicular regression syndrome. *Bull Acad Natl Med* 1989;173:709–714
3. Levitt SB, Kogan SJ, Engel RM, Weiss RM, Martin DC, Ehrlich RM. The impalpable testis: a rational approach to management. *J Urol* 1978;120:515–520.
4. Ferro F, Lais A, Bagolan P, Talamo M, Caterino S. Impact of primary surgical approach in the management of impalpable testis. *Eur Urol* 1992;22:142–146.
5. Smith NN, Byard RW, Bourne AJ. Testicular regression syndrome: a pathological study of 77 cases. *Histopathology* 1991;19:269–272.
6. Grady RW, Mitchell ME, Carr MC. Laparoscopic and histologic evaluation of the inguinal vanishing testis. *Urology* 1998;52:866–869.
7. Kirsch AJ, Escala J, Duckett JW, et al. Surgical management of the nonpalpable testis: the Children's Hospital of Philadelphia's experience. *J Urol* 1998;159:1340–1343.
8. Weiss RM, Glickman MG, Lytton B. Venographic localization of the nonpalpable, undescended testis in children. *J Urol* 1997;117:513–517

Author Information

Amit A. Desai, M.S. D.N.B.

Senior Postgraduate Registrar, Department of Surgery, K.J.Somaiya Medical College

Radha A. Verma, M.S.

Professor and Unit Head, Department of Surgery, K.J.Somaiya Medical College

Mrunal B. Parab, M.B.B.S.

Postgraduate Student, Department of Surgery, K.J.Somaiya Medical College