

# Successful Resuscitation of Massive Exsanguination during Ambulatory Surgery: A Formidable Challenge

A Truong

## Citation

A Truong. *Successful Resuscitation of Massive Exsanguination during Ambulatory Surgery: A Formidable Challenge*. The Internet Journal of Anesthesiology. 2009 Volume 26 Number 1.

## Abstract

In the United States, nearly 80% of all surgical procedures are performed on an outpatient basis. 1 Central venous catheter placement for chemotherapy or bone marrow transplantation is thus routinely done in an ambulatory center, remote from the main operating room. We report a case of a massive hemothorax sustained during outpatient subclavian venous cannulation. An early diagnosis, effective resuscitation, and timely surgical repair of a lobar pulmonary artery laceration led to the patient's survival.

## INTRODUCTION

In the United States, nearly 80% of all surgical procedures are performed on an outpatient basis. 1 Central venous catheter placement for chemotherapy or bone marrow transplantation is thus routinely done in an ambulatory center, remote from the main operating room. Generally considered as relatively minor, this invasive procedure nevertheless carries significant risks of serious, potentially fatal, complications. 2,3 The occurrence of sudden profuse intrathoracic hemorrhage in an outpatient setting creates extraordinary challenges to resuscitation. We report a case of a massive hemothorax sustained during outpatient subclavian venous cannulation. An early diagnosis, effective resuscitation, and timely surgical repair of a lobar pulmonary artery laceration led to the patient's survival. This case highlights the formidable challenges of resuscitation and the principles of successful management under these critical circumstances.

## CASE REPORT

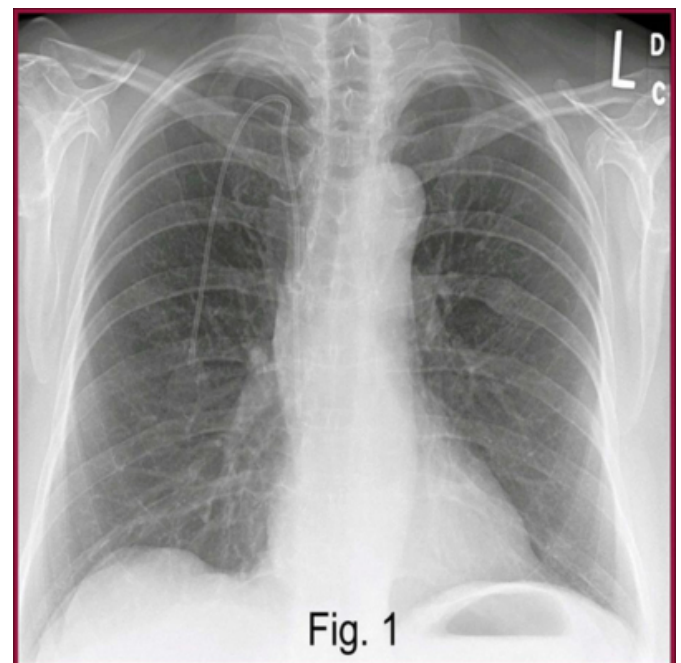
A 66-year-old woman with refractory multiple myeloma presented for outpatient subclavian venous catheter placement in preparation for autologous stem cell transplant. She had received radiotherapy followed by chemotherapy with dexamethasone and thalidomide but failed to achieve remission criteria. She then received melphalan, again without satisfactory response. Preoperative review of systems revealed no other significant medical problems. Physical examination was essentially unremarkable. Bone survey showed healed compression fractures of T4, T6 and

L1. Hemoglobin (Hb) was 12.5g/dL and hematocrit (Hct) 37 L%. Her height was 163 cm, weight 83 kg and body mass index (BMI) 31. The procedure was done with monitored anesthesia care (MAC) because the patient could not lie supine due to severe pain in her thoracic spine. In the outpatient surgery suite, standard American Society of Anesthesiologists (ASA) monitors were applied. Vital signs prior to the induction of MAC included blood pressure (BP) 145/77 mmHg, heart rate (HR) 72 beats/min (bpm), respiratory rate (RR) 18/min, and oxygen saturation (O<sub>2</sub> sat) 99% on room air. An 18-gauge peripheral intravenous (IV) cannula was placed in the right wrist. An infusion of plasmalyte was started. Midazolam 2 mg and fentanyl 100 mcg were given followed by a continuous infusion of propofol 75 mcg . kg<sup>-1</sup>. min<sup>-1</sup>. Cannulation of the left subclavian vein was started. Hemodynamic parameters were stable with BP in the range of 130-145/60-77 mmHg and HR 70-85 bpm until about 30 minutes into the procedure. At that time, HR increased steadily to 100-115 bpm. Shortly after, BP decreased to 80-94/43- 50 mmHg. Fluids were rapidly infused and repeated boluses of phenylephrine 100 mcg given without sustained improvement. The propofol infusion was discontinued. A 16-gauge IV catheter was placed in the right basilic vein. Simultaneously, a liter (L) of plasmalyte and 500 ml of 5% albumin were rapidly given. Despite vigorous fluid resuscitation, vital signs continued to deteriorate and repeated boluses of epinephrine 100 mcg were needed to support BP. At that point, even though a BP of 78/40 mmHg was still obtainable by cuff, a cardiac arrest emergency was activated to assist in resuscitation.

Uncrossmatched type-specific blood was requested from the blood bank for immediate transfusion. The main operating room was alerted to have a cardiothoracic surgery team ready. The patient's breathing became fast, shallow and labored with markedly decreased breath sounds over the left hemithorax. Simultaneously, the patient was intubated and resuscitated per Advanced Cardiac Life Support (ACLS) protocol while a 14-gauge cannula was inserted in the left second intercostal space in the midclavicular line, releasing copious amounts of dark blood. A chest tube was emergently placed, draining over 3 L of blood. A 9-French introducer was inserted in the right femoral vein. The patient was urgently transferred to the main operating room (OR) for emergency thoracotomy. On arrival to the OR, BP was 82/41 mmHg, HR 91 bpm and O<sub>2</sub>sat 100%. A 20-gauge cannula was placed in the right radial artery. Laboratory results showed Hb 4.1 g/dL, Hct 11.5 L%, platelets 61.109/L, pH 7.02, pO<sub>2</sub> 280 mmHg on FIO<sub>2</sub> 100%, pCO<sub>2</sub> 47 mmHg, lactate 9.4 mmol/L, base excess (BE) 19 mmol/L and bicarbonate 12 mmol/L. The left chest was quickly opened by median sternotomy with left subclavicular extension. An additional 3 L of blood were evacuated. A left upper lobe laceration with brisk bleeding from a lobar pulmonary artery was identified and surgically repaired. There was no bleeding from either the left subclavian vein or artery. With bleeding under control, the patient's hemodynamic status stabilized. At the conclusion of surgery, the patient was transferred to the intensive care unit (ICU). Total estimated blood loss was 8 L. During resuscitation and surgery, 8 units of whole blood, 2 units of fresh frozen plasma, 8 units of platelets, 2 L of 5% albumin and 4.5 L of plasmalyte were given. On arrival to the ICU, parameters included BP 124/67 mmHg, HR 78 bpm, CVP 7 mm Hg, O<sub>2</sub>sat 100%, Hb 11.7 g/dL, Hct 33.8 L%, platelets 94.109/L, pH 7.43, pO<sub>2</sub> 94 mmHg on 40% FIO<sub>2</sub>, pCO<sub>2</sub> 39 mmHg, bicarbonate 25 mmol/L, BE +1, O<sub>2</sub> sat 99%, lactate 1.7 mmol/L, m BUN 11mg/dL, and creatinine 0.6mg/dL. The endotracheal was removed the following day. Postoperative neurological examination showed no deficits. Serial cardiac enzymes were within normal range. The patient was discharged home in good condition 7 days after the event.

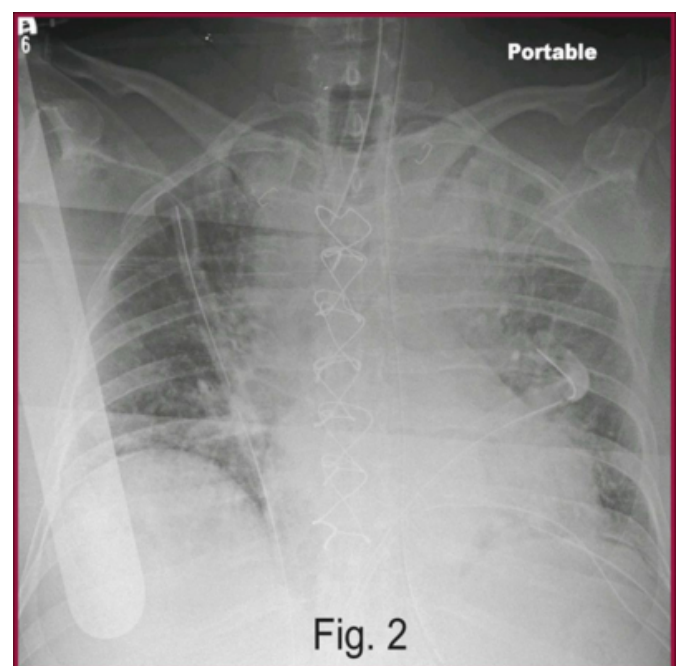
**Figure 1**

Figure 1: Preoperative chest X-ray



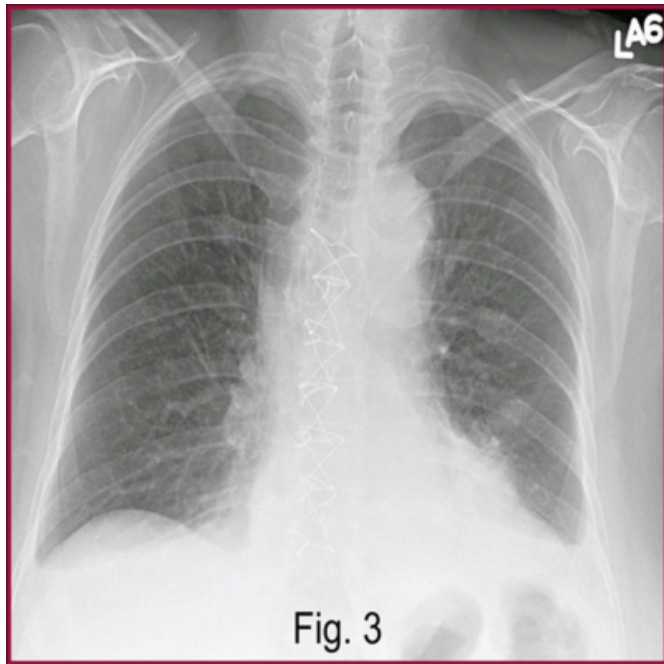
**Figure 2**

Figure 2: Immediate postoperative chest X-ray



**Figure 3**

Figure 3: Follow-up chest X-ray



## DISCUSSION

The complex challenges of this case arise from the combination of two factors: severe intrathoracic hemorrhage and the outpatient setting. First, hemothorax due to major vascular injury is usually sudden and massive. In a matter of minutes, profuse intrathoracic bleeding transformed a routine ambulatory procedure into a life-threatening emergency. Without rigid structures in the pleural cavity to tamponade the hemorrhage, relentless exsanguination continued. When severe hypotension and tachycardia exceeding 120 bpm occurred, 30-40% of the patient's blood volume had already been lost.<sup>4</sup> Finally, the accumulation of large volumes of blood in the pleural cavity ultimately caused tension hemothorax, impairing normal function of the heart, great vessels and contralateral lung.

Even when such a major event occurs in the main operating room, it constitutes one of the most difficult challenges in resuscitation. In the ambulatory setting, these difficulties are exponentially compounded. Outpatient central venous cannulations are usually done without the presence of an anesthesiologist. Monitoring of the patient is often performed by an ambulatory care nurse. Furthermore, monitoring equipment in outpatient centers is often suboptimal. Consequently, it is difficult to make an early diagnosis. Even after a correct diagnosis has been made, resuscitation efforts may be hampered due to the lack of

necessary ACLS equipment. In this case, precious minutes were wasted searching for a chest tube which was not immediately available. Moreover, because these cases do not ordinarily require preoperative type and screen, the availability of blood products is delayed. Finally, time remains the most critical factor in the management of these cases. Undue delay at any phase of resuscitation may rapidly cause irreversible ischemic damage to major organs, especially the heart and brain. Successful management of a crisis of this magnitude depends on a combination of many fundamental elements: heightened awareness, systematic crisis planning, early diagnosis, effective resuscitation and successful definitive treatment. Thus, it is important to realize that, even though rare, injuries to major blood vessels, heart and lungs do occur during central venous catheter cannulations. These complications occur suddenly and progress rapidly. Therefore, a well-established contingency plan is essential to successfully cope with such crises. The emergency plan should be carefully formulated in advance. It should clearly delineate the specific roles of each member of the resuscitation team. It should be prominently displayed for ready reference in time of need. Because life-threatening emergencies are rare in the ambulatory setting, periodic drills are mandatory to maintain proficiency of team members in performing their respective tasks. Finally, equipment necessary for resuscitation must be properly stocked and maintained in good working condition. During the procedure, vigilance and close monitoring of the patient are needed to detect early warning signs of impending cardiovascular collapse. In this case, the patient received MAC provided by an anesthesiologist. In ambulatory centers, standard monitors mandated by the ASA are the same as required for all operating rooms. These include noninvasive BP, continuous EKG, pulse oximetry and capnography.<sup>5</sup> Similarly, a high index of suspicion is crucial in order to make an early diagnosis. Several risk factors have been reported to be associated with higher incidence of complications during central vein cannulations. These include BMI greater than 30 or less than 20, age older than 77, previous radiotherapy, surgery or catheterizations at the site of cannulation, fractures of the clavicle or first rib, coagulation disorders, inexperienced operator and multiple attempts exceeding three passes.<sup>6,7,8</sup> Even in patients without identifiable risk factors and in the most experienced hands, complications may still occur. It is important to adjust the rate of propofol infusion to achieve stable BP and HR during the procedure so that any unexplained changes in these parameters would immediately raise the suspicion of

an on-going intrathoracic event. The subsequent lack of favorable response to aggressive fluid management and vasopressors confirmed the diagnosis of severe hemorrhage. Finally, when the patient's respirations became shallow and labored with decreased breath sounds on the affected side, the diagnosis of tension hemothorax was immediately made. In this critical situation, coordinated team-work is essential. While the anesthesiologist immediately intubated the trachea, the surgeon placed the chest tube to relieve the tension hemothorax. The resuscitation team leader directed and coordinated drug and volume resuscitation. Emergency thoracotomy is usually required for massive intrathoracic hemorrhage greater than 1.5 L.<sup>9</sup> When over 3 L of blood were evacuated by the chest tube, arrangements were made to immediately transfer the patient to the OR. Finally, the ability of the main OR to provide a cardiothoracic surgery team on short notice contributed to the ultimate successful resuscitation of the patient.

## CONCLUSION

Major intrathoracic exsanguination occurring in an ambulatory setting constitutes one of the most exacting challenges in resuscitation. Ultimate survival was achieved with a timely diagnosis, effective resuscitation, a speedy transfer and successful surgical repair. Successful resuscitation in this case was especially rewarding because the patient recovered completely from this lifethreatening

event.

## References

1. Apfelbaum J. Current Controversies in Adult Outpatient Anesthesia. American Society of Anesthesiologists Annual Meeting Refresher Course Lectures. October 2006, 103 p.1-6.
2. Sznajder JJ, Zveibil FR, Bitterman H, Weiner P, Bursztein S. Central vein catheterization. Failure and complication rates by three percutaneous approaches. Arch Intern Med 1986; 146:259- 61.
3. Eerola R, Kaukinen L, Kaukinen S. Analysis of 13 800 subclavian vein catheterizations. Acta Anaesthesiol Scand 1985; 29:193-7.
4. Capan LM, Miller SM . Trauma and Burns. In Barasch PG, Cullen BF, Stoelting RK, editors. Clinical Anesthesia. 4th ed. Philadelphia: Lippincott Williams & Wilkins; 2001. p.1262.
5. Guidelines for Ambulatory Anesthesia and Monitoring. Park Ridge, IL: American Society of Anesthesiologists; 2003.
6. Mansfield PF, Hohn DC, Fornage BD, Gregurich MA, Ota DM. Complications and failures of subclavian vein catheterization. N Engl J Med 1994; 331: 1735-8.
7. Lefrant JY, Muller L, De La Coussaye JE, et al. Risk factors of failure and immediate complication of subclavian vein catheterization in critically ill patients. Intensive Care Med 2002; 28: 1036-41.
8. Takeyama H, Taniguchi M, Sawai H, et al. Limiting vein puncture to three needle passes in subclavian vein catheterization by the infraclavicular approach. Surg Today 2006; 36: 779-82.
9. Baez BB, Smok JT, Finucane BT, Abrams KJ. Thoracic Trauma. In Kaplan JA, Slinger PD, editors. Thoracic Anesthesia. 3rd ed. Philadelphia: Churchill Livingstone; 2003. p.317.

**Author Information**

**Angela Truong, MD**

Associate Professor, Department of Anesthesiology and Perioperative Medicine, MD Anderson Cancer Center