

# Soft Tissue Lower Limb Trauma

G Darmanin, R Baker, T Cubison

## Citation

G Darmanin, R Baker, T Cubison. *Soft Tissue Lower Limb Trauma*. The Internet Journal of Plastic Surgery. 2009 Volume 7 Number 1.

## Abstract

Soft tissue lower limb trauma ranges from pretibial lacerations in the elderly to limb threatening open fractures with vascular injuries. Patients with these wounds initially present to Emergency Medicine specialists and General Practitioners (GP) and so a broad knowledge of the concepts involved will aid these doctors in correctly assessing injuries and deciding which patients need specialist referral. The factors that influence management of a leg injury are wound site and its relation to the relevant anatomy, the nature of the wound (e.g. crush, laceration, degloving), the energy involved, contamination and tissues involved, the presence of coexisting injuries and patient co morbidities. Advances in the surgical management of high-energy lower limb injuries mean that there are many more patients in the community with salvaged limbs who in the past would have had amputations and prostheses. This means that today's GP is much more likely to encounter patients who have had complex lower limb reconstructive surgery. This review explains the nature and reasons for these procedures and their possible complications.

## INTRODUCTION

Soft tissue lower limb trauma ranges from pretibial lacerations in the elderly to limb threatening open fractures with vascular injuries. Patients with these wounds initially present to Emergency Medicine specialists and General Practitioners (GP) and so a broad knowledge of the concepts involved will aid these doctors in correctly assessing injuries and deciding which patients need specialist referral. The factors that influence management of a leg injury are wound site and its relation to the relevant anatomy, the nature of the wound (e.g. crush, laceration, degloving), the energy involved, contamination and tissues involved, the presence of coexisting injuries and patient co morbidities. Advances in the surgical management of high-energy lower limb injuries mean that there are many more patients in the community with salvaged limbs who in the past would have had amputations and prostheses. This means that today's GP is much more likely to encounter patients who have had complex lower limb reconstructive surgery. This review explains the nature and reasons for these procedures and their possible complications.

## METHODS

Pubmed and Medline were searched using the terms 'leg', 'lower limb', 'trauma' and 'reconstruction' from 1998 onwards. The highest quality articles were selected comprising original papers, reviews, recommendations, and

consensus reports. The studies are all population-based, prospective or retrospective observational reports. The field of reconstructive surgery does not lend itself to randomized controlled trials and much of the evidence inevitably comes from case series and observational reports. In addition, those seminal papers that have substantially influenced practice are referenced.

## ASSESSMENT OF LOWER LIMB INJURIES WHAT IS THE CRUCIAL ANATOMY TO KNOW?

Figure 1

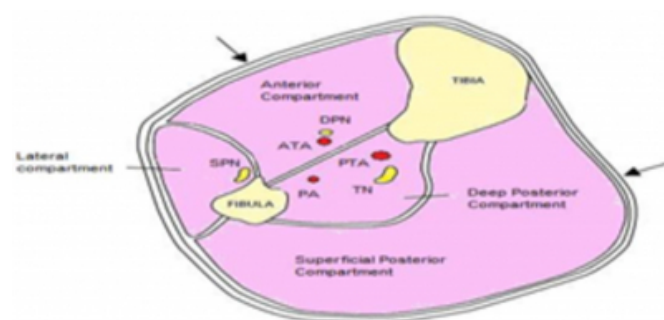

Figure 1 demonstrates a transverse section of the leg which is divided into four compartments containing muscles, nerves and vessels enclosed by bone and fascia. This forms the anatomical basis of compartment syndrome in which the pressure within one of these compartments exceeds the perfusion pressure causing ischemia and necrosis.<sup>1</sup>

Perforating vessels pass from the main arteries between these compartments to the skin influencing fasciotomy incisions and the geometry of fasciocutaneous flaps used to close wounds.<sup>2</sup>

### HOW ARE SOFT TISSUE LOWER LIMB INJURIES ASSESSED?

Clinical assessment of lower limb trauma should follow ATLS protocol –managing more immediately life threatening injuries first.<sup>3</sup> However, if the leg is the source of life-threatening haemorrhage then this should be treated immediately. A retrospective review of 165 patients with severe extremity injuries during the current Iraq conflict showed that pre-hospital tourniquet use was associated with reduced haemorrhage and mortality and no adverse consequences.<sup>4</sup>

The history should concentrate on mechanism of injury (eg. laceration, crush, degloving or penetrating) and energy (high/low), which are determinants of the extent of tissue injury. Co-morbidities, especially those affecting surgery (e.g. peripheral vascular disease) should be noted together with the patient's pre-injury ambulatory status. Clinical examination of the lower limbs should assess deformity, colour, fractures (location, type,) compartment syndrome, movement, sensation (particularly over the sole of foot), wounds (size, soft tissue damage, skin viability) and the vascular status. Pulses should be compared with those of the non-injured limb. In case impalpable, hand-held Doppler ultrasound is used. One should also ensure that patients are warm and well-filled to avoid misleading assessment of sensation in a cold, under-perfused limb.

Most lower limb trauma patients require radiographs. If a vascular injury is suspected then either conventional arteriography or computed tomographic angiography (CTA) may help to localise the lesion. A 52 patient retrospective comparison of these techniques, found CTA to be as accurate, with the benefits of non-invasiveness and better availability.<sup>5</sup> Vascular imaging is useful prior to microsurgical reconstruction if the integrity of vessels to be used in anastomoses is doubted.

### HOW CAN WE RECOGNISE COMPARTMENT SYNDROME?

Compartment syndrome commonly follows crush injuries particularly but not exclusively if there is a fracture (open or closed) but other mechanisms such as electrical injuries can cause it too.<sup>6</sup> Clinical features are severe pain unresponsive to analgesia and out of proportion to the injury, decreased

sensation in the distribution of the nerve running through the affected compartment (for example, the first dorsal web space in the case of the anterior compartment), tenderness of the affected compartment and pain on passive stretching. The diagnosis is a clinical one but in difficult cases can be aided by measuring (all) compartmental pressures with 30mmHg the critical threshold.<sup>7</sup> 'Pallor, pulselessness and paralysis' are very/too late signs.<sup>8</sup> The limb should be placed at heart level, the patient resuscitated and emergency fasciotomies performed in which the inelastic muscle fascia is incised thus relieving the compartmental pressures. Untreated compartment syndrome leads to replacement of muscle with scar tissue followed by fibrous contracture and neuropathy of involved nerves and a permanently disabled limb.<sup>8</sup>

### ARE THERE CLINICAL TOOLS THAT CAN HELP US ASSESS THE SEVERITY OF INJURY TO A LOWER LIMB?

Several tools allow objective grading of lower limb injuries in terms of prognosis and limb salvageability that are useful for research and audit purposes although they shouldn't determine management decisions in individual patients. These include the Mangled Extremity Severity Score (MESS), Limb Salvage Index (LSI) and the Predictive Salvage Index (PSI).<sup>11,9,10</sup> However, in a prospective cohort study of 407 patients these systems were not found to be predictive of functional outcome after limb reconstruction.<sup>12</sup>

### WHICH PATIENTS AND INJURIES NEED TO BE REFERRED TO SPECIALISTS?

All patients with fractures, severe injuries or with obvious tendon, nerve or vascular deficits need to be referred. Those with penetrating injuries need referral if vital structures may have been damaged. Crush and degloving injuries need referral as the extent of the damage is often greater than is first apparent. Patients with large areas of skin loss need referral for skin grafting as do elderly patients with large pretibial lacerations. Those patients with straightforward wounds that can be expected to heal with or without direct closure in two to four weeks do not need referral.

### THE MANAGEMENT OF LOWER LIMB INJURIES WHAT ARE THE PRINCIPLES OF MANAGEMENT OF LOWER LIMB INJURIES?

Principles of lower limb wound management owe much to the experience of surgeons in the two World Wars.<sup>13</sup> All significant injuries require early and aggressive debridement, antisepsis, fracture management (if relevant) and antibiotics.

Minor wounds are cleaned with saline and an antiseptic solution (eg. chlorhexidine) and sutured if needed. Larger wounds require radical debridement of all non-viable tissues including bone, with amputation in extreme cases. Such injuries often require multiple debridements as tissues may take time to 'declare' their non-viability and could potentially endanger reconstructive procedures.<sup>14,17</sup>

Preservation of structures such as nerves is also important (even if of doubtful viability) as they can have an impact on definitive reconstruction. Fracture fixation usually precedes soft tissue closure to avoid damaging reconstructions.<sup>15</sup>

In the context of open tibial fractures, Godina et al (1986) first championed early definitive wound closure to prevent osteomyelitis and other complications.<sup>16</sup> A retrospective review showed that delaying soft tissue cover over 72 hours resulting in higher complication rates.<sup>15,16</sup> This influenced the publishing of joint guidelines by the British Association of Orthopaedic Surgeons and British Association of Plastic Surgeons in 1997 which emphasised early debridement and soft tissue cover.<sup>18</sup> However, these guidelines have been comprehensively revised this year and now the focus is much more on management of these injuries in specialist centres by multidisciplinary teams of orthopaedic and plastic surgeons with specific expertise in managing complex lower limb trauma.<sup>19</sup>

### HOW ARE PRETIBIAL LACERATIONS MANAGED?

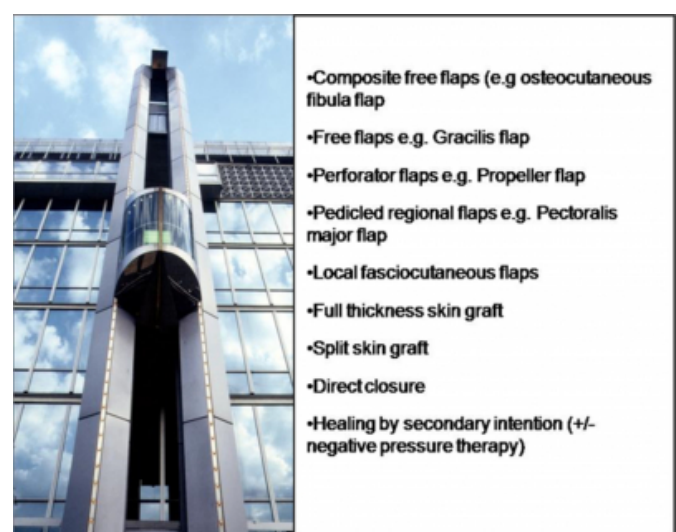
Pretibial lacerations and hematomas predominantly present in the elderly female population with fragile skin, often as a result of mild trauma. Most of these injuries can be managed with standard wound care and dressings but a minority have large flaps of devitalised skin. These wounds will take many months to heal without surgery and therefore debridement and split skin grafting should be considered. Skin graft take is not significantly improved by immobilisation and may lead to other complications in this patient group.<sup>20,33</sup> The mortality of this particular subset of patients population is 11% at six months after injury and is associated with escalation of social care requirements.<sup>32</sup>

How are more complex lower limb soft tissue injuries reconstructed? (The concept of the reconstructive elevator.)

Reconstruction ensues after the wound is free of contamination and necrotic tissue. This may be during the first procedure or may follow after serial debridements or prolonged negative pressure therapy. The concept of the reconstructive elevator is used (figure 2). This is a

continuum of procedures ranging from the simplest (allowing the wound to heal by secondary intention with or without negative pressure therapy) to the most complex (free flap transplantation). As a general principle the procedure with the greatest chance of success and lowest risk is chosen, often being one of the simpler techniques.<sup>22</sup> The more complex procedures are required in larger wounds with exposed bone, fixation devices or poorly vascularised tissues like tendons, where surfaces are unable to support a skin graft.<sup>23</sup> These defects often require free tissue transfer usually in the form of muscle flaps although a 177 patient prospective comparison study of free muscle and free fasciocutaneous flaps showed similar functional outcomes.<sup>24</sup> However, local (to the defect) perforator-based fasciocutaneous flaps are frequently preferred because they are technically easier with less likelihood of total flap loss (since there are no microsurgical anastomoses) and can give excellent cosmetic results especially when raised as rotating (on a perforator vessel) 'propeller' flaps.<sup>25,26</sup>

**Figure 2**



### NEGATIVE PRESSURE THERAPY (NPT)

NPT is a relatively recent advancement in wound management. It reduces wound oedema, bacterial contamination and stimulates granulation tissue formation. Over time, it allows coverage of exposed tendon, bone and implants with less complex procedures. It also extends the time that surgeons can safely wait prior to definitive closure.<sup>27</sup> NPT prior to definitive reconstruction in the sub-acute phase (8 to 42 days post-injury) reduced overall complication rates in open tibial fractures in a 105 patient retrospective study.<sup>27</sup> A broad review of the literature found that clinical evidence justified the application of NPT in soft

tissue lower limb trauma.<sup>28</sup>

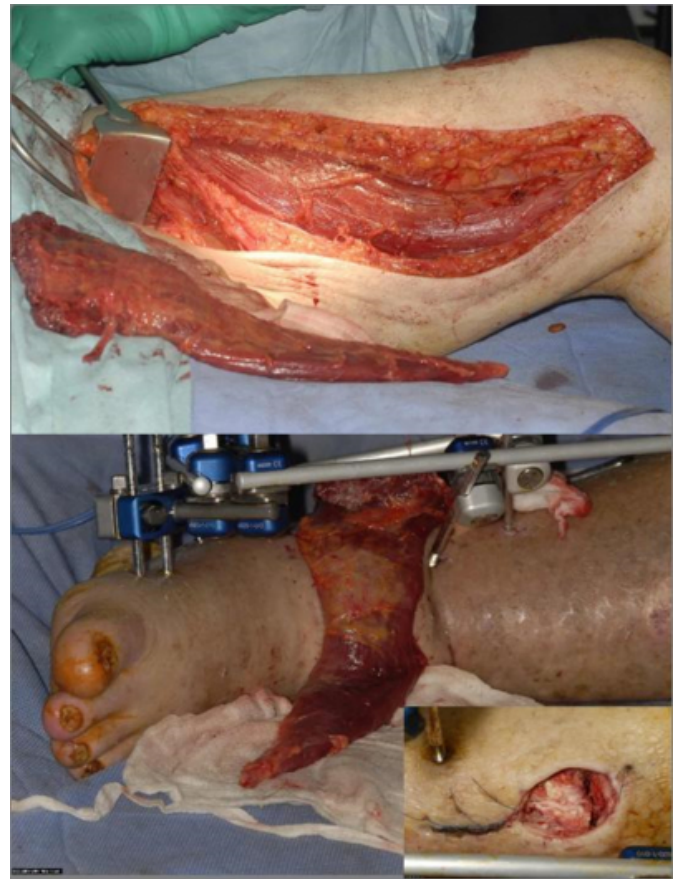
### CURRENT CONCEPTS AND ISSUES

Free flaps are important in the reconstruction of three-dimensional defects (which might include bone). Vascularised bone free flaps commonly use the fibula and are even being performed as part of a single procedure post-injury.<sup>34</sup> In a murine model of periosteally-stripped open tibial fractures, muscle flaps were shown to be superior to fasciocutaneous flaps with faster bone bridging, 50% more bone content and a 3-fold stronger union of the fractures.<sup>29</sup> Expertise in microsurgery has improved to an extent that a meta-analysis of observational studies showed salvaged legs to give functional outcomes equivalent to primary amputation.<sup>30</sup> A retrospective review of 545 patients showed salvaged legs are associated with considerably lower lifetime financial costs.<sup>31</sup> Not all limbs are salvageable in particular, those with prolonged 'warm ischemia' times. Technological advances such as microprocessor-controlled prosthetic knees and energy-storing/return prosthetic feet are improving the utility of prostheses for amputees.<sup>32,35,36</sup> Progress in cybernetics means that osseo-integrated prostheses may one day be truly bionic.<sup>37</sup>

### CONCLUSION

Lower extremity soft-tissue trauma ranges from minor injuries to severe ones with associated fractures. Accurate assessment of the wound and limb viability is crucial. Debridement (and negative pressure therapy) remains the mainstay of management followed by reconstruction with one of a range of procedures of increasing complexity.

**Figure 3**



### SUMMARY POINTS

Lower limb injuries should be assessed according to ATLS protocol.

The compartmental anatomy of the leg is the basis of compartment syndrome and determines the geometry of fasciocutaneous flaps

Wounds are managed by debridement followed by reconstruction according to the reconstructive elevator

Negative pressure therapy can act as a temporising measure prior to reconstruction

Procedures range from split skin grafting to local fasciocutaneous flaps and microsurgical reconstruction with free flaps

Primary amputation is sometimes the only option and prostheses are becoming technologically sophisticated

### TIPS FOR THE NON-SPECIALIST

Refer wounds that cannot be closed by direct suture, penetrate the fascia, are high energy or have associated neurovascular injuries or fractures.

Soft tissue lower limb injuries with fractures need irrigation and debridement as a matter of urgency

Patients with large pretibial lacerations or hematomas may need debridement and split skin grafting

### ONGOING RESEARCH

Extending the application of negative pressure therapy to increase the salvageability of limbs

Techniques of reconstruction including fasciocutaneous flaps versus free flaps and one-stage reconstruction

Development of prostheses with microprocessors, energy storing/return and osseointegration capabilities

### COMPLICATIONS OF NEGATIVE PRESSURE THERAPY

Loss of suction – reinforce the adhesive airtight dressing

Pain – reducing the suction pressure (normally about 125mmHg) to 75mmHg and using continuous rather than intermittent suction.

Dermatitis at the wound margin - use of a hydrocolloid dressing such as Duoderm® along the edges can help prevent this

Infection and bleeding – all but the very minor cases will require discussion with the relevant specialist

### References

1. Owen CA, Mubarak SJ, Hargens AR, et al. Intramuscular pressures with limb compression clarification of the pathogenesis of the drug-induced muscle-compartment syndrome. *N Engl J Med* 1979;300(21):1169-72.
2. Schaverien M, Saint-Cyr M. Perforators of the lower leg: analysis of perforator locations and clinical application for pedicled perforator flaps. *Plast Reconstr Surg* 2008;122(1):161-70.
3. Advanced Trauma Life Support® for Doctors, Student Course Manual. American College of Surgeons Committee on Trauma. 2004, 7th edition, American College of Surgeons, Chicago.
4. Beekley AC, Sebesta JA, Blackburn LH, Herbert GS, Kauvar DS, Baer DG, Walters TJ, Mullenix PS, Holcomb JB; 31st Combat Support Hospital Research Group. Prehospital tourniquet use in Operation Iraqi Freedom: effect on hemorrhage control and outcomes. *J Trauma* 2008;64:S28-37.
5. Peng PD, Spain DA, Tataria M, Hellinger JC, Rubin GD, Brundage SI. CT angiography effectively evaluates extremity vascular trauma. *Am Surg* 2008;74(2):103-7.
6. Köstler W, Strohm PC, Südkamp NP. Acute compartment syndrome of the limb. *Injury* 2004 Dec;35(12):1221-7.
7. Allen M, Stirling A, Crawshaw C, Barnes M. Intracompartmental pressure monitoring of leg injuries. An aid to management. *J Bone Joint Surg* 1985;67Br:53-7.
8. Mubarak S, Hargens A. Acute compartment syndromes. *Surg Clin North Am* 1983;63:539-65.
9. Russell WL, Sailors DM, Whittle TB, Fisher DF Jr, Burns RP. Limb salvage versus traumatic amputation. A decision based on a seven-part predictive index. *Ann Surg* 1991;213:473-81.
10. Howe HR Jr, Poole GV, Hansen KJ, Clark T, Plonk GW, Koman LA, Pennell, TC. Salvage of lower extremities following combined orthopedic and vascular trauma. A predictive salvage index. *Am Surg* 1987;53:205-8.
11. Helfet DL, Howey T, Sanders R, Johansen K. Limb salvage versus amputation. Preliminary results of the Mangled Extremity Severity Score. *Clin Orthop Relat Res* 1990;(256):80-6.
12. Ly TV, Trivison TG, Castillo RC, Bosse MJ, MacKenzie EJ; LEAP Study Group. Ability of lower-extremity injury severity scores to predict functional outcome after limb salvage. *J Bone Joint Surg Am* 2008;90(8):1738-43.
13. Helling TS, Daon E. In Flanders fields: the Great War, Antoine Depage, and the resurgence of débridement. *Ann Surg* 1998;228(2):173-81.
14. Karanas YL, Nigriny J, Chang J. The timing of microsurgical reconstruction in lower extremity trauma. *Microsurgery* 2008, 28(8):632-4.
15. Gopal S, Majumder S, Batchelor AG, Knight SL, De Boer P, Smith RM. Fix and flap: the radical orthopaedic and plastic treatment of severe open fractures of the tibia. *J Bone Joint Surg Br* 2000;82(7):959-66.
16. Godina M. Early microsurgical reconstruction of complex trauma of the extremities. *Plast Reconstr Surg* 1986;78(3):285-92.
17. Steiert AE, Gohritz A, Schreiber TC, Krettek C, Vogt PM. Delayed flap coverage of open extremity fractures after previous vacuum-assisted closure (negative pressure therapy - worse or worth?) *J Plast Reconstr Aesthet Surg* 2009;62(5):675-83.
18. Court-Brown CM, Cross AT, Hahn DM, Marsh DR, Willett K, Quaba AA, WF, Small J, Watson JS. BAPS/BOA Working Party on The Management of Open Tibial Fractures. British Orthopaedic Association, London; 1997.
19. Nanchahal J, Nayagam D, Khan U, Moran C, Barrett S, Sanderson F, Pallister I. Standards for the management of open fractures of the lower limb. RSM Press, London; 2009.
20. Wood SH, Lees VC. A prospective investigation of the healing of grafted pretibial wounds with early and late mobilisation. *Br J Plast Surg* 1994 ;47(2):127-31.
21. Rees LS, Chapman T, Yarrow J, Wharton S. Long term outcomes following pretibial injury: mortality and effects on social care. *Injury* 2008;39(7):781-5.
22. Reddy V, Stevenson TR. MOC-PS(SM) CME article: Lower extremity reconstruction. *Plast Reconstr Surg* 2008;121(4 Suppl):1-7.
23. Hallock GG. Utility of both muscle and fascia flaps in severe lower extremity trauma. *J Trauma* 2000;48(5):913-7.
24. Yazar S, Lin CH, Lin YT, Ulusal AE, Wei FC. Outcome comparison between free muscle and free fasciocutaneous flaps for reconstruction of distal third and ankle traumatic open tibial fractures. *Plast Reconstr Surg* 2006;117(7):2468-75.
25. Hollier L, Sharma S, Babigumira E, Klebuc M. Versatility of the sural fasciocutaneous flap in the coverage of lower extremity wounds. *Plast Reconstr Surg* 2002;110(7):1673-9.
26. Erdmann MW, Court-Brown CM, Quaba AA. A five year review of islanded distally based fasciocutaneous flaps on the lower limb. *Br J Plast Surg* 1997;50(6):421-7.
27. Rinker B, Amspacher JC, Wilson PC, Vasconez HC.



Subatmospheric pressure dressing as a bridge to free tissue transfer in the treatment of open tibia fractures. *Plast Reconstr Surg.* 2008;121(5):1664-73.

28. Kanakaris NK, Thanasis C, Keramaris N, Kontakis G, Granick MS, Giannoudis PV. The efficacy of negative pressure wound therapy in the management of lower extremity trauma: Review of clinical evidence. *Int. J. Care Injured* 2007;38S:S8—S17.

29. Harry L E, Sandison A., Paleolog EM, Hansen U, Pearse MF, Nanchahal J. Comparison of the healing of open tibial fractures covered with either muscle or fasciocutaneous tissue in a murine model. *J Orthop Res.* 2008; 26(9):1238-44.

30. Busse JW, Jacobs CL, Swiontkowski MF, Bosse MJ, Bhandari M; Evidence-Based Orthopaedic Trauma Working Group. *J Orthop Trauma.* Complex limb salvage or early amputation for severe lower-limb injury: a meta-analysis of observational studies. 2007;21(1):70-6.

31. MacKenzie EJ, Jones AS, Bosse MJ, Castillo RC, Pollak AN, Webb LX, Swiontkowski MF, Kellam JF, Smith DG, Sanders RW, Jones AL, Starr AJ, McAndrew MP, Patterson BM, Burgess AR. Health-care costs associated with amputation or reconstruction of a limb-threatening injury. *J Bone Joint Surg Am.* 2007;89(8):1685-92.

32. Collins DM, Karmarkar A, Relich R, Pasquina PF,

Cooper RA. Review of research on prosthetic devices for lower extremity amputation. *Crit Rev Biomed Eng.* 2006;34(5):379-438.

33. Budny PG, Lavelle J, Regan PJ, Roberts AH. Pretibial injuries in the elderly: a prospective trial of early mobilisation versus bed rest following surgical treatment. *Br J Plast Surg.* 1993;46(7):594-8.

34. Yazar S, Lin CH, Wei FC. One-stage reconstruction of composite bone and soft-tissue defects in traumatic lower extremities. *Plast Reconstr Surg.* 2004;114(6):1457-66.

35. Seymour R, Engbretson B, Kott K, Ordway N, Brooks G, Crannell J, Hickernell E, Wheeler K. Comparison between the C-leg microprocessor-controlled prosthetic knee and non-microprocessor control prosthetic knees: a preliminary study of energy expenditure, obstacle course performance, and quality of life survey. *Prosthet Orthot Int.* 2007;31(1):51-61.

36. Graham LE, Datta D, Heller B, Howitt J. A comparative study of oxygen consumption for conventional and energy-storing prosthetic feet in transfemoral amputees. *Clin Rehabil.* 2008;22(10-11):896-901.

37. Pylatiuk C, Döderlein L. "Bionic" arm prostheses. State of the art in research and development. *Orthopade.* 2006;35(11):1169-70, 1172-5.

**Author Information**

**Geraldine Darmanin**

Core Surgical Trainee, Charing Cross Hospital Imperial College NHS Foundation Trust

**Richard Baker**

Specialty Training Registrar Plastic Surgery, Queen Victoria Hospital NHS Foundation Trust

**Tania Cubison**

Consultant Plastic Surgeon, Queen Victoria Hospital NHS Foundation Trust