

Intraventricular Neurocysticercosis In HIV Positive Patients

H Foyaca-Sibat, L Ibañez-Valdés

Citation

H Foyaca-Sibat, L Ibañez-Valdés. *Intraventricular Neurocysticercosis In HIV Positive Patients*. The Internet Journal of Neurology. 2002 Volume 2 Number 1.

Abstract

English:

Introduction. Currently neurocysticercosis (NCC) is the most common parasitic infection of the nervous system causing epileptic attacks, and signs of intracranial hypertension by obstruction of the cerebrospinal fluid circulation in most of the patients. Some patients with intraventricular neurocysticercosis (INCC) qualify for medical and surgical treatment, usually ventriculo-peritoneal shunt (VPS), and others only for one of them but to determine who is still a controversial point.

Patients and Method. Two groups of nine patients each were included for anti-parasitic treatment with and without surgical approach.

Results. Patients with multi-viable parasites showed better outcome and less complication than patients with an associated VPS.

Conclusion. For HIV patients with INCC characterized by multi-cysts on CT Scan anti-parasitic treatment alone rather than VPS is the treatment of choice because of the high frequency of obstruction in the derivation systems by the parasites. Some consideration regarding immunology, pathophysiology and management for those patients are discussed.

Spanish:

Introducción: En el momento actual la neurocysticercosis (NCC) es la enfermedad parasitaria mas comun del sistema nervioso, causando epilepsia, y signos de hipertension endocraniana secundarios a la obstrucción de la libre circulación del líquido cefalorraquídeo en la mayoría de los enfermos. La decisión de someter a enfermos con INCC a tratamiento neuroquirúrgico es todavía un dilemma en estudio.

Material y Método: Se estudiaron dos grupos de nueve enfermos cada uno considerando su respuesta al tratamiento medico con o sin derivación ventricular-peritoneal.

Resultados: El grupo de paciente que recibió solo tratamiento anti-parasitario mostró mejores resultados.

Conclusion: Se recomienda el tratamiento anti-parasitario sin manipulacion neuroquirurgica (VPD) para aquellos pacientes que presentan varios cysticercos viables dentro del sistema ventricular, debido a la considerable frecuencia en que el sistema derivativo puede ser obstruido por los cysticercus.

INTRODUCTION

Little is known about the nature of Intraventricular Neurocysticercosis (INCC) in Sub-Saharan Africa. while results from other endemic areas for NCC based INCC registers have not been reported, and there is no published information on INCC patients from rural areas, however more than sixty million of peoples all over the world are infected with the larvae form of *Taenia Solium* (TS) and in places such as the former Transkei (Region D and E of

Eastern Cape Province) in South Africa, the incidence and prevalence of this parasitic disease continue increasing gradually¹

NCC is an infection of central nervous system (CNS) caused by the larval stage (*Cysticercus cellulosae*) of the pig tapeworm TS. The adult stage is a parasite exclusively of humans, and they are the most common helminth to produce CNS infection in human beings. The occurrence of epilepsy, neuropsychiatry manifestations, dermatological problems,

ocular disturbances, and/or raised intracranial pressure in a person living in or visiting a region where taeniasis is endemic or even in one living in close contact with people who have taeniasis should suggest a diagnosis of cysticercosis; patients with NCC may remain asymptomatic for months to years and commonly a diagnosis is made incidentally when neuroimaging is performed.

Symptoms and signs are related both to the parasite which can show a different molecular biology expression from one place to another and to the inflammatory-immunological response of the host. Diagnostic criteria for NCC have been well-established recently ², although there is controversial points, based on these studies, categories of Absolute criteria is acceptable when the histological demonstration of the parasite from biopsy of the brain or spinal cord lesion is made, or in case of cystic lesion showing the scolex on CT or MRI, or when sub retinal parasite is visualized by funduscopy examination, others less acceptable criteria such as: Major, Minor or Epidemiological criteria can be reviewed in the Del Bruto's article.²

The International League Against Epilepsy, established that cysticercosis is the single most common cause of acquired epilepsy in the developing world, where prevalence rates of epilepsy are twice those of developed countries ³ Nearly all these infected peoples live in less-developed countries and the probable link with HIV/AIDS is that chronic parasitic infection down regulates the cellular immune response that is needed to prevent infection by the immunodeficiency virus and Mycobacterium tuberculosis ⁴ In South Africa , the MRC has estimated that HIV/AIDS accounted for 40% of death in adults aged 15-49 in 2000 , and will probably kill between 5 and 7 million people by 2010⁵ Neurocysticercosis is commonly associated to HIV/AIDS, TB and Schistosomiasis in some developing countries and is well known that co-infection by pathogens that elicit opposing immune response, particularly helminths versus HIV and TB can influence the infection dynamic, progression, and immunoprophylaxis of the disease they cause⁵ . Disease model in mice have been manipulated at molecular and cellular level, in order to demonstrate priming of immune response by contact with viral, bacterial and parasitic organism. The respective antigenic exposures influence differentiation of T helper1 (Th1) or Th2 cell as well as the associated cytokine profiles and TH1/Th 2 ⁶

The parasite inhibit complement activation, lymphocyte activation, and cytokine production and remains viable

longer in HIV patients,¹ The above-mentioned immunological mechanisms are present in NCC spite of its location on the CNS, excepting for the subarachnoid NCC in which the scolex of the parasite is destroyed by hydrolytic degeneration. We report the neurological outcome in some HIV patients with INCC after VPS for alleviation of intracranial hypertension due to obstruction of the CFS circulation by the parasites. No previous report concerning neurosurgical approach of INCC in HIV patients has been published up to date.

PATIENTS AND METHOD

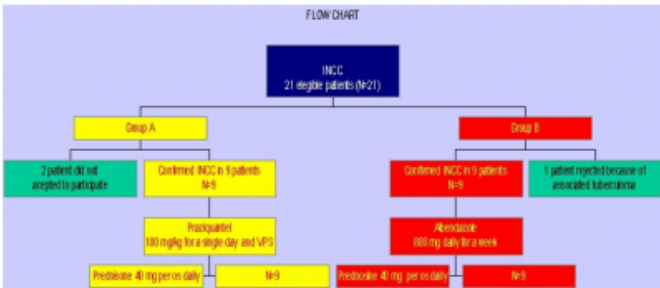
Umtata General Hospital (UGH) is a 360-bed hospital that offers services for tertiary neurological care to 6.4 million peoples. All patients admitted to medical wards at Umtata General Hospital with a likely diagnosis of NCC were examined and investigated looking for INCC. Twenty-one patients fulfilling the clinical and radiographic criteria of INCC were identified prospectively for the study among patients referred to neurology during five years period. Most of those patients presented with an associated HIV seropositive, ,and pulmonary tuberculosis (PTB).

After the CT Scan of the brain, eligible patients (n=18) had clinical signs of raised intracranial pressure and dilatation of the ventricular system. An experienced neurologist evaluated all patients, none had no previous history of any other neurological disease apart from epilepsy and those with concomitant disorders such: metabolic disorders, cerebrovascular diseases, meningoencephalitis, and head injuries were excluded. Nine patients were treated randomly with Praziquantel (100 mg/kg) and VPS (group A) and other nine (group B) with albendazole (800 mg daily during 7 days), in both series 40 mg of prednisone orally were given. (See the flow chart). No patients receiving treatment for any other disease requiring immunomodulatory agents within the past six months before admission were admitted to the study.

Other exclusion criteria included alternative cause for intracranial calcifications or suspicion of tuberculomas, pyogenic brain abscesses, mycotic granulomas, and primary or brain's metastases Apart from antiepileptic drugs, steroids medications and antiparasite treatment, other concomitant treatment was prohibited for patient while participating in the study. Approximately once a fortnight patients, and where it was impossible to see the patients themselves, the proformas / notes were assessed by us. Where patients had indeed had an INCC their clinical findings and where available investigation data were entered onto the register.

Because for some patients the closest CT scanner is a three-hour drive away and transport is seldom if ever available, in some patients INCC type was assessed using clinical impression and confirmed by CT Scan later. For all patients screening for retroviral infection were done and for those with result positive, CD 4 count was also performed. No for all HIV-positive patients Viral Load was available and in only six patients was done.

Figure 1



RESULTS

Approximately 4-8 patients with NCC are admitted to per month but results of the first 21 consecutive patients with INCC entered onto the register. Of the 18 finally included in this investigation, 8 were male and 10 female and the average age was 55 (13-73). 12% were confirmed to have associated NCC in different parasitic stages and all of them presented with epileptic attacks, 78% INCC and none had subarachnoid NCC (racemose). In 8 % it was impossible to assess other features clinically. The average time from VPS and its complications was 13 days (0-164).

More than half of patients (67 %) were HIV positive but CD 4 Count was no less than 250 cells/mm3 and viral load less than 55 000 copies/ml. Of those with confirmed retroviral infection in group A, 78 % developed complications after VPS and in most of them due to obstruction of the ventricular-peritoneal catheter (Table I). Two patients from group A died and the post-mortem examination confirmed viable intraventricular parasites at the fourth ventricle (similar to Figure 1), hydrocephalus, obstruction of the derivation system, mild tonsillar herniation (one case) and severe inflammatory reaction of the ependymal tissue, ischemic changes with microhemorrhages on the brain stem.

Group B (treated with albendazole) shows a better response to the anti-parasitic drugs; only two patients complained of headache after treatment, evidence of viable cysticercus on the ventricular system were found in none one, and fatal results were found neither. In patients with previous history

of PTB unremarkable outcome differences were detected but no discussed in this article. Blood results (Elisa test) were available for 86% of patients but many contradictories finding are found therefore those results were not taken for statistical analysis.

Figure 2

Table 1

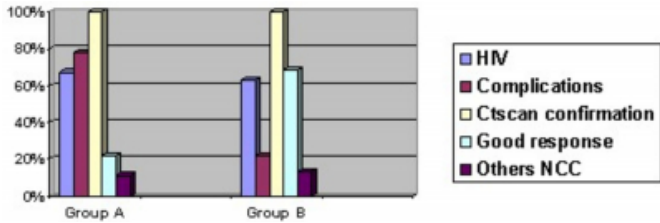


Figure 3

Figure 1: (courtesy by Salfelder)

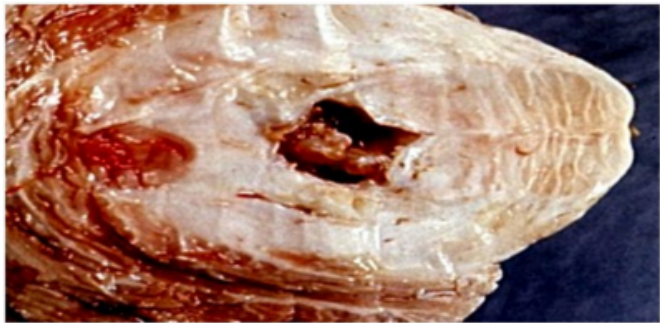
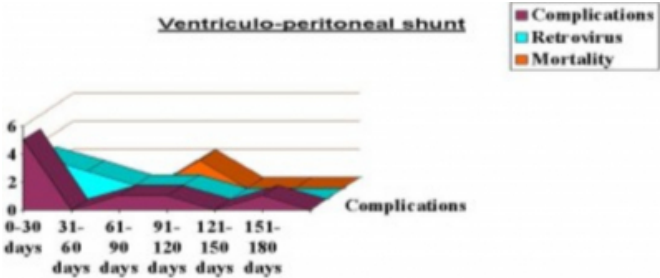


Figure 4

Table 2



DISCUSSION

Poverty, underdevelopment, poor personal hygiene or improper hygiene of foods, and living conditions allowing pig's access to human faeces, are the most important co-factor in epidemiological of NCC. In densely populated informal settlements in South Africa, co-infection by HIV, Mycobacterium tuberculosis, and TS is very important because this parasite is common. Infection by TS can accelerate HIV progression to AIDS because this parasite modify the immune system of the host polarizing this

immune response to Th2, suppressing interleukin 2, 5 and 6, and TH1 cytokine. NeuroAIDS depends on a number of factors, such as degree of immunosuppression, and the molecular biology of the viral strain, particularly its neurovirulence₇

NCC constitutes a serious health problem in Latin America, India, and China and its becoming more frequent in Europe and North America, where NCC was exceptionally rare 10 years ago. NCC is localized in well demarked region of Eastern Cape province and part of KwaZulu Natal in South Africa where access to employment, cash income, safe and clean water, proper toilet facilities, proper refuse disposal, electricity, telecommunication and medical services are extremely low; that limited access to primary health care system among other factors are perpetuating its dissemination. Because NCC is the commonest cause of new-onset seizure the incidence of epileptic seizures in the former Transkei is three times more elevated than in developed countries without NCC. *Cysticercus* in our region, does not invade the eyes as often as India; and skeletal muscles or the subcutaneous tissue are less affected than Asian countries (China). Multiple intracranial lesions are much less common in India than in Latin American countries₈ or our region. 1 In USA, is becoming more common among immigrants from endemic areas, and around 1000 news cases have been reported each year. Seroprevalence of NCC infection between 4.9 % and 24 % of the entire population have been reported in some endemic areas in Mexico, Bolivia, Peru, Ecuador and Guatemala₉, but because the number of seropositive patients represent only the 40 % of cases diagnosed by Absolute criteria the prevalence in those country should be higher.

Pathology, immunology, and pathogenesis are one of the thirty different species of cestodes affecting the human beings. TS require two hosts to complete its life cycle. In the first stage, the human host ingest diseased (measly) pork containing viable cysticerci, after ingestion, the scolex evaginates and attaches to small intestine using its 4 suckers (teaniasis), the tapeworm mature over 3 to 4 months after the infection achieving a length of 2-7 meters, 700-1200 hermaphrodites proglottids developed from the base of scolex containing more than 50 000 eggs each which are shed passive and intermittently in the stool two or three times a week, it is why stool test are usually negative for cysticercosis and because to differentiate eggs of TS from eggs of other taenias is not certain. Pigs become infected by

ingesting the ova or mature proglottids and in the human small intestines the larvae hatch and using its double crown of 25 hooklets, erode the intestine mucosa and enter the bloodstream where the parasites are constantly exposed to the immune system of the host (pre-critical stage), HIV can infect monocytes easily however if the parasites died at this stage its may prevent the dominance of Th2 immune response, reducing immune activation and can also alleviate cell anergy, facilitating immunosuppression effect by HIV. If the parasite remains alive after this immunological attack then they will reach the skeletal muscles, eyes and central nervous system; on those places the parasite could be found in different stages such as:

1. -Vesicular stage: characterized by cysts of 4-30 mm in diameter (or even bigger), the cyst wall is thin (0.4-0.8 mm thick) isodense with the nervous tissue on CT Scan, the cyst fluid is isodense with CSF and there is minimum inflammatory reaction around the cyst because the parasite elaborate prostaglandins and low-molecular-weight molecules which decrease perilesional inflammation, also secrete proteases that can degrade interleukin (IL)-2 and immunoglobulin, in this stage there is not focal edema; the size of the cyst is related with the resistance of surrounding tissue, i.e. on the skeletal muscle the lesions are almost similar in size although smaller in the musculature of the limbs(1-2 cm in diameter) compared with muscular tissue at the trunk(2-3 cm in diameter) and in the CNS cysts are bigger on the subarachnoid space compared with intracerebral tissue where there is a more mechanical resistance.

2. -Critical stage: long time after primary CNS invasion and due to a successful persistent immunology attack against the cysticercus, due to anti-cysticidal drugs or due to other reasons (sickness of the parasite or infected by virus?), in some people then the parasite serine protease secretion increase compared with the previous stage, and decrease the elaboration of prostaglandin by the parasite therefore inflammatory perilesional response is more evident. In spite of the variety of ways used by the parasite to modify host immune response, at this stage, their mechanism of excretory/secretory product fail and its anti-immune properties are weaker, paradoxically these pathologic changes on the parasite membrane and the surrounding tissue (without remarkable edema) are observed, its may be seen in HIV patients₁₀(with CD4 count > 350 cells/mm³ and viral load rises <55,000 copies /ml or even in window period), those patients do not qualify for anti-retroviral

therapy(ART).

At this stage electrophysiological changes suggesting sub-clinical peripheral neuropathy can be seen, those patients will develop sensory distal symmetrical polyneuropathy later or will manifest peripheral neuropathy as side effect of ART without co-infection like CMV or MAC. We have hypothesized that at this stage there is an increased microglial activation with an associated oligodendrocyte and astroglial changes with a subsequent damage of the

EPIDEMIOLOGY

Poverty, underdevelopment, poor personal hygiene or improper hygiene of foods, and living conditions allowing pig's access to human faeces, are the most important co-factor in epidemiological of NCC. In densely populated informal settlements in South Africa, co-infection by HIV, *Mycobacterium tuberculosis*, and TS is very important because this parasite is common. Infection by TS can accelerate HIV progression to AIDS because this parasite modify the immune system of the host polarizing this immune response to Th2, suppressing interleukin 2, 5 and 6, and TH1 cytokine. NeuroAIDS depends on a number of factors, such as degree of immunosuppression, and the molecular biology of the viral strain, particularly its neurovirulence⁷

NCC constitutes a serious health problem in Latin America, India, and China and its becoming more frequent in Europe and North America, where NCC was exceptionally rare 10 years ago. NCC is axonal functions and blood-brain barrier leading to pathological concentration of macrophage histocompatibility complex, Interleukin-1 and -6, and tumor necrosis factor alpha among other unknown neuro-toxins causing CNS and peripheral nerve disorders. Because HIV does not directly infect neurons, the neuronal injury and/or neuronal death should be related with the interaction of the parasite with chemokine receptors on neurons and astroglia, and the increased concentration of proinflammatory molecules from meningeal macrophages, choroids plexus macrophages, perivascular macrophages, phagocytic macrophages, multinucleated giant cells, and activated microglia-according to the number and location of the cysticercus's.

This stage can provoke a collapse of the immune system stimulating intracellular retroviral replication. The above-mentioned information also serve to support our criteria suggesting medical treatment (albendazole)for multiple viable cysticercus's in INCC at this stage rather to add more

immunological disturbances secondary to surgical procedures even more due to releasing antigens when the parasite is dying, and also due to more damage of the nervous system due to obstruction of the derivation system. 3. - Colloid Stages: characterized by increased cysts fluids density and perilesional edema, in this stage seizure disorders are common and the previous disorders may be aggravated therefore similar considerations should be taken into account regarding any surgical intervention.4.- Granular stage: the parasite is death, cyst is collapse or fibrotic, edema can be present. 5. - Calcify stage: 2- 10 mm-calcified lesion with perilesional edema (still "active" lesions) or without edema (inactive lesions), and epileptic seizures that are also frequents. As before-mentioned all along those stages the parasite secrete, excrete or shed factors which down regulate both T cell proliferation and cytokine production ¹¹.

Increased IgG, interleukin-2-5 in serum and interleukin 5-6 plus neopterin in the CSF has been reported.⁹ Epidemiological and clinical finding suggest that individual immunological responses to cysticercosis might have a genetic basis.⁹ There is also an association with epilepsy in neurocysticercosis with HLA type I ₁₂ therefore HLA differences might also determine the risk of intracranial infection or symptomatic parenchymal disease in NCC.⁹ HIV-1 does not directly infect neurons, astrocytes or oligodendroglial cells but seems to be that affected microglial cells is whom dysregulate cytokines and chemokines production. Maslinska¹³ reported the accumulation and phenotype heterogeneity of mast cell (MC) contained immunoreactive tryptase in human brains with NCC. MC are the multifunctional effectors cells of the immune system, MC synthesize and secrete numerous powerful mediators such as endorphins, serotonin, histamine, heparin, kinins, leukotriens, prostaglandin, vasoactive intestinal peptide, proteolytic enzymes, cytokines and phospholipases which are well known to have significant pathophysiological effects on vascular (research in progress by Maslinska) and neuronal tissues. The role of MC accumulated in the CNS regarding host immune tolerance is clear but regulating factors for MC accumulation are not certain. Because MC provide a source of multifunctional cytokines and other potent mediators has been proposed that MC participate in control of cerebral blood flow and the integrity of the blood-brain-barrier. Perilesional edema in calcified lesion is probably related with histamine concentration from MC, inducing vasopermeability and cerebrovascular damage.

CLINICAL PRESENTATION

Most of our patients present with wide variety of epileptic attacks (89 %); signs of intracranial hypertension secondary to CFS flow obstruction and hydrocephalus, meningeal syndrome, and ischemic stroke are very less common¹⁰. Among our patients, focal neurological signs by lesion in the long motor pathways, cranial nerves disorders, cerebellar manifestations, and signs of encephalitis have been observed. In HIV patients (CD4 count >350/mm) with INCC, raised intracranial pressure is still the most common problem and although new-onset seizures associated with late-stage HIV infection has been documented recently¹⁴ in our series, epileptic attacks were NCC related. Psychiatric symptoms,¹⁵ intramedullary lesions,^{16, 17} extra ocular manifestations,¹⁸ optic nerve lesions,¹⁹ orbital and ocular presentation,²⁰ lesions on the tongue and buccal mucosa,²¹ and cutaneous manifestations,²² have been reported.

MEDICAL MANAGEMENT

Many tests to confirm HIV infection have been reported and we are not longer be describing all of them, in our series we used Elisa test for most of the patient and sometimes CD4 count and viral load when it was possible.

For INCC the best investigations to confirm the diagnosis, to establish a trusted prognosis and proper follow-up are CT Scan and/or MRI of the brain, CT Scan of the brain showing the scolex in to the cysts is the test of choice. There is abundant information regarding these topic in available medical literature.^{1 2 8 9 10}

As was before-cited most patients with INCC presented with intracranial hypertension in critical stage, those patients with tonic-clonic generalized seizure respond very well to anti-epileptic monotherapy, however HIV patients can present different respond because other mechanisms are involved including increased number of parasites in different stages (re-infection plus prolongation of the other parasite' stage) for more the 2 years.²³ Medication of choice for intraparenchymal presentation (commonest one) of NCC is praziquantel in spite of its reduced effect when is associated to anti-epileptic therapy. Praziquantel is a effective isoquinoline for almost all helminthes, it is absorbed very quickly reaching its peak concentration in serum 1 or 2 hours after oral administration, half life is around 2 to 3 hours, and concentration in blood increase 10 % when high carbohydrate diet is given.

Oral doses of 25 mg/kg 3 hourly four times for one day

followed by 4 days treatment with steroids, can kill almost all of them with minimal side effect producing a spastic paralysis of the parasite musculature, destroying the scolex and affecting the metabolism of the parasite's membrane; for patients with recurrent seizures or in status epilepticus 100mg/kg/day dosage should be given divided in four doses hourly per os or by nasogastric tube always associated with steroid medication. Praziquantel is contraindicated in ocular NCC and during pregnancy, but we have found no teratogenic effect in patients under single day treatment. In some anecdotic cases no responding to praziquantel, albendazole which kills the parasites by inhibition of the glucose up-taking, must be prescribed at no less than 15-20mg/kg/day for a week however for INCC without intraparenchymal cyst albendazole is the medication of choice, also confirmed with our findings.

In HIV patients we recommend to take praziquantel in regular cycles of one- day treatment per month for twelve month and associated 2- 3 days steroids medications, mainly for those patients living in endemic areas; for patients with demonstrated INCC to take albendazole on monthly basis is very strong recommended. Although some controversial results about praziquantel treatment have been reported^{24 25} we emphasize on one-day treatment of praziquantel therapy four times per year for those patients with multiple intraparenchymal lesions, and women at the reproductive ages; and for those with INCC living in endemic areas with higher risk of re-infection or being HIV seropositive, anti-helminthic treatment with albendazole/seven days every three months even for years should be considered until better life condition with alleviation of poverty, with proper access to electricity, adequate access to save and clean water and toilets, good sanitary control of the pig population, better hygiene of foods, and more effective primary health care system will be implemented.

We feel that better results in the program for control tuberculosis will help to reduce fatal consequences in HIV patients with INCC. For the other hand, while those enormous economic differences between countries persist the immigration rates from endemic regions will continue increasing gradually and INCC will become a worldwide problem, perhaps affecting less those with very cold climate and/or extremely well developed primary health care system. We would like to emphasized that while this situation persists the number of infected immigrants to developed areas will continue increasing.²⁸ We believe that this disease present more commonly than has been appreciated in our

experience; we also believe that massive vaccination of the pigs population without a good primary health care supporting system, is wasting time and resources.

When the immune system fails to kill the parasite then the highly activated members of the macrophage family fuse to form giant cells in an attempt to rid the body of what the immune system could not destroy. Soluble substances released by virally infected or cytokine-stimulated monocyte/macrophages and microglia can activate or disrupt the blood-brain-barrier (BBB).²⁹ They also stimulate macrophages in the CNS, augmenting their recruitment and retention. That combination of HIV-INCC appears to drive monocytes towards the activated macrophages phenotype, resulting in the release of matrix-metalloproteinases that degrade extracellular matrix integrity. Brain-resident macrophages and microglia, as well as astrocytes in HIV infected CNS; synthesize chemokines including MIP-1alpha and MIP-1beta, which are involved in stimulating monocyte traffic and retention. Injured neurons themselves may participate in recruiting macrophages to the CNS by secreting fractalkine, thereby potentially contributing to a cycle of increasing neuron damage and macrophage recruitment.²⁹

Finally, we considered important to highlight that a massive anti-helminthes medication campaign without an appropriated management of the secondary immunological reaction will not provide safe benefits to affected population, and the lack of health education program will facilitate a new cycles of re-infection with the consequent immunological changes in HIV patients facilitating the progression into AIDS with a increasing chance of opportunistic infection, and a higher mortality rate.

CONCLUSION

VPS is not longer the treatment of choice for HIV patients with INCC treated with praziquantel and this procedure should be reserved for patients with solitary INCC plus signs of ICH when they not response to albendazole properly.

We have hypothesized that in HIV patients the cysticercus live longer compare with non-HIV patients because the parasites are less attacked by the immunological system therefore the effect of praziquantel is more remarkable and more perilesional reaction secondary to substances released by the parasite should be present.

References

1. Foyaca-Sibat H, Ibanez-Valdes LdeF, Awotedu A,

- Fernandez-Mena C. Neurocysticercosis in the former Transkei. 7th Internet World Congress for Biomedical-Sciences, Inabis 2002. April 14-20, 2002 website: http://www.inabis2002.org/poster_congress/area_01/01011/010117.pdf
2. Del Bruto OH, Rajshekhar V, White AC, Tsang VCW, et al Proposed diagnosis criteria for neurocysticercosis. *Neurology* 2001;57:177-183.
3. Commission Tropical Diseases of the International League Against Epilepsy. Relationship between epilepsy and tropical diseases. *Epilepsy* 1994; 35:98-93.
4. McMichael AJ, Rowland-Jones SL. Cellular immune response to HIV. *Nature* 2001;401:980-986.
5. Dorrington R, Bourne D, Bradshaw D, Laubscher R, Timaeus IM. The impact of HIV/AIDS on adult mortality in South Africa. Technical Report. Parow, South Africa: Burden of Disease Research Unit. Medical Research Council, 2001, ISBN 1-919809-14-7. Website: <http://www.mrc.ac.za/bod>.
6. Ficham J. Helminths, HIV/AIDS and tuberculosis. *AIDS Bulletin* Dec 2001;10(3):4-10.
7. McGuire D, Greece WC. Neurological damage in HIV infection. IN: Level AML, ed. *The Molecular Biology of HIV/AIDS*. New York: John Wiley & Sons, 1996:127-142.
8. White C. Neurocysticercosis: Update on Epidemiology, Pathogenesis, Diagnosis, and Management. *Annu.Rev.Med.* 2000;51:187-206.
9. Pal KD, Carpio A, Sander WASJ. Neurocysticercosis and epilepsy in developing countries. *J Neurol Neurosurg Psychiatry* 2000;68:137-143.
10. Foyaca-Sibat H, Ibanez-Valdes LdeF, Awotedu AA. Neurocysticercosis in critical stage. Proceeding of the NASA 2002 EGOLI Congress. March 20-24, 2002 Sadton Conventional Center, Johannesburg, South Africa.
11. Spolski RJ, Corson PG, Thomas PG, Kuhn RE. Parasite-secrete products regulate the host response to larval *Taenia crassiceps*. *Parasite immunology*. 2000;22:297-305.
12. Jain S, Padma MV, Kanga U. et al. Human leukocyte antigen studies in Indian probands with seizures associated with single small enhancing computed tomography lesions and seizure types in their family members. *Journal of Epilepsy* 1997;10:55-61.
13. Maslinska D, Damska M, Kalieska A, Maslinsmi S. Accumulation, distribution and phenotype heterogeneity of mast cell (MC) in human brains with neurocysticercosis. *Folia Neuropathol.* 2001; 39(1): 7-13.
14. Modi G, Modi M, Martinus I, Saffer D. New-onset seizures associated with HIV infection. *Neurology* 2000 Nov 28;55(10):1558-1561.
15. Schneider RK, Robinson MJ, Levenson JL. Psychiatric presentations of non-HIV infectious diseases. Neurocysticercosis, Lyme disease, and pediatric autoimmune neuropsychiatric disorder associated with streptococcal infection. *Psychiatr Clin North Am* 2002 Mar;25(1):1-16.
16. Mathuriya SN, Khosla VK, Vasishta RK, Tewari MK, Pathak A, Prabhakar S. Intramedullary cysticercosis. *Neurol India* 2001 Mar;49(1):71-74.
17. Homans J, Khoo L, Chen T, Commings DL, Ahmed J, Kovacs A. Spinal intramedullary cysticercosis in a five-year-old child: case report and review of the literature. *Pediatr Infect Dis J* 2001 Sep;20(9):904-908.
18. Santosh GH, Chandre GS. Ultrasonological characteristics of extraocular cysticercosis. *Orbit* 1998;17(4):271-284.
19. Gulliani BP, Dadeya S, Malik KP, Jain DC. Bilateral cysticercosis of the optic nerve. *J Neuro-ophthalmol* 2001 Sep;21(3):217-218.
20. Pushker N, Bajaj MS, Chandra M, N. Ocular and orbital

cysticercosis. *Acta Ophthalmol Scand* 2001 Aug;79(4):408-413.

21. Saran RK, Rattan V, Rajwanshi A, Nijkawan R, Gupta SK. Cysticercosis of the oral cavity: report of five cases and a review of literature. *Inter J. Paed. Dent* 1998(December);8(4):273-279.

22. Ponnighaus JM, Nmkhosa P, Baum HP. Cutaneous manifestation of cysticercosis. *Hautarzt* 2001Dec;52(12):1098-2000.

23. Foyaca SH, Ibanez-Valdes L, Awotedu AA, Fernandez-Mena C. Neurocysticercosis in critical stage. II Internet International Congress of Critical Medicine. December 1-15, 2001 Website; <http://www.uninet.edu/cimc2001/comunicaciones/foyaca/index.html>.

24. Sotelo J, Torre B, Rubio-Donnadieu, Escobedo F, Rodriguez-Carbajal. Praziquantel in the treatment of neurocysticercosis: long-term follow-up. *Neurology* 1985;35(5):752-755.

25. Del Brutto O, Campos X, Sanches J, Mosquera A. Single-day praziquantel versus 1-week albendazole for neurocysticercosis.

26. Pretll EJ, Garcia HH, Custodio N, Padilla, Alvarado M, Gilman RH, Martinez M. Short regimen of praziquantel in the treatment of single brain enhancing lesions. *Clin Neurol. Neurosurg.* 2000;102(4):215-218.

27. Pretell JE, Garcia HH, Gilman R, Saavedra H, Martinez M. Failure of one-day praziquantel treatment in patients with multiple neurocysticercosis lesions. *Clin Neurol. Neurosurg* 2001;103(3):175-177.

28. Foyaca SH, Tapeworm and the Brain. *Science in Africa*. 2002 XVII June: 3 Available on-line at:

<http://www.sciencein africa.co.za/2002/june/worm.htm>

29. Williams KC, Hickey WF. Central Nervous System Damage, Monocytes and Macrophages, and Neurological Disorders in AIDS. *Annul Rev. Neurosis.* 2002;25:537-562.

Author Information

H. Foyaca-Sibat

University of Transkei

LdeF Ibañez-Valdés

University of Transkei