

Spontaneous Dissecting Aneurysm Of Intra-Petrous Internal Carotid Artery

L Thomas, M Kaleem, C Yeong, S Kent

Citation

L Thomas, M Kaleem, C Yeong, S Kent. *Spontaneous Dissecting Aneurysm Of Intra-Petrous Internal Carotid Artery*. The Internet Journal of Otorhinolaryngology. 2003 Volume 3 Number 1.

Abstract

Internal Carotid Artery (ICA) dissection and other vascular abnormalities are known to cause pulsatile tinnitus, usually with associated neurological symptoms and signs. We report a case of spontaneous intra-petrous carotid dissection with aneurysm formation who had only pulsatile tinnitus.

The study was done at ENT and Radiology departments of Warrington Hospital

INTRODUCTION

Dissection of the Internal Carotid Artery (ICA) is a rare but increasingly recognised entity, in younger patients. It usually presents with pain, cerebral ischaemia, Horner's syndrome or intracranial haemorrhage and rarely with pulsatile tinnitus.¹ Most cases are either traumatic in origin or have underlying vascular disease such as atherosclerosis and fibromuscular dysplasia.² A small number of dissections which have no obvious cause are classified as spontaneous.

We present a case of Intra-petrous ICA dissection that occurred spontaneously. It was associated with aneurysm formation and presented solely with pulsatile tinnitus. The imaging strategies for pulsatile tinnitus are discussed, along with Magnetic Resonance (MR) and Computerised Tomography (CT) imaging features and different management options available for dissecting ICA aneurysm.

CASE REPORT

A 36-year old, healthy manual labourer, presented to our ENT clinic with a six month history of gradual onset pulsatile tinnitus. Initially it was intermittent, becoming apparent on exertion. Later his tinnitus became more pronounced and present at rest. The hearing in both ears was normal and there were no associated neurological symptoms.

The patient did not recall any head and neck trauma associated with the onset of the tinnitus. There was no family history or past medical history of migraine, hypertension or hypercholesterolaemia. He has been a

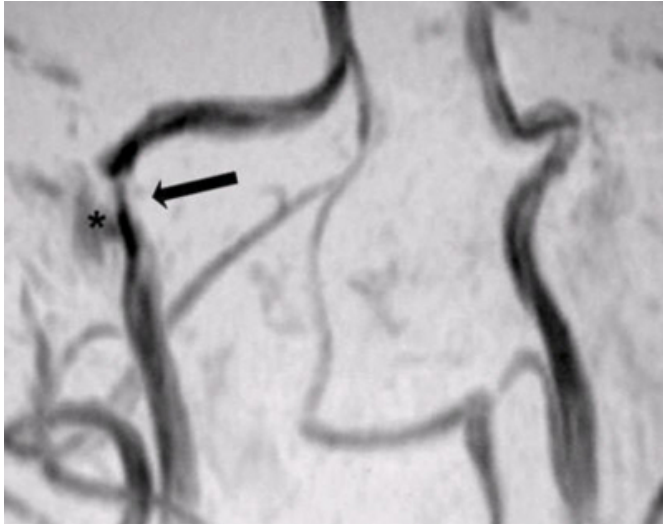
smoker for the last 15 years. He was not on any regular medication.

Otoscopic examination, pure tone audiometry and tympanometry were normal. Superficial temporal arteries were felt to be normal on either side.

The patient was referred to the vascular surgery department. A Magnetic Resonance Angiogram (MRA) was subsequently performed which revealed an area of stenosis in the right ICA just inferior to its horizontal intra-petrous segment (Fig.1). The Magnetic Resonance Venography (MRV) as well as the Magnetic Resonance (MR) scan of the brain was normal on that occasion.

Figure 1

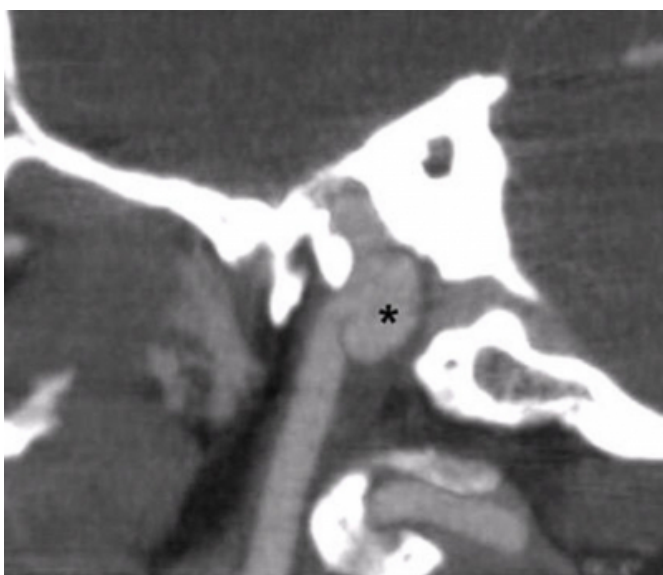
Figure 1: MRA showing stenosis in the right ICA (arrow). There is some signal lateral to the stenosis, which is due to slow flow within the aneurysmal sac of the dissection (asterix).



Computerised Tomographic Angiogram (CTA) showed the right ICA to be aneurysmal in the vertical intra-petrous part, just proximal to the horizontal portion, along with an intraluminal septum in keeping with a small dissecting aneurysm that measured 10mm x 6mm (Fig.2). The horizontal portion of the right Intra-petrous ICA and the left ICA were normal.

Figure 2

Figure 2: CT angiogram of the right ICA, sagittal view, showing the aneurysm (asterix) in the posterior aspect of the dissection, causing stenosis.



DISCUSSION

The role of minor trauma as a cause of carotid dissection is well described. Examples of such trauma include extreme and prolonged neck extension or lateral flexion including chiropractic manipulation.³ Several cases of pulsatile tinnitus due to petrous ICA dissection, have been reported, but without any associated aneurysm.^{4,5}

There are only few case-reports of dissecting aneurysms of the ICA causing pulsatile tinnitus. One such case was associated with severe blunt trauma,⁶ whilst another was probably secondary to fibromuscular dysplasia.¹ The third case reported of apparently spontaneous aetiology presented after an army physical fitness test.⁷ Our patient developed a spontaneous dissecting aneurysm of the Intra-petrous ICA, presenting purely with pulsatile tinnitus, thus is probably the first described in English language literature.

The most common initial symptom of ICA dissection is unilateral neck or head pain followed by cerebral ischaemic symptoms like transient ischaemic attacks and stroke.⁸ Other infrequent symptoms include incomplete Horner's syndrome, cranial nerve palsies and pulsatile tinnitus which can be objective or subjective. Pulsatile tinnitus is the sole presenting symptom in 4% and an associated symptom in 35% of cases involving spontaneous extracranial carotid artery dissections.⁹ Most patients who may initially present with only pulsatile tinnitus will subsequently develop neurological symptoms.

The various aetiology for pulsatile tinnitus include vascular tumours, congenital or acquired vascular abnormalities around the ear, benign intracranial hypertension, otosclerosis and Paget's disease.¹⁰

Diagnostic work-up for pulsatile tinnitus includes different imaging modalities ranging from invasive Contrast Angiography to non-invasive tests like MRA and CTA. Doppler Ultrasound is generally not useful. There have been different studies commending different algorithms for the diagnostic approach. In general CT/CTA is recommended as the first line of investigation for tinnitus which is pulsatile and when there are positive otoscopic signs. MR/MRA, on the other hand is the preferred first line modality when tinnitus is non-pulsatile and the tympanic membrane is normal on examination.¹⁰ As is well illustrated in our case, the two modalities are complementary to each other and the choice may be influenced by the accessibility and quality of the available scanners as well as the local radiologist's

preference and experience. The CTA technique is becoming more popular with the availability of multi-slice CT technology and its excellent multiplanar resolution. This is particularly true for the petrous ICA imaging due to intra-osseous course of the artery. Contrast Angiography may still play a role in presence of normal CT and MR examinations as it remains the best modality to show arterio-venous malformations and fistulas.¹⁰

Management of ICA dissection in acute situation with stroke, involve intra-arterial thrombolysis within six hours of onset. Further anticoagulation with heparin followed by warfarin or antiplatelet agents is recommended to prevent thrombo-embolic complications.¹¹ A Cochrane review has shown no evidence to support the routine use of anticoagulants or antiplatelets for the treatment of extracranial ICA dissection.¹² The clinical course of dissecting aneurysm has been shown to be benign in different studies.^{13,14} In the case of a dissecting aneurysm formation, which happens in up to 40% of dissections,¹³ the management is mainly conservative especially in small aneurysms as in this particular case. However, serial imaging in the form of CT or MR angiography is prudent for the aneurysm follow up.

The surgical treatment of dissecting aneurysms carries a small risk of stroke and transient nerve palsies.¹⁵ The different techniques include carotid ligation, aneurysm resection and carotid reconstruction or cervical to intracranial ICA bypass. Alternatively, endovascular treatment with stenting and coil embolisation has been reported successful for both intra and extracranial carotid artery aneurysms.¹⁶

Our patient is not keen on any treatment and is planned to undergo non-invasive imaging follow up and conservative management.

CONCLUSION

It is worthwhile investigating patients presenting with

persistent pulsatile tinnitus. The finding of a dissecting aneurysm is rare and alarming but does appear to be benign.

References

1. Depauw P, Caekebeke J, Vanhoenacker P. Objective pulsatile tinnitus caused by intrapetrous dissecting aneurysm. *Clin Neurol Neurosurg.* 2001; 103: 197-199
2. Sismanis A, Stamm MA, Sobel M. Objective tinnitus in patients with atherosclerotic carotid artery disease. *Am J Otol* 1994;15:404-407
3. Haneline MT, Croft AC, Frishberg BM Association of internal carotid artery dissection and chiropractic manipulation. *Neurolog.* 2003; 9: 35-44
4. Harris JP, Horlbeck DM, Brew KH Unique case of pulsatile tinnitus. *Ann Otol Rhinol Laryngol.* 2000; 109: 1103-1106
5. Saeed SR, Hinton AE, Ramsden RT, Lye RH. Spontaneous dissection of the intrapetrous internal carotid artery. *J Laryngol Otol.* 1990; 104: 491-493
6. Reece PH, Higgins N, Hardy DG, Moffat DA An aneurysm of the petrous internal carotid artery. *J Laryngol Otol.* 1999; 113: 55-57
7. Vories A, Liening D. Spontaneous dissection of the internal carotid artery presenting with pulsatile tinnitus. *Am J Otolaryngol.* 1998; 19: 213-215
8. Anson J, Crowell RM. Cervicocranial arterial dissection. *Neurosurgery* 1991; 29: 89-96
9. Hart RG, Easton DJ. Dissection of cervical and cerebral arteries. *Neurol Clin.* 1983; 1: 155-182
10. Weissman JL, Hirsch BE. Imaging of tinnitus : a review. *Radiology* 2000; 216: 342-349
11. Dziewas R, Konrad C, Dragner B, Evers S, Besselmann M, Ludemann P, et al. Cervical artery dissection- clinical features, risk factors, therapy and outcome in 126 patients. *J Neurol* 2003;250:1179-84
12. Lyrer P, Engelter S. Antithrombotic drugs for carotid artery dissection. *Cochrane Database Syst Rev.* 2000;4:CD000255
13. Guillon B, Brunereau L, Biousse V et al. Long term follow up of aneurysms developed during extracranial internal carotid artery dissection. *Neurology* 1999; 53: 117-122
14. Touze E, Randoux B, Meary E et al. Aneurysmal forms of cervical artery dissection : associated factors and outcome. *Stroke* 2001; 32: 418-423
15. Schievink WI, Piepgras DG, McCaffrey TV, Mokri B. Surgical treatment of extracranial internal carotid artery dissecting aneurysms. *Neurosurgery* 1994; 35: 809-815
16. Bush RL, Lin PH, Dodson TF et al. Endoluminal stent placement and coil embolization for the management of carotid artery pseudoaneurysms. *J Endovasc Ther.* 2001; 8: 53-61

Author Information

Ligy Thomas, FRCS

SHO, Otolaryngology, Countess of Chester Hospital

Musa Kaleem, FRCP

SpR, Radiology, Arrowe park Hospital

Chi C. Yeong, FRCS

Consultant Radiologist, Warrington Hospital

Stephen E. Kent, FRCS

Consultant ENT surgeon, Warrington Hospital