

# CMV Pneumonitis in an Immunosuppressed Patient With C-ANCA Positive Glomerulonephritis

M Kedmi, M Margalit, S Maayan, M Shalit, A Rokach

## Citation

M Kedmi, M Margalit, S Maayan, M Shalit, A Rokach. *CMV Pneumonitis in an Immunosuppressed Patient With C-ANCA Positive Glomerulonephritis*. The Internet Journal of Internal Medicine. 2007 Volume 7 Number 2.

## Abstract

Cytomegalovirus (CMV) pneumonitis is an important cause of morbidity and mortality in HIV and post-transplant patients, and is rare in patients with autoimmune diseases treated with immunosuppressive therapy. We report the first case of a patient with Cytoplasmic anti neutrophil cytoplasmic antibodies positive glomerulonephritis who developed CMV pneumonitis after treatment with cyclophosphamide and prednisone. The CMV infection developed simultaneously with bacterial respiratory infection. All symptoms resolved rapidly under treatment with gancyclovir and immunoglobulins.

## ABBREVIATIONS

C-ANCA=cytoplasmic anti neutrophil cytoplasmic antibodies

BAL=bronchoalveolar lavage

CMV=cytomegalovirus

## INTRODUCTION

CMV pneumonitis is an important cause of morbidity and mortality in HIV and immunosuppressed post-transplant patients. This entity is rare in patients with autoimmune disorders who are treated with immunosuppressive agents. In a review of the medical literature, we have found only two reports that describe patients with systemic lupus erythematosus who developed CMV pneumonitis while on corticosteroids and cyclophosphamide. As best as we can say, we report the first case of CMV pneumonitis in a patient with C-ANCA positive glomerulonephritis who was treated with oral corticosteroids and cyclophosphamide.

## CASE REPORT

A seventy-seven year old male was admitted with prolonged fever, confusion and a productive cough. Past medical history was notable for ischemic heart disease and hypertension. Three months prior to his admission, the patient was diagnosed with C-ANCA positive glomerulonephritis, which presented as unrelenting fever and renal failure. CMV serology (IgG and IgM) at that point was negative. Treatment with oral cyclophosphamide, prednisone and haemodialysis were initiated. At the time of admission he was receiving 150mg/day cyclophosphamide

and 20mg/day prednisone.

On physical examination the patient appeared confused and agitated, Body temperature was 37.8°C, Oxygen saturation was 85% in room air. Examination of the lungs revealed prolonged expiration and bilateral rales. The rest of the physical examination was unremarkable.

Complete blood count was significant for mild normocytic anemia (Haemoglobin 10.7g/dL, MCV 84), with no additional abnormalities. LDH was markedly elevated (1032 units, normal range: 300-620 units). The chest X-ray was normal.

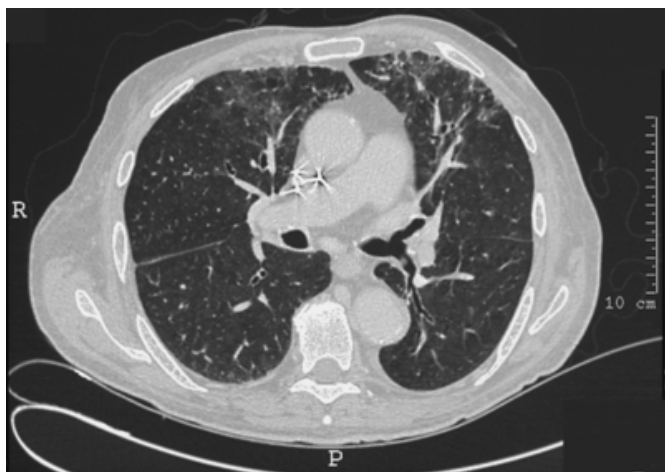
Sputum cultures were positive for *Serratia marcescens*. Intravenous antibiotics were initiated and the dialysis catheter removed for presumed line-associated bacteremia. Despite these measures, the patient's condition continued to deteriorate, with progressive dyspnea and worsening hypoxemia. High-resolution CT demonstrated non-specific interstitial changes in the apices of both lungs and diffuse ground glass appearance (Fig. 1). Bronchoscopy with bronchoalveolar lavage (BAL) was done; a positive shell vial assay established the diagnosis of pulmonary CMV infection. Bacterial culture was once again positive for *Serratia marcescens*. Staining for *Pneumocystis carinii*, acid fast staining and culture for *Mycobacterium tuberculosis* were negative.

In view of these findings, intravenous gancyclovir and immunoglobulins were administered, cyclophosphamide was

stopped and steroids were tapered, with rapid resolution of the fever and hypoxemia. Treatment with intravenous ganciclovir was continued for 3 weeks, followed by oral ganciclovir for another four weeks; IV Immunoglobulins was given over seven weeks. CMV IgG after resolution of the disease turned positive.

### Figure 1

Figure 1: thoracic CT scan demonstrating the interstitial changes in the apices of both lungs. High resolution CT scan of the lungs shows non-specific interstitial changes at the apices of both lungs, and diffuse ground glass appearance.



### DISCUSSION

CMV infection is very common and usually asymptomatic in the general population (<sub>1</sub>). In adults, severe CMV disease usually results from a significant defect in cellular immunity, as observed in immunosuppressed, post-transplant and HIV patients. CMV pneumonitis occurs in 17-38% of solid organ recipients; in bone marrow transplant patients the disease tends to be more severe, though it is somewhat less frequent (<sub>2,3</sub>). Cytotoxic immunosuppressants and depressors of T-cell function increase the risk of infection, steroids are not considered to so (<sub>4</sub>).

In a search of the literature, we have found only two case report of CMV pneumonitis in a patients treated by intensive combined therapy with cyclophosphamide and corticosteroids for lupus nephritis (<sub>5, 6</sub>). To our knowledge, our patient is the first described case of CMV pneumonitis in the context of immunosuppressive therapy for C-ANCA positive glomerulonephritis. The reason for the decreased propensity of immunosuppressed rheumatologic patients to develop CMV pneumonitis, compared to post-transplant patients, is not known, and may relate to the latter's worse general condition and multiple co morbidities, as well as to the extent of immunosuppression.

In our patient, pulmonary involvements of Wegener's granulomatosis as well as infection were viable explanations for the observed clinical course. Interestingly, the white blood count on admission was normal, despite a combination of CMV infection and treatment with cyclophosphamide.

In the bowel, CMV has been shown to colonize areas of mucosal inflammation secondary to various aetiologies (<sub>7</sub>). A similar situation may exist in the respiratory tract. In our case, underlying infection with *Serratia marcescens* may have predisposed the patient to colonization with CMV. The rapid response to specific treatment for CMV infection, the positive shell vial test and the sero-conversion leads us to believe that CMV had a central role in the pathogenesis of this patient's illness.

### CONCLUSIONS

We conclude that CMV pneumonitis, while uncommon, may complicate the disease course of rheumatologic patients treated by immunosuppressive agents. Bacterial infection may predispose the patient to CMV pneumonitis. Bronchoscopy may be essential to establish the diagnosis. We also suggest, that blood count alone may not be a reliable parameter for monitoring the immune suppression of patients receiving cyclophosphamide.

### CORRESPONDENCE TO

Meirav Kedmi MD Hematology department Hadassah University Hospital PO Box 12000 Jerusalem Israel, 91120  
Tel: 972-2-6776685 Fax: 972-2-5332056 E-mail: meiravk@ekmd.huji.ac.il

### References

1. Krech U. Complement-fixing antibodies against cytomegalo-virus in different parts of the world. *Bull WHO* 1973; 49:103-106.
2. Bowden RA. Antivirals for CMV. In: Michelson F, Plotkin SA, editors. *Understanding Cytomegalovirus disease*. Amsterdam: Elsevier, 1993; 241-249.
3. Myers JD, Spencer HC, Watts JC, et al. Cytomegalovirus pneumonia after human marrow transplantation. *Ann Intern Med* 1975;82:181-188.
4. De la Hoz RE, Stephens G, Sherlock C. Diagnosis and treatment approaches of CMV infections in adult patients. *J Clin Virol* 2002; 25(Suppl 2):1-12.
5. Tokunaga Y, Takenaka K, Asayma R, et al. Cytomegalovirus-induced interstitial pneumonitis in a patient with systemic lupus Erythematosus. *Intern Med*. 1996; 35:517-520.
6. Garcia-Porrúa C., Gonzalez-Gay M.A., et al. Fatal interstitial pneumonia due to cytomegalovirus following cyclophosphamide treatment in a patient with systemic lupus erythematosus. *Scand-J-Rheumatol*. 1998; 27: 465-6
7. Ohashi N, Isozaki T, Shirakawa K, et al. Cytomegalovirus colitis following immunosuppressive therapy for lupus peritonitis and lupus nephritis. *Intern Med*.

2003;42:362-366.

**Author Information**

**Meirav Kedmi, MD**

Department of Medicine A, Hadassah-Hebrew University Medical Center

**Maya Margalit, MD**

Department of Medicine A, Hadassah-Hebrew University Medical Center

**Shlomo Maayan, MD**

Department of Clinical Microbiology and Infectious Diseases, Hadassah-Hebrew University Medical Center

**Meir Shalit, MD**

Department of Medicine A, Hadassah-Hebrew University Medical Center

**Ariel Rokach, MD, MHA**

Institute of Pulmonology, Hadassah-Hebrew University Medical Center