

# A rare cause of Ischemic colitis and review of literature.

G S, D S, A P.

## Citation

G S, D S, A P.. *A rare cause of Ischemic colitis and review of literature..* The Internet Journal of Gastroenterology. 2009 Volume 9 Number 1.

## Abstract

Tumour necrosis factor(TNF) alpha is an inflammatory cytokine. Inhibition of TNF alpha is effective in the treatment of rheumatoid arthritis and other inflammatory rheumatic diseases. We describe a rare presentation of ischemic colitis without vasculitis in a patient who received anti-TNF for rheumatoid arthritis.

## CASE REPORT

A sixty year old man presented with seven days history of post-prandial bilious vomiting, right flank and upper quadrant cramping pain, abdominal distension and diarrhoea for four days followed by absent bowel motions for three days. Two weeks prior to this presentation an anti-TNF treatment (Adalimumab 40mg injections fortnightly) had been started for his rheumatoid arthritis.

His past medical history included hypertension, a duodenal ulcer, depression and he had an appendicectomy. In the past he had been on methotrexate, gold, sulphasalazine, prednisolone for his rheumatoid arthritis. Presently he was only on azathioprine with his new adalimumab. He was a retired non-smoker, self-sufficient and lived with his family.

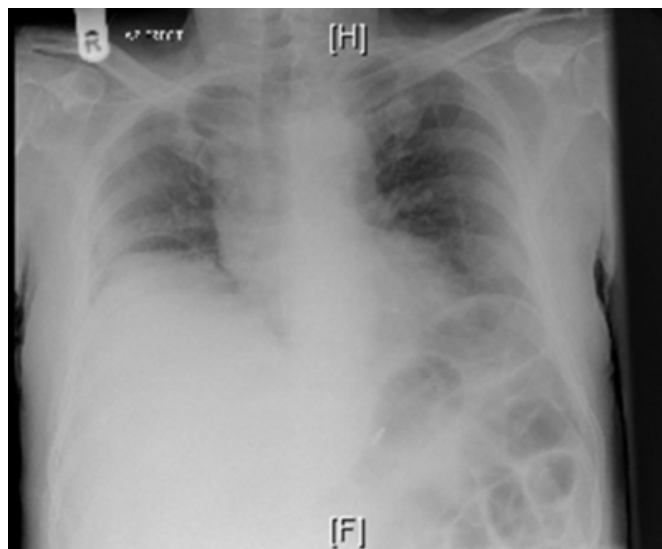
He looked pale, clammy and was uncomfortable. Bedside observations revealed that he was tachycardic (115 bpm), normotensive (130/70 mm/hg), tachypnoeic (28) and pyrexial (38.4 C).

On examination his abdomen was distended and peritonitic particularly in the right upper quadrant and flank, but bowel sounds were preserved. Digital rectal examination was normal.

His blood tests revealed a leucocytosis (WCC 39.0), an elevated C-reactive protein (326.6) and an arterial base excess of -6.8. Radiographically he had pneumoperitoneum and dilated loops of small bowel (Fig 1 & 2).

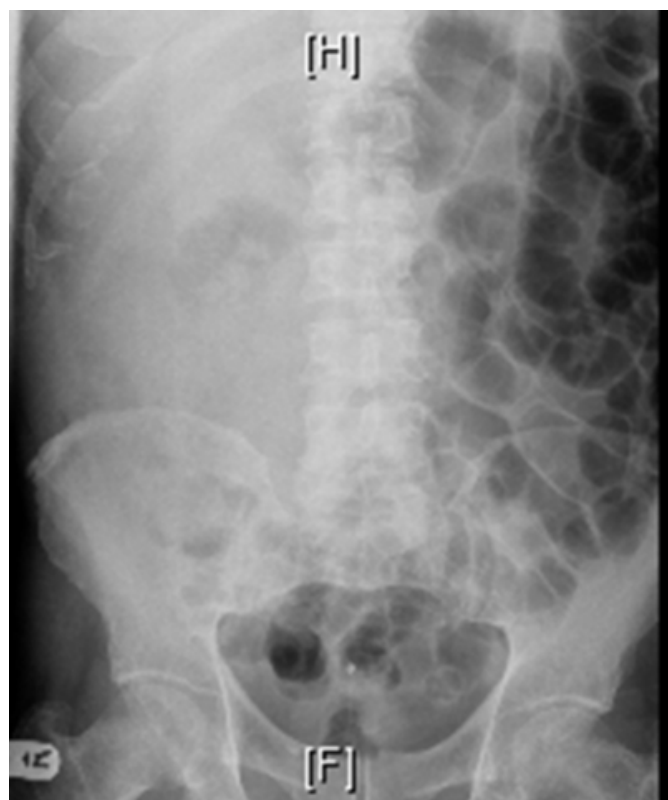## Figure 1

Fig:1 pneumoperitoneum



**Figure 2**

Fig:2 dilated smallbowel loops.



Broad-spectrum antibiotics were commenced and he was resuscitated for an exploratory laparotomy, which revealed gangrenous perforated ischemic ascending colon causing faecal peritonitis. A right hemi-colectomy was performed with an end-ileostomy and mucus fistula formation.

The histology reported an ischemic colitis but no evidence of a vasculitis. There was extensive fat necrosis and reactive changes throughout the specimen. The ascending colon displayed varying degrees of mucosal infarction and early necrosis of the wall sparing the mucosal layer. The extent of inflammation within fat around the affected area of bowel with the formation of an abscess cavity was reported as unusual.

Post-operatively he suffered from a moderate sepsis and developed several intra-abdominal collections, some of which were ultrasonically percutaneously drained. Microbiological pus studies showed a heavy growth of ampicillin resistant coliforms. He settled with conservative management and his anti-TNF treatment was not recommenced on rheumatological advice.

## DISCUSSION

Tumour necrosis factor alpha (TNF-alpha) is an

inflammatory cytokine that causes apoptotic cell death, cellular proliferation, differentiation, inflammation, tumourogenesis and viral replication<sup>1</sup>. It also stimulates the hypothalamic- pituitary adrenal axis by stimulating the release of corticotrophin releasing hormone<sup>2</sup>. It attracts neutrophils very potently and helps them to stick to the endothelial cells for migration<sup>3</sup>. Its primary role is in the regulation of immune cells. It has been implicated in a variety of rheumatic and inflammatory diseases<sup>4</sup>. TNF is mainly produced by macrophages and also by endothelial cells, mast cells, lymphoid cells, cardiac myocytes, adipose tissue, fibroblasts and neuronal tissues<sup>3</sup>. Matrix metalloproteinases (MMPs) play a crucial role in the intestinal wound healing. Matrilysin-1(MMP-7), Stromelysin-2(MMP-10) and collagenase-1(MMP-1) are involved in intestinal re-epithelization in vivo and they are up regulated by TNF<sup>5</sup>.

Anti TNF alpha medications are expected to down regulate the inflammatory reactions associated with autoimmune diseases. Infliximab is a mouse-human chimeric anti-TNF –alpha monoclonal antibody, etanercept is a recombinant human TNF receptor-IgG fusion protein and adalimumab is an anti- TNF- alpha recombinant human IgG1 monoclonal antibody<sup>2</sup>. As these are immunosuppressant, the important adverse reactions are infections, activation of tubercle bacilli, fatal blood disorders, rarely lymphoma, serious liver injury and demyelinating central nervous system disorders<sup>6</sup>.

There are two major forms of colonic ischemia – gangrenous (transmural) and non-gangrenous colitis (disease contained within colonic wall). Gangrenous ischemic colitis caused by occlusion of major mesenteric vessels and by progressive non-gangrenous ischemic colitis. In contrast to the rarity of non occlusive ischemia of the small bowel is the relative frequency of local vascular hypoperfusion of the colon. The colon receives less blood, fewer vascular collaterals and possesses an ongoing forceful motor activity<sup>7</sup>.

The classical presentation of non-gangrenous ischemic colitis is characterised by a sudden onset of severe crampy abdominal pain, diarrhoea with or without fresh blood and the physical examination may reveal distended abdomen with bowel sounds and no signs of peritoneal involvement<sup>8</sup>. The colitis could be associated with hypotension, congestive heart failure, atherosclerosis, small vessel disease such as diabetes, vasculitis, amyloidosis, radiation, hypercoagulable states, contraceptives, NSAIDs<sup>9</sup>, cocaine, verapamil, diuretics<sup>10</sup>, gold therapy<sup>11</sup>, simvastatin, long distance

running, dialysis, infections such as CMV, E.coli 0157:H7. The disease may either resolve or progress to gangrenous colitis.

In rheumatoid arthritis it is well known that secondary ischemic changes may occur in ileum and colon. The histologic features include necrotising vasculitis with fibrinoid necrosis and mural thrombus in submucosal layer of the bowel<sup>12</sup>. There are few reports of segmental ischemic colitis associated with the use of NSAIDs and gold therapy in rheumatoid arthritis. In this case no other possible etiologic factors were shown and the possible cause for the ischemic gangrenous ascending colon may be related to the 40 mg adalimumab injected subcutaneously a week before the event. A better knowledge of gastrointestinal side effects of anti TNF is warranted.

## **References**

1. Kalden JR. Emerging role of anti-tumor necrosis factor therapy in rheumatic diseases. *Arthritis Res.*2002;4 Suppl 2:S34-40.Epub 2002 may 24.
2. Moreland LW. Drugs that block tumour necrosis factor: experience in patients with rheumatoid arthritis. *Pharmacoeconomics.*2004;22(2 Suppl 1):39-53.
3. Robbins Pathologic basis of disease, Cotran et al 7th edition.
4. Emerging role of anti-tumour necrosis factor therapy in rheumatic disease, *Arthritis Res* 2002; E pub 2002 may 24 .
5. Collagenase, matrilysin-1, stromelysin are expressed by migrating enterocytes during intestinal wound healing, *Scand J Gastroenterology* 2004 Nov; 39(11); 1095-104.
6. TNF alpha blockade in human diseases: an overview of efficacy and safety, *Clin Immunol.* 2008 Jan; 126 (1): 13-30.
7. A.A. Tempia-Caliera, P.Renzulli et al. Mesenteric Inflammatory Veno-Occlusive Disease: A Rare Cause of Intestinal Ischemia. *Digestion* 2002;66:262-264.
8. Baert F, Hart J et al. A case of diclofenac- induced colitis with focal granulomatous change. *Am J Gastroenterol.* 1995 Oct;90(10):1871-3.
9. Segmental ischemic colitis associated with NSAIDs, *J Clin Gastroenterology* 1993 Jan ; 16(1); 31-4
10. Simulation of a colon carcinoma : diuretic induced ulcerative structuring ischemic colitis, *Dtsch Med wochenschr*,2004 mar 26; 129(13):681-4.
11. Ischemic colitis and immune complexes during gold therapy for rheumatoid arthritis, *Ann Rheum Dis.* 1984 Jun; 43(3): 495-7.
12. Gastroenterology manifestation of Rheumatologic disorders, Shiraz E – medical journal Vol 13 / Jan 2002.

**Author Information**

**Gopalswamy S**

Department of Coloproctology, The Royal Cornwall Hospital

**Dindyal S**

Department of Coloproctology, The Royal Cornwall Hospital

**Arumugam P.**

Department of Coloproctology, The Royal Cornwall Hospital