

# Internal Jugular Vein Thrombosis Following Neck Surgery

P v, N Chakrabarty, R Shetty, A Jain

## Citation

P v, N Chakrabarty, R Shetty, A Jain. *Internal Jugular Vein Thrombosis Following Neck Surgery*. The Internet Journal of Surgery. 2010 Volume 26 Number 2.

## Abstract

Internal jugular vein (IJV) thrombosis is a rare complication following neck surgery. It is an under-diagnosed condition that may also occur following central venous access, in local malignancy, polycythemia, hyperhomocysteinemia, after neck massage and intravenous drug abuse. It is also reported to occur spontaneously. The diagnosis is often challenging and requires a high degree of clinical suspicion. A quick diagnosis is important since there can be lethal complications later. We present an instance of excision biopsy done for a lymphangioma in the neck followed by uneventful recovery in the immediate post-operative period. However, the patient developed IJV thrombosis after 2 weeks which was asymptomatic, detected and confirmed on Doppler ultrasound and treated with systemic anticoagulation. The case presents a rare instance of IJV thrombosis following a simple neck surgery with few such cases being reported in literature.

## INTRODUCTION

Internal jugular vein (IJV) thrombosis is a rare condition which may follow central venous catheterization and intravenous drug abuse. It has an association with local malignancies of the head, face and neck region and a rare association with systemic gastrointestinal malignancies and lymphoma<sup>(5)</sup>. Lemierre syndrome, also known as Necrobacillosis or post-angina septicemia is a condition where an infected IJV thrombus is caused by extension of oropharyngeal infection. It can have serious and potentially life-threatening complications that include systemic sepsis, chylothorax, papilledema, airway edema, and pulmonary embolism<sup>(7)</sup>. Hence, it requires a high degree of clinical suspicion for a quick diagnosis and prompt treatment.

Here we present a case of IJV thrombosis following excision biopsy performed for a lymphangioma in the neck.

## CASE REPORT

A 35-year-old male labourer presented to us with a painless left-sided neck swelling of 6 months duration. The swelling was 3 x 3cm in dimensions, soft and cystic in consistency, in the left anterior triangle, near the internal jugular vein. However, there was no evidence of any constitutional symptoms, pressure symptoms or movement with deglutition.

Ultrasonography of the neck region revealed a large anechoic cyst with a volume of approximately 50cc in the

left lateral aspect of the neck above the sternocleidomastoid muscle, in the intramuscular compartment, extending up to carotid artery and internal jugular vein but without any vascularity.

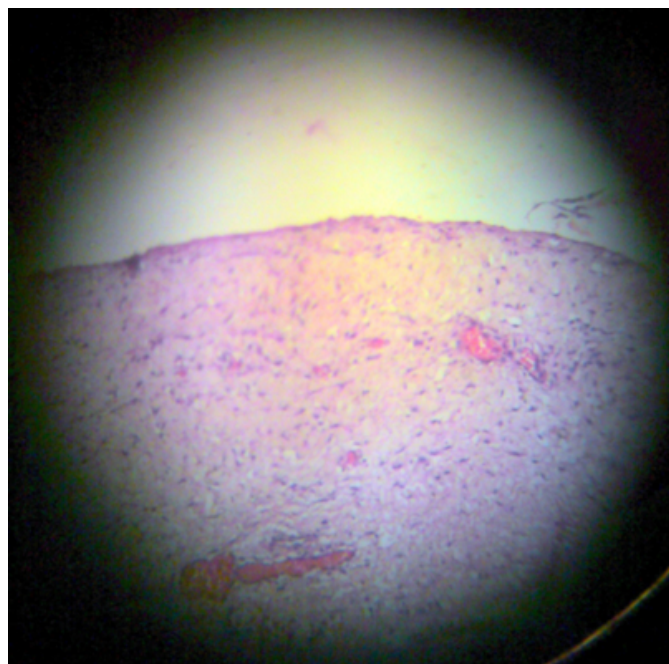
Fine-needle aspiration cytology (FNAC) revealed mature lymphocytes with foamy macrophages in proteinaceous background suggestive of lymphangioma.

A CT scan of the neck showed the swelling to be in close proximity to, but separate from, the left common carotid artery and internal jugular vein. The pharyngeal and laryngeal space and the rest of the neck spaces were normal.

An excision biopsy of the swelling was performed under general anesthesia with minimal tissue dissection since the swelling was well circumscribed and not adherent to surrounding structures. The swelling was thin-walled and contained clear fluid. Post-operative recovery as well as wound healing was uneventful and the patient was discharged from the hospital on the 5<sup>th</sup> day. The final histopathological diagnosis was "simple cyst" (Figure 1).

**Figure 1**

Figure 1: Histopathological image of a simple cyst

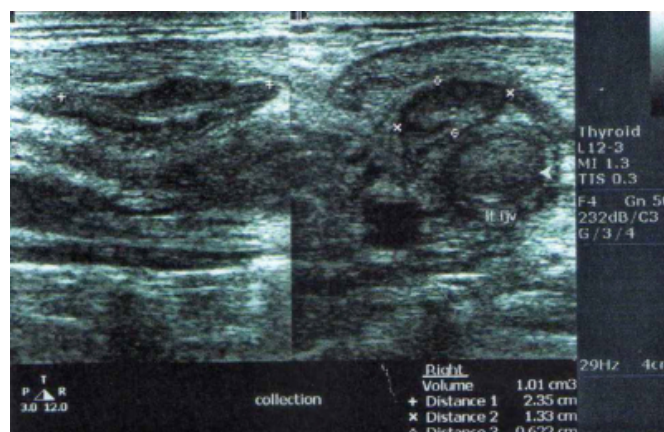


However, 2 weeks post-operatively he presented with a diffuse fullness of the left side of the neck and local pain around the operative site. There was local tenderness but without evidence of active inflammation. There was mild restriction of neck movements but without involvement of the sternocleidomastoid muscle on the same side.

Serum biochemistry, coagulation screening and hematological investigations including a total leucocyte count were within normal limits. Ultrasound colour Doppler of the neck confirmed our clinical suspicion of left internal jugular vein thrombosis. It revealed a thrombus 3.5cm long, along the entire length of the vessel. There was evidence of 2 cc of localized collection around the internal jugular vein (Fig. 2).

**Figure 2**

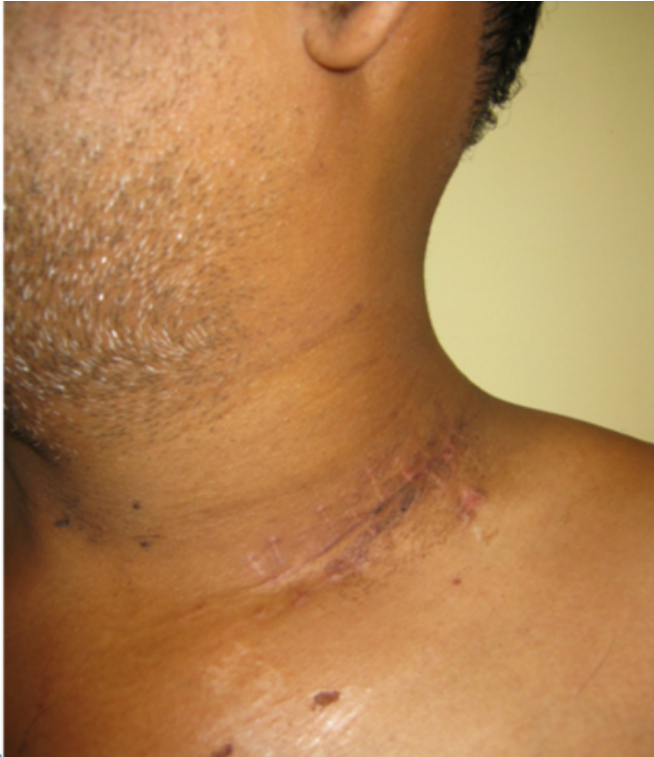Figure 2: The IJV shows an intra-luminal thrombus on Doppler ultrasound



The patient was admitted and started on systemic anticoagulation after confirmation of results on a CT scan. Strict observation was done to detect any sign of local infection or sepsis. Anticoagulation was started with heparin and then converted to oral warfarin after 3 days. Colour Doppler studies at the end of one week showed partial resolution of the thrombus and a normal coagulation profile with normal INR values. Recovery was uneventful (Figure 3) and the patient was discharged from the hospital after 2 weeks. Oral warfarin was continued for 6 weeks

**Figure 3**

Figure 3: Complete resolution of left IJV thrombosis



## DISCUSSION

Lymphangiomas are localized malformations in the development of the lymphatic system that most frequently affect the head and neck and may be present at birth. Spontaneous resolution has been reported to be as high as 41%<sup>(4)</sup>.

Surgical excision is the recommended treatment standard, but the invaginating nature of lymphangiomas, typically consisting of multiple cysts with a very thin lining, makes surgery difficult. Complete excision without damage to vital structures is possible in only approximately one third of cases and with incomplete excision, recurrence is extremely high (15%). Laparoscopic treatment and laser ablations have been reported with some success. The other options include intravenous cyclophosphamide therapy and intralesional bleomycin and OK-432, of which there are encouraging reports in a small number of cases<sup>(4)</sup>.

Recurrence of the lymphangioma is seen, but IJV thrombosis after surgery for lymphangioma in the neck is very rare, especially after a simple excision which did not involve extensive and time-consuming dissection<sup>(4)</sup>.

Internal jugular vein thrombosis, a very rare vascular

condition, was first described by Long as a complication of peritonsillar abscess in 1912<sup>(5)</sup>. It refers to an intraluminal thrombus occurring anywhere from the intracranial internal jugular vein to the junction of the internal jugular and subclavian vein.

The causes include central venous catheterization of IJV or subclavian vein, intravenous drug abuse, neck massage, local and systemic malignancies, Lemierre syndrome, head and neck surgery, hypercoagulable states and occasional spontaneous episodes<sup>(5)</sup>.

Etiological factors can be described in relation to Virchow's triad. Any factor causing endothelial damage, alteration in blood flow or hypercoagulable state can lead to IJV thrombosis. IJV catheters can potentiate thrombus formation by causing endothelial damage during insertion, or the catheter itself can act as a nidus for clot formation<sup>(6)</sup>. The mechanism of thrombus formation in oropharyngeal infections is likely to be the result of systemic hypercoagulability (caused or exacerbated by infection), venous stasis (from vessel occlusion by the infectious process of inflammation) and endothelial damage either due to direct endovascular invasion by microbes or through perivascular inflammation<sup>(6)</sup>.

IVJ thrombus with otitis media or mastoiditis is a result of progression of sigmoid sinus thrombosis. Endothelial damage and introduction of infection are the main causative factors of thrombosis in intravenous drug abusers. Malignancy potentiates thrombus formation by causing direct compression from tumour or nodes and by causing a hypercoagulable state<sup>(7)</sup>.

Clinical manifestations depend on whether it is infected (complicated) or not infected (uncomplicated)<sup>(5,6,7)</sup>. Uncomplicated cases present with pain, swelling in the neck and a cord can be palpated beneath the sternocleidomastoid muscle. Complicated cases present as fever in the majority (83%), leucocytosis (78%), and cervical pain in 66% of patients while 70% may complain of a neck swelling. Cord sign and sepsis syndrome may occur in about 40% and pleuro-pulmonary complications in around 30% of patients. Rarer complications include superior vena cava syndrome (11%), chylothorax (5%) and jugular foramen syndrome (6%). Our patient who presented with neck pain and a diffuse swelling but no features of infection therefore had an uncomplicated presentation.

Complicated IJV thrombosis requires culture from the

infective focus in the oro-nasopharynx with blood cultures. However, infected or septic IJV thrombosis requires detailed investigative screening which includes hypercoagulation work-up in form of protein C, protein S, antithrombin-3-deficiency tests and DIC screening with prothrombin time (PT), activated partial thromboplastin time (APTT), fibrin split products and fibrinogen. In the absence of infection, our patient was not subjected to any of these except a coagulation profile which included prothrombin time and APTT<sup>(3,5)</sup>.

When IJV thrombosis is diagnosed on ultrasonography, CT scan, MRI, nuclear isotope scan and contrast venogram can all be used for further confirmation<sup>(2)</sup>. However, contrast venogram can dislodge the thrombus resulting in embolism, apart from causing hypersensitivity reactions<sup>(3)</sup>. Ultrasound Doppler can detect flow rate, is non-invasive, cheap and easily affordable. However, it has its limitations in not being accurate enough in patients with thrombosis deep to the mandible and clavicle<sup>(2,3)</sup>. This was the first investigation performed in our patient. CT scan with intravenous contrast is considered by many to be the investigation of choice. The advantage of MRI lies in providing better soft-tissue definition and sensitivity to blood flow rates compared to CT scanning and not requiring exposure to contrast material or radiation. However, MRI is usually done if an intra-thoracic extension is suspected. Nuclear medicine scan is expensive and has a limited availability<sup>(2,3)</sup>.

Medical treatment varies for the different types of IJV thrombosis. Non-infected cases require systemic anticoagulation<sup>(5)</sup>; Complications of this therapy are possible and a strict watch on the coagulation profile and INR values is mandatory. Thrombolytic therapy has no documented role. However, in cases of neck dissection surgeries, post-operative IJV thrombosis is associated with spontaneous recanalisation and the vessel has good long-term patency.

In infected IJV thrombosis, the source of infection is first removed and broad-spectrum antibiotics to cover Gram-positive and Gram-negative agents as well as anaerobes are started and changed according to culture and sensitivity reports<sup>(7,8)</sup>. The role of systemic anti-coagulation in an infected thrombus is controversial except for clot propagation or septic emboli.

Surgery is indicated for associated deep-space neck infections, carotid sheath involvement (to prevent extension into the carotid artery), intra-luminal abscess and failed medical treatment. However, medical treatment might be

slow<sup>(6)</sup>. A number of procedures have been described in the literature and include drainage of collections, debridement of necrotic tissue and even ligation or excision of the IJV<sup>(8,9)</sup>.

In our patient we found it appropriate to use anticoagulation in the form of subcutaneous heparin for 3 days followed by oral warfarin for 6 weeks as has been mentioned previously. Strict monitoring of the coagulation profile along with regular Doppler ultrasonography of the neck was done to monitor the progress of the patient and watch for secondary infection. In the absence of infection and other complications described above, neither antibiotics, nor any form of surgical intervention were required.

## CONCLUSION

IVJ thrombosis is a rare complication following neck surgery especially if the surgery has been short and has not involved extensive tissue dissection or handling of the IJV. Hence, it requires a high degree of clinical suspicion to diagnose non-infected IJV thrombosis in the post-operative period, especially after simple neck surgery. Early recognition is important for prompt treatment and for prevention of complications. Doppler ultrasound is a simple, easily available and inexpensive diagnostic tool in this situation. Systemic anticoagulation used in most patients is also associated with occasional complications and needs meticulous monitoring of the patient. Our patient is regularly following up for the last 4 months and has not developed any complications.

## References

1. Quraishi HA, Wax MK, Granke et al.: Internal jugular vein thrombosis after functional and selective neck dissection. *Arch Otorhinolaryngology*; 1997; 123(9): 969-73.
2. Carpenter JP, Holland GA et al.: Magnetic resonance venography for the detection of deep venous thrombosis: comparison with contrast venography and duplex Doppler ultrasonography. *Journal of Vascular Surgery*; 1993; 18(5): 734-741.
3. Shameem M, Akhtar J et al.: Internal jugular vein thrombosis – a rare presentation of mediastinal lymphoma. *Respiratory Medicine CME*; 2010; 3 (4): 273-275.
4. Daver GB, Bakshi GD et al.: Cystic lymphangioma in an adult. *Bombay Hospital Journal*; 2005; 47: 1.
5. Mueller DK, Dacey MJ et al.: Internal jugular vein thrombosis, *eMedicine*; Sep 2009. <http://emedicine.medscape.com/article/461577-overview>
6. Jonas N, Fagan J: Internal jugular vein thrombosis: A case study and review of the literature. *The Internet Journal of Otorhinolaryngology*; 2007, Volume 6, Number 2
7. Lemierre A: On certain septicemias due to anaerobic organisms. *Lancet*; 1936; 1: 701-703.
8. Kristensen LH, Prag J: Human necrobacillosis, with emphasis on Lemierre's syndrome. *Clinics of Infectious Diseases* 2000; 31: 524-532.
9. Tovi F, Fliss DM et al.: Septic jugular thrombosis with

abscess formation. Annals of Oto-Rhino Laryngology 1991; 100 (8): 682-84.

**Author Information**

**Prajakt V v, DNB FMAS**

Assistant Professor, Department of General Surgery, K J Somaiya Medical College, Hospital and Research Center

**Nilay Chakrabarty, MS**

Professor and Head of Department, Department of General Surgery, K J Somaiya Medical College, Hospital and Research Center

**Ratnakar Shetty**

Honorary Consultant, Department of General Surgery, K J Somaiya Medical College, Hospital and Research Center

**Abhay Jain, DNB**

Student Senior Registrar, Department of General Surgery, K J Somaiya Medical College, Hospital and Research Center