

Sigmoid Volvulus: A New Twist to an Old Problem

S Ward, D Khan, T Edwards, I Daniels

Citation

S Ward, D Khan, T Edwards, I Daniels. *Sigmoid Volvulus: A New Twist to an Old Problem*. The Internet Journal of Surgery. 2010 Volume 27 Number 2.

Abstract

Reports of a volvulus (twisting) of the sigmoid colon can be found in a papyrus from ancient Egypt. However, sigmoid volvulus represents a spectrum of disease across the globe from young men in central Africa to the elderly institutionalised patients in Western Europe and the USA. As the population ages the prevalence of sigmoid volvulus is likely to rise. As an acute presentation, it represents a multidisciplinary challenge in its management, because whilst surgery is a definitive cure, this has to be balanced against co-existing morbidity. In the chronic or recurrent case, definitive treatment must again be tailored to the 'fitness' of the patient to minimise an acute recurrence with its inherent increased morbidity and mortality. In this review we have looked at the results of the published series for the different management options, which may be surgical or endoscopic. We have proposed an algorithm for the management of an acute or chronic sigmoid volvulus within the multidisciplinary team setting.

INTRODUCTION

The management of sigmoid volvulus in the elderly patient still poses a complex problem despite decades of study with treatment options evolving everyday [1]. The 'gold standard' of treatment is surgical resection, which is often not ideal for the frail, elderly patient that this disease normally affects. In this review article we will look at the treatment options and demonstrate evidence for our proposed algorithm for this disease management.

Sigmoid volvulus is not a new condition. The ancient Ebers papyrus describes the natural history of sigmoid volvulus as either reducing spontaneously, or the sigmoid colon being 'rotted'. Volvulus was a common cause of obstruction amongst the Greeks and Romans, the words ileus (Greek) for intestinal obstruction, or acutum tormentum (Latin) meaning twisted appear in the ancient texts, and are now well-recognised medical terms. The Greek physician Soranus defined ileus as 'a severe and dangerous twisting of the intestines.' Up until the 19th century, the condition was often referred to as 'iliac passion' because of the severe abdominal pain – the characteristic symptom of gut ischaemia [2,3].

EPIDEMIOLOGY

The sigmoid colon is the most common site of volvulus in the gastrointestinal tract, accounting for up to 6% of all intestinal obstructions [2]. There is age and sex predilection, being more common in men (63.7% of 571 patients) with the

lower incidence in women being attributed to a wider pelvis. A racial trend has also been noted with 67% of those affected by the condition being black Afro-Caribbean [2]. There has proven to be two global patterns of disease: In the Western world sigmoid volvulus is a disease of the sixth decade. It is thought to be caused by sigmoid elongation, which results in a redundant loop of large bowel. Conditions predisposing to disorders of bowel movement such as chronic constipation and abdominal distension have been implicated in its aetiology [4,5].

In the elderly, this presentation is most commonly seen as a result of long-term neurological or psychiatric disease. Neuro-psychiatric disorders have been reported in up to 71% of cases in individual series [2,6,7]. Psychotropic drugs or sedatives that interfere with colonic motility have been implicated as well as the association with Parkinson's disease, multiple sclerosis and spinal cord paralysis.

The high incidence in nursing homes and mental institutions led to the description of the condition as the "Bedford Syndrome", where a high proportion of psychiatric patients were reported as developing sigmoid volvulus (over 50% in some series) [14,15].

In other parts of the world, the disease occurs 15-20 years earlier, and the pattern is different. In Brazil, the condition occurs in 10% of patients with a megacolon secondary to Chagas' disease and in Africa a high fibre diet has been

implicated as a significant factor in the development of the disease [16].

PATHOPHYSIOLOGY

Many theories for the cause of sigmoid volvulus have been proposed over the centuries, each unique to the group of patients described, but they can all be united by a single mechanism.

The British surgeon Cullen, in 1777 [8], believed it was caused by ‘spasmodic contraction’ whereas Good, in 1824, [9] believed that there was a strong inverse peristalsis causing the bowel to be ‘twisted into nooses and knots [14] [15].’ However, the German pathologist von Rokitsky recognised that the main predisposing factor was a ‘congenital or acquired long, loose and flabby mesentery [10].’ Further descriptions are provided by Esau in 1875 [11] and Treves [12], who outlined the necessary predisposing factors; “the loop must be of considerable length, the mesocolon must be long and very narrow at its parietal attachments, so that the two ends of the loop may be brought as close together as possible.” Whilst Treves appreciated that this anatomical finding may be congenital, he recognised that in the young it was extremely rare [11, 12].

Classically, sigmoid volvulus is described as occurring in a clockwise direction, and it occurs in the face of three factors:

1. Elongation of the sigmoid colon;
2. Narrowing of the base of the sigmoid mesocolon at its parietal attachment
3. A torque force to the sigmoid colon, which initiates the torsion process.

As the sigmoid colon twists on its mesenteric axis, both ends are occluded resulting in a closed-loop obstruction. Bowel gas can enter this closed loop, but is unable to escape. This results in bowel dilatation and further tightening of the twist, ultimately compromising blood supply to the bowel, resulting in ischaemia and perforation [7].

In Western cultures chronic constipation results in an overloaded sigmoid loop, whose weight provides the momentum to initiate the volvulus. In African and Middle Eastern societies, a high-fibre diet results in a bulky sigmoid colon that provides the necessary impetus [17,18]. A shift in the relative positions of the intra-abdominal organs, as seen in pregnancy or in the presence of large pelvic tumours, may shift the relative positions of the intra-abdominal organs and

also precipitate an episode of sigmoid volvulus [19].

The base of the sigmoid mesocolon becomes foreshortened as a result of repeated episodes of torsion. Many of these episodes are sub-acute and self-limiting, and patients rarely seek medical attention (over 50% of patients presenting with volvulus give a history of previous episodes) [7]. However, as a result of foreshortening of the mesocolon, the narrow base acts as a fulcrum, about which the sigmoid colon may twist. In addition, adhesive bands develop between the two limbs of the sigmoid, creating a paddle-like configuration and this chronic “meso-sigmoiditis” is visible in the root of the sigmoid mesentery in most patients in whom a sigmoid volvulus occurs.

In acute sigmoid volvulus, the degree of torsion varies; from 180° (35% of cases) to 540° (10% of cases) but 360° torsion is seen in 50% of patients [2]. The common form of volvulus around the mesenteric axis usually is sited 15-25cm from the anus and is, therefore, easily accessible by rigid sigmoidoscopic examination and is amenable to decompression in the acute setting.

CLINICAL PRESENTATION

Sigmoid volvulus classically presents with the insidious onset of chronic abdominal distension, followed by vague lower abdominal discomfort, then absolute constipation, and finally vomiting – the four cardinal signs of bowel obstruction. This typical presentation is only seen in 30-50% of patients [7, 14] with a further 50% of patients presenting with diarrhoea in the early stages of the disease [7]. The symptom of vomiting often occurs late; however, if present in the early stages it may indicate a more severe presentation associated with increased morbidity and mortality [17,20].

Examination of the abdomen usually reveals a tympanitic abdomen, and a palpable mass may be present - often on the right side of the abdomen. The presence of a systemic inflammatory response syndrome (SIRS) or sepsis suggests that the colon is ischaemic or perforated and urgent surgical assessment and treatment is warranted. Rectal examination will only reveal an empty rectal ampulla. Prognosis is dependent on early recognition and prompt intervention [2, 7, 15]. Often patients are elderly and incapacitated, and obtaining an accurate and reliable history can be difficult. The clinician must therefore have a high index of suspicion for diagnosing sigmoid volvulus in at-risk groups.

The differential diagnoses includes an ileosigmoid knot. The ileosigmoid knot is a rare but serious abdominal emergency

in which the ileum and sigmoid entangle each other to form a knot, which may lead to vascular compromise and gangrene of both the ileum and sigmoid colon. It is also important to recognise that there is a true obstruction and not a pseudo-obstruction with megacolon. Pseudo-obstruction or Ogilvie's Syndrome is also characteristic in the elderly population and is a flaccid dilatation of the colon and often is a secondary phenomenon to other pathologies.

DIAGNOSTICS

Plain abdominal radiograph is the most basic mode of radiological investigation where a classic 'coffee bean or U-loop' sign can be demonstrated; however, other signs of varying specificity have been described [16,17]. One study evaluated the plain abdominal radiographs of patients thought clinically to have a sigmoid volvulus [18]. Strict diagnostic criteria based on the findings at barium enema and/or surgery were applied to establish or refute a diagnosis of sigmoid volvulus. The presenting plain abdominal radiographs were assessed for ten radiological signs considered valuable in the diagnosis of sigmoid volvulus, and of the seventeen patients with a volvulus, 88% had more than five signs. Five signs achieved significance in differentiating between the groups, but three signs, (apex of the loop under the left hemi-diaphragm, inferior convergence on the left and the left flank overlap sign) were 100% specific as well as being highly sensitive. However, it is worth noting that on plain abdominal x-ray films the diagnosis of sigmoid volvulus was difficult to make in one third of patients (Figure 1).

Diagnostic difficulties may occur with plain abdominal radiographs if the degree of proximal dilatation is so marked that the sigmoid loop may not be recognized as such. Similar difficulties may be encountered when a large amount of fluid is associated with a small amount of air. This situation causes poor definition of the sigmoid colon on a supine radiograph, and the high air-fluid level demonstrated on erect images may be inadequate to define the sigmoid loop accurately. Diagnostic accuracy may vary from 30-90% on plain films, dependent on who reports the images [7].

Contrast enemas: If there is concern as to the nature of the obstruction, for example if an obstructing neoplasm is suspected or pseudo-obstruction is to be confirmed, then a contrast enema using water-soluble contrast is recommended. This investigation is contraindicated in patients with suspected peritonitis, gangrenous bowel, or pneumoperitoneum.

Computed Topography: A dilated colon with an apparent air/fluid level may be noted on CT. Other characteristic signs have been reported which may prove beneficial in diagnosing equivocal cases on an abdominal plain film [24]. If the axis of twisted bowel and mesentery are perpendicular to the scanning plane, a 'whirl sign' can be seen [25]. Other reported findings include a 'bird-beak' aspect of the afferent and efferent segments [26].

MANAGEMENT OF A VOLVULUS

The management of sigmoid volvulus has evolved over the decades from one requiring immediate surgical correction, which carries high mortality, to one of immediate sigmoidoscopic reduction and elective surgery with its attendant lower mortality [15]. Essentially, the initial management question is to exclude suspected ischaemia;

The presence of ischaemic colon needs immediate treatment with surgical excision being the only option. Ischaemia should be suspected in those patients with fever, raised white blood count, and pain disproportionate to the clinical signs (the classic symptom of ischaemic bowel). These patients require urgent surgical referral, together with pre-operative assessment and optimisation by the anaesthetists or intensivists. In these patients there is no role for conservative treatment, except for those cases where extensive co-morbidity or the wishes of the patient mean that palliation is more appropriate than surgical intervention. In the presence of gangrene, resection of the bowel with formation of an end colostomy or primary anastomosis can be performed. It is important to note that emergency surgery for ischaemic bowel has an average mortality of 38%, eight times higher than those patients with viable bowel [27]. A review of 43 studies (comprising 2228 patients) showed that the mortality of those with viable bowel was 12.3%, but where the bowel is gangrenous, a mortality of 52.8% can be expected [2]. The management option of non-ischaemic volvulus would be colonoscopic derotation in all cases of acute, uncomplicated sigmoid volvulus, followed by semi-elective single-stage colonic resection or colopexy [2,29].

A MULTITUDE OF TREATMENT OPTIONS

Non-surgical methods to achieve reduction have been performed for many years. Even from the time of Hippocrates, reduction of the volvulus using a long suppository "10 digits long" into the rectum was described. This mode of deflating the volvulus was suggested once again by an English physician named Gay in 1859, but did not gain widespread acceptance until the middle of the next

century. In the latter part of the 20th century, percutaneous deflation of the loop using trochars was described by Crisp, who performed his studies in cadavers, but in 1947 Bruusgaard revived the technique of transanal deflation using sigmoidoscopy, and reported an 86% success rate [3]. In recent times, the use of the flexible sigmoidoscope or colonoscope provides a further weapon in the armamentarium of the surgeon attempting non-operative reduction of the sigmoid loop. Increasingly ingenious methods of reaching high obstructions are employed, such as lassoing a flatus tube onto the side of a flexible endoscope [30].

Although decompression is achieved in over 70% of patients [2], the recurrence rate is high, with studies quoting rates varying between 20-90 % [15, 16, 29, 33, 27]. One of the ways in which recurrence can be prevented, is by leaving a rectal tube in place for 5-6 days following decompression. However, evidence for this as a successful treatment option is weak.

Operative intervention for sigmoid volvulus can take many forms, from de-torsion to resectional surgery either with a primary anastomosis or a Hartmann's procedure. Trying to identify which procedure is the most successful is difficult as the mortality rates reported in the literature relate to the many different surgical procedures, as well as both elective and emergency surgery.

Operative de-torsion without resection has been recommended by many as the primary surgical intervention when non-operative decompression cannot be performed. Mortality was quoted at 14 % in one study with the major criticism being recurrence of the volvulus occurring in 18% [35].

In the past 10 years, another historic treatment for sigmoid volvulus has gained popularity, with the renewed description of percutaneous deflation of the sigmoid loop by Salim et al. [37]. The authors describe a 100% success rate using percutaneous deflation of the sigmoid loop, followed by per-anal intubation and elective band sigmoidopexy. This regime was attended by 0% mortality and 5% morbidity, compared with 13% morbidity and 13% mortality with conventional sigmoidoscopic reduction and elective sigmoid resection [37].

Percutaneous endoscopic colostomy (PEC) is another new technique that has evolved as a treatment of recurrent sigmoid volvulus. A colonoscope is inserted into the left

colon per rectum until trans-illumination is seen through the skin surface and finger pressure indents the colon. Under local anaesthesia, two standard 16-Ch percutaneous gastrostomy tubes are pushed through the abdominal wall into the bowel and then secured against the abdominal wall to anchor the sigmoid colon in two places. The colonoscope is reinserted to check the final position of the catheters, which are then attached to drainage bags and flushed twice daily. Antibiotics are administered for five days postoperatively and the tubes can be in situ for the long term or short term (figure 2). PEC offers an alternative treatment for patients who have tried conventional treatment options without success or in whom open resection may be contraindicated (such as the frail, elderly or severely immunocompromised patients). One series by Daniels et al. [38], describes the use of the technique in 14 patients (mean age: 78 years) with recurrent sigmoid volvulus in whom surgical resection was not felt to be appropriate. PEC may further be refined in future cases with use of magnetic image guidance. Previously, the position of the sigmoid loop was estimated, but now coils embedded within the colonoscope producing a pulsed low-voltage magnetic field can be used to calculate and display the exact position of the scope within the bowel [33]. This improves accuracy and safety of this technique.

Sigmoid resection or colectomy are the definitive treatment for all sigmoid volvulus. However, the timing of resection following non-operative or operative decompression has attracted debate. Deferred, semi-elective surgery is associated with greatly reduced morbidity and mortality. In one study the mortality rate of elective resection following sigmoidoscopy was 7.6%, whereas the mortality rate for emergency primary resection and Hartmann procedure were 16.6% and 37.5%, respectively [41]. Indeed, same admission semi-elective resection minimises surgical complications and hastens convalescence [15, 17].

TO OPERATE OR NOT TO OPERATE?

After successful endoscopic deflation, the question then arises, whether or not subsequent surgery is required. Simple deflation, without operative fixation or resection is followed by subsequent episodes of volvulus in over 50% of patients, with its own complications and mortality [15]. Bak, who cited a 6% operative mortality, compared to a mortality of 30% from recurrent episodes of volvulus, advocated elective resection, during the same hospital stay, and many papers have followed suit [18, 31]. However, these results were disputed in another series, which cited an operative mortality

of 15% from resection after the first episode, yet a lower mortality (9%) from recurrent episodes of volvulus requiring surgery [42]. The authors further stratified their patients according to age (< 70, and > 70 years of age) and found, not surprisingly, that two thirds of the deaths occurred in the older population [42]. They concluded that resection should be performed after the first episode only in patients under 70 years of age and in patients older than 70 years, resection should be deferred until the second or subsequent episode. The lower operative mortalities for recurrent episodes were attributed to an increase in the blood supply as a result of recurrent episodes of volvulus. The experience of Arnold et al. can be alternatively interpreted in that elderly (>70 years old) debilitated patients may not live long enough to develop another episode of volvulus, hence removing themselves from the equation. However, the risk of this assumption is that the less debilitated septuagenarians may survive long enough to experience one or many further episodes. If resection is performed only in this healthier subgroup, the operative mortality will naturally be lower. Therefore, candidates for elective resection should be selected not only on basis of greater or less than 70 years of age, but on the usual cardio-respiratory and metabolic criteria, which determine fitness for surgery.

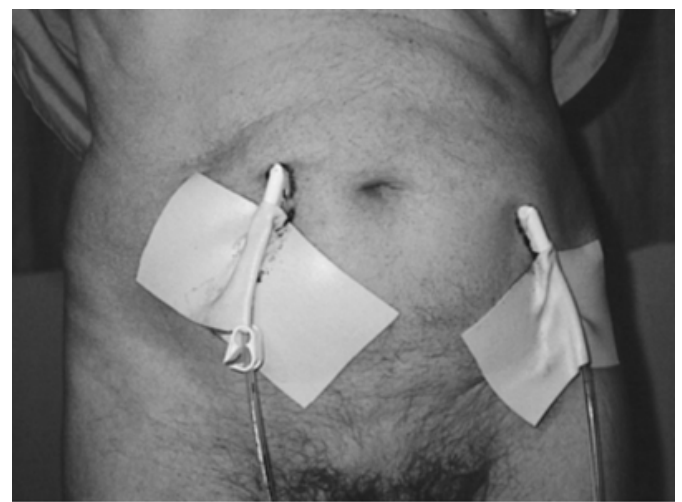
Figure 1

Figure 1. The typical appearance of a sigmoid volvulus on a plain abdominal film. The classic 'omega' or 'coffee-bean' loop is seen arising in the left iliac fossa with its apex in the right upper quadrant. Faeces can be seen in the caecum and ascending colon and there is a paucity of gas in the rectum and distal sigmoid colon

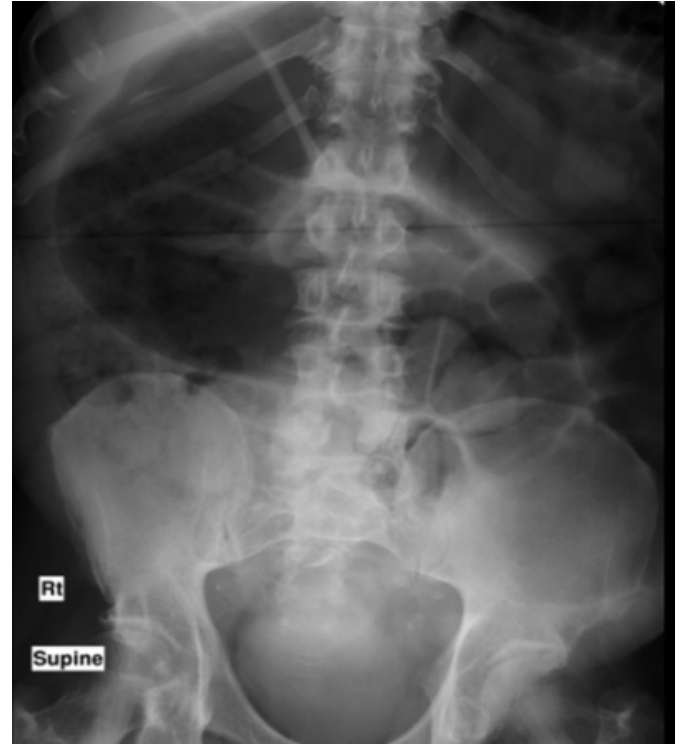

Figure 2

Figure 2. Endoscopic placement of two PEC tubes can be seen here. The tubes are classically well separated, one fixed at the apex, the other proximally to prevent further rotation. Recurrent volvulus following PEC placement is seen if the tubes are inserted too close to the base of the mesentery.



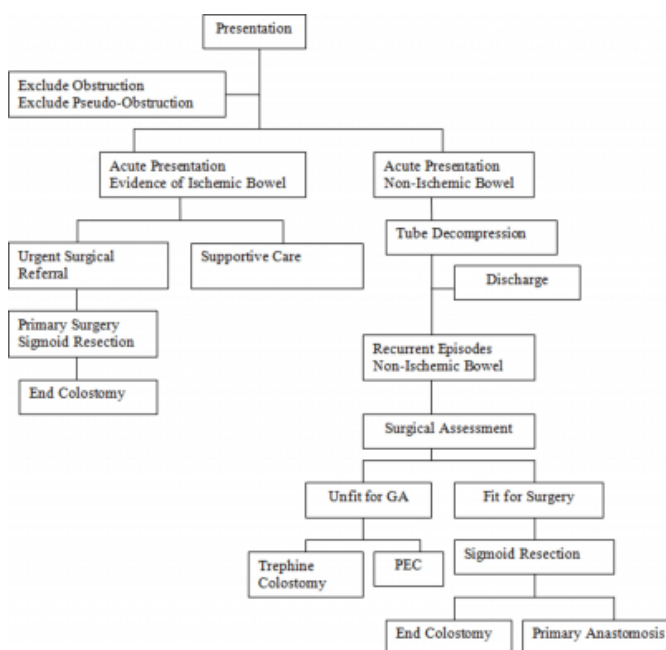
CONCLUSIONS

Volvulus of the sigmoid colon is not a new condition and in the Western world tends to occur in those who are elderly with significant co-morbidities. There has been a shift in recent times from emergency surgical intervention to the use of the flexible sigmoidoscope or colonoscope to decompress the colon; however, given the high recurrence rate following decompression, further intervention is still required.

Sigmoid volvulus with gangrenous bowel requires excision, but the management of the non-ischaemic cases and recurrent episodes is more controversial. We have devised an algorithm for the management of this condition and included in this, the PEC technique that may be a useful treatment modality in those who are frail and elderly. Only occasionally, in patients with advanced age, lack of bowel symptoms, and multiple co-morbidities, may surgical repair not be considered.

Figure 3

Table 1. Our proposed algorithm for the management of sigmoid volvulus.



KEY POINTS

- In the Western world, sigmoid volvulus is predominantly a disease of the elderly.
- In a third of patients it can be difficult to make the diagnosis on plain abdominal x-rays alone.
- Decompression via sigmoidoscope is successful, but carries a high recurrence rate.

- Gangrenous bowel requires immediate surgical excision.
- PEC may be an alternative treatment for recurrent sigmoid volvulus in those patients who are not appropriate for surgical intervention.

ACKNOWLEDGEMENT

We would like to thank Mr JNL Simson FRCS for allowing us to use the image in Figure 2.

References

1. Madiba TE and Thomson SR: The management of sigmoid volvulus. *J R Coll Surg Edinb*; 2000; 45: 74-80.
2. Ballantyne GH: Review of sigmoid volvulus. Clinical patterns and pathogenesis. *Dis Colon Rectum*; 1982; 25(8): 823-30.
3. Ballantyne GH: Review of sigmoid volvulus: history and results of treatment. *Dis Colon Rectum*; 1982; 25(5): 494-501.
4. Morrissey TB and Deitch EA: Recurrence of sigmoid volvulus after surgical intervention. *Am Surg*; 1994; 60: 329-331.
5. Strom PR, Stone HH and Fabian TC: Colonic atony in association with sigmoid volvulus: its role in recurrence of obstructive symptoms. *South Med J*; 1982; 75: 933-936.
6. Mangiante EC, Croce MA, Fabian TC, Moore OF 3rd, Britt LG: Sigmoid volvulus. A four-decade experience. *Am Surg*; 1989; 55(1): 41-4.
7. Tiah L, Goh S: Sigmoid volvulus: diagnostic twists and turns. *Eur J Emerg Med*; 2006; 13(2): 84-87.
8. Cullen W: First lines of the practice of a physick. 1777, Edinburgh: William Creech.
9. Good J: The study of medicine with a physiological system of nosology. 1824, Philadelphia: Bennett and Walton.
10. Rokintansky K: A manual of physical anatomy. 1849, London: Sydenham Society.
11. Esau, Ueber Achsendrehung des Darms, Achsendrehung der Flexura sigmoidea, kolossale Dilatation derselben mit ausgedehnten Einrissen ihrer Serosa und Ringmuskulatur. *Dtsch Arch Klin Med*; 1875; 16: 474.
12. Treves F: Intestinal obstruction, its varieties with their pathology, diagnosis and treatment. 1884, Philadelphia: Henry C. Lea's Son & Company.
13. Pool RM and Dunavant WD: Volvulus of the sigmoid colon. *Ann Surg*; 1951; 133(5): 719-26.
14. Ronka EK: The incidence of volvulus of the sigmoid colon and its treatment in a psychiatric Veterans Administration Hospital--"the Bedford Syndrome". *Mil Med*; 1965; 130: 184-6.
15. Safioleas M et al.: Clinical considerations and therapeutic strategy for sigmoid volvulus in the elderly: A study of 33 cases. *World J Gastroenterology*; 2007; 13 (6): 921-924.
16. Habr Gama A, Haddad J, Simonsen O, et al.: Volvulus of the sigmoid colon in Brazil: a report of 230 cases. *Dis Colon Rectum*; 1976; 19: 314-320.
17. Heiss AH et al.: Sigmoid Volvulus in the Middle East. *World J Surg*; 2008; 32: 459-464.
18. Alam MK et al.: Surgical management of colonic volvulus during same hospital admission. *Saudi Med J*; 2008; 29(10): 1438-1442.

19. Connolly MM., Unti JA and Nora PF: Bowel obstruction in pregnancy. *Surg Clin North Am*; 1995; 75(1): 101-103.
20. Raveenthiran V: Observations on the pattern of vomiting and morbidity in patients with acute sigmoid volvulus. *J Postgrad Med*; 2004; 50: 27-29.
21. String ST and DeCosse JJ: Sigmoid volvulus: an examination of the mortality. *Am J Surg*; 1971; 121: 293-297.
22. Feldman, D: The coffee bean sign. *Radiology*; 2000; 216(1): 178-179.
23. Raveenthiran V: Emptiness of the left iliac fossa: a new clinical sign of sigmoid volvulus. *Postgrad Med J*; 2000; 76: 638-641.
24. Agrez M and Cameron D. Radiology of sigmoid volvulus. *Dis Colon Rectum*; 1981; 24(7): 510-4.
25. Shaff MI et al.: The whirl sign: a CT finding in volvulus of the large bowel. *J Comput Assist Tomogr*; 1985; 9(2): 410.
26. Catalano, O: Computed tomographic appearance of sigmoid volvulus. *Abdom Imaging*; 1996; 21(4): 314-7.
27. Madiba TE and Thomson SR: The management of sigmoid volvulus. *J R Coll Surg Edinb*; 2000; 45(2): 74-80.
28. Renzulli P et al.: Preoperative colonoscopic derotation is beneficial in acute colonic volvulus. *Dig Surg*; 2002; 19: 223-229.
29. Alver O et al.: Internal herniation concurrent with ileosigmoid knotting or sigmoid volvulus: Presentation of 12 patients. *Surgery*; 2005; 137(3): 372-7.
30. Piers ACG and Elton C: Endoscopic placement of flatus tube using "lasso" technique with snare wire. *World J Gastroenterol*; 2006; 12 (36): 5902-5903.
31. Bak MP and SJ Boley: Sigmoid volvulus in elderly patients. *Am J Surg*; 1986; 151(1): 71-5.
32. Siroospour D and Berardi R: Volvulus of the sigmoid colon: A ten-year study. *Dis. colon & Rectum*; 1976; 19(6): p535-541.
33. Lau KCN et al.: A study of large-bowel volvulus in urban Australia. *Can J Surg*; 2005; 49(3): 203-207.
34. Ballantyne GH et al.: Volvulus of the colon. Incidence and mortality. *Ann Surg*; 1985. 202(1): 83-92.
35. Jagetia A et al.: Sigmoidopexy (tube sigmoidostomy) as definitive surgical procedure for sigmoid volvulus. *Indian J Gastroenterol*; 1998. 17(4): 129-30.
36. Akgun Y: Mesosigmoidoplasty as a definitive operation in treatment of acute sigmoid volvulus. *Dis Colon Rectum*; 1996. 39(5): 579-81.
37. Salim AS: Percutaneous deflation and colopexy for volvulus of the sigmoid colon: a new approach. *J R Coll Surg Edinb*; 1990. 35(6): 356-9.
38. Daniels IR et al.: Recurrent sigmoid volvulus treated by percutaneous endoscopic colostomy. *Br J Surg*; 2000; 87(10): 1419.
39. Witherspoon P, Wright DM: Three-dimensional magnetic image guided percutaneous endoscopic sigmoidopexy for the treatment of recurrent sigmoid volvulus. *Colorectal Disease*, 2010, 12, 72-73.
40. Alhindawi R, Kelly N. and Holubar S: Incisionless Hartmann's procedure: an innovative minimal access technique for surgical treatment of sigmoid volvulus in debilitated patients with faecal incontinence. *Tech Coloproctol*; 2008; 12: 337-339.
41. Dulger M et al.: Management of sigmoid colon volvulus. *Hepatogastroenterology*; 2000; 47(35): 1280-3.
42. Arnold FC and Nance GJ: Volvulus of sigmoid colon. *Ann Surg*; 1973; 177: 527-537.

Author Information

SL Ward, MB ChB BSc(Hon)

Royal Devon and Exeter NHS Foundation Trust

D Khan, MRCS

Royal Devon and Exeter NHS Foundation Trust

T Edwards, MRCS

Royal Devon and Exeter NHS Foundation Trust

IR Daniels, FRCS

Royal Devon and Exeter NHS Foundation Trust