

# Airway management in a case of critical sub-glottic stenosis: The use of a preformed tracheal tube

N Venugopal, M Youssef, S Nortcliffe

## Citation

N Venugopal, M Youssef, S Nortcliffe. *Airway management in a case of critical sub-glottic stenosis: The use of a preformed tracheal tube*. The Internet Journal of Anesthesiology. 2007 Volume 15 Number 2.

## Abstract

A 34 year old woman with critical fibrotic sub-glottic stenosis secondary to Wegener's granulomatosis presented with worsening dyspnoea and stridor. She was posted for an urgent tracheostomy under general anaesthesia as she refused to consent for tracheostomy under local anaesthesia despite medical advice. Airway was successfully managed with a 4.0 mm preformed tracheal tube and tracheostomy was performed uneventfully.

## INTRODUCTION

Wegener's granulomatosis is a rare form of vasculitis affecting 8-9 / one million adults [1]. It is a multi-system disease and airway involvement occurs in 15-20% of the cases [2]. We report a case of critical fibrotic sub-glottic stenosis secondary to Wegener's posted for an urgent tracheostomy.

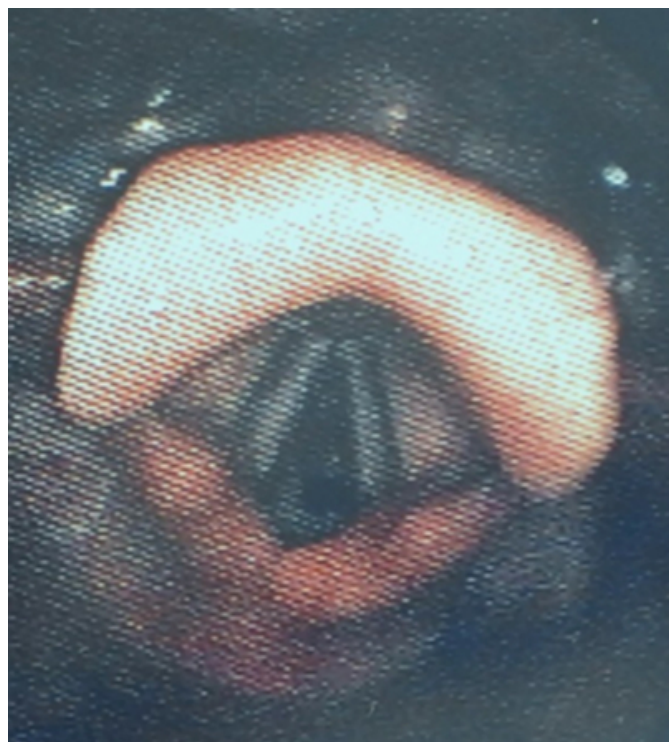
## CASE HISTORY

A 34 year old female, diagnosed with Wegener's granulomatosis 2 years before, presented with worsening dyspnoea and stridor. She had pulmonary and joint involvement and suffered recurrent respiratory tract infections. Her exercise tolerance was greatly reduced and her previous pulmonary function tests showed a restrictive pattern. Nasal endoscopy performed by the ENT surgeons under local anaesthesia showed nasal mucosal crusting, nasal bridge collapse and sub-glottic fibrous stenosis (Fig.1, 2). CT scan of the neck showed mild thickening of vocal cords and critical narrowing of subglottic larynx. Sagittal reconstruction of CT showed the stenosis which extended for 1.5 cms at about 1 cm below the level of cords and the internal tracheal diameter was reduced to 4mm at the point of critical narrowing (Fig.3). She was posted for an urgent tracheostomy under anaesthesia to relieve airway obstruction. The options for anaesthesia were awake tracheostomy under local anaesthesia or inhalational induction. She refused to consent for the procedure to be performed under local anaesthesia despite anaesthetic advice. Risks and complications of anaesthesia especially, the devastating effects of losing the airway were explained.

In the anaesthetic room, she was positioned at a 40° head-up tilt on the operating table with full monitoring. After 5 min pre-oxygenation, anaesthesia was induced with 100 % Oxygen and Sevoflurane. Video laryngoscopy (Karl-Storz endoscope) was performed with the patient breathing spontaneously. Lignocaine was sprayed onto the vocal cords and beyond. The Portex 4.0 mm ID tracheal tube with its length of 21 cm was not long enough to reach below the whole segment of subglottic stenosis. Hence, an uncut, uncuffed Portex 4.0 mm ID preformed north facing tube with its length of 24 cm, straightened with a stylet was used. Magill's forceps assisted in guiding the tube beyond the stenotic region. There was no leak around the tube on positive pressure ventilation.

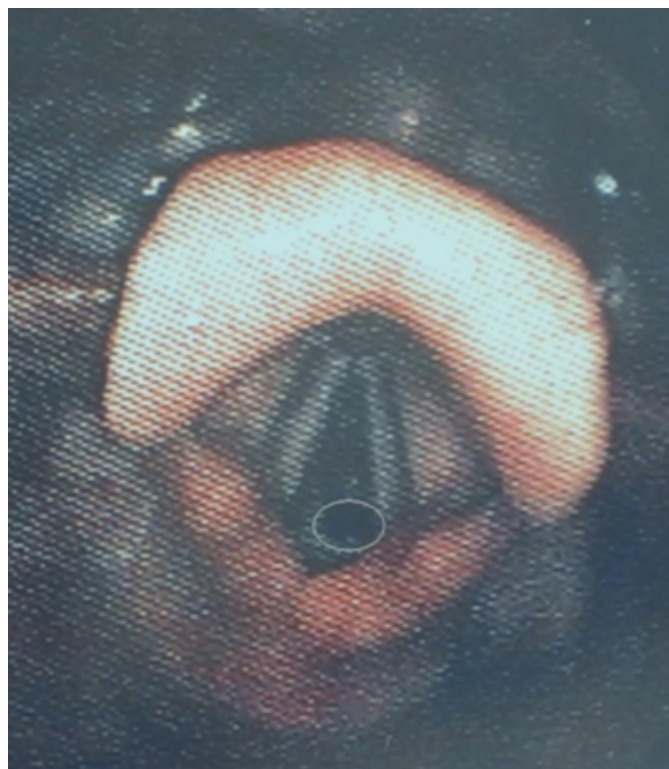
**Figure 1**

Figure 1



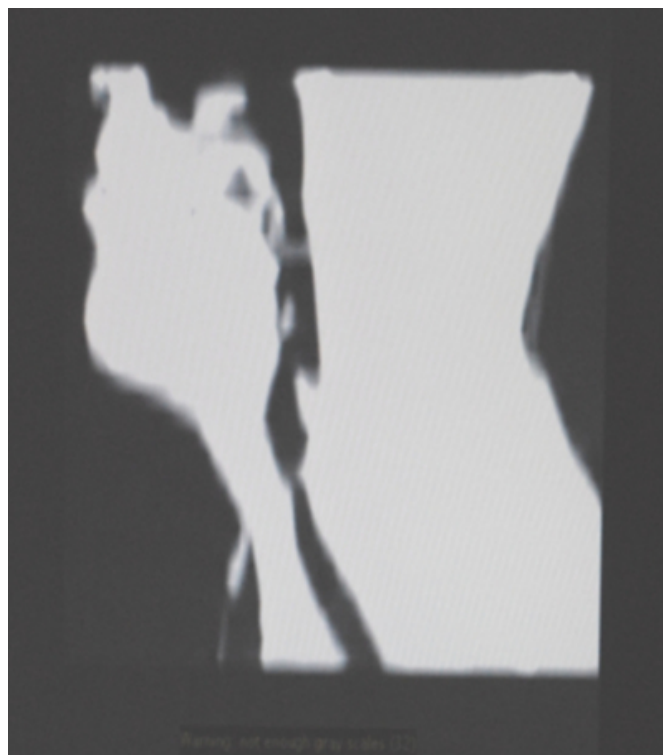
**Figure 2**

Figure 2



**Figure 3**

Figure 3



The surgeon infiltrated 1 % Lignocaine with 1:200,000 Adrenaline before the incision and tracheostomy was performed successfully. Recovery from anaesthesia and surgery was uneventful.

## **DISCUSSION**

Wegener's granulomatosis is an idiopathic systemic vasculitis, characterized by the formation of necrotising granulomas of the respiratory tract, in addition to focal or proliferative glomerulonephritis. The vasculitis affects small to medium sized vessels. Classically, Wegener's granulomatosis involves a three organ systems: the upper respiratory tract, the lungs, and the kidneys [1]. Laryngeal involvement in Wegener's granulomatosis typically involves the subglottis and upper trachea. Incidence of subglottic stenosis is 15% to 20%, with higher incidence in women and patients < 20 yrs. [2]

The goal of treatment of subglottic stenosis in Wegener's granulomatosis is to eradicate airway obstruction, ideally avoiding tracheostomy and its possible complications. Medical treatment is the preferred option. Mild lesions usually respond to treatment with immunosuppressants [3]. Fixed lesions are treated surgically. The surgical modalities are serial tracheal dilatations, laser resection of the subglottic tissue, stenting and laryngotracheal reconstruction. Stents are

not typically used in Wegener's granulomatosis as excessive granulation tissue may cause obstruction. [4] The most frequent surgical approach is a combination of intralesional injection of methylprednisolone acetate and intratracheal dilatation. [4]

In this patient the options for safely securing the airway were limited.

Intravenous induction has the potential for the loss of airway during induction and is considered unsafe.

Awake fiberoptic intubation had 2 distinct disadvantages.

1. Coughing and distress during the procedure could cause turbulent flow, further airway obstruction and a cycle of decline.
2. Passage of the fiberoptic scope and tube through the subglottic narrowing might hinder spontaneous ventilation (cork in the bottle effect).

Jet ventilation relies on patent upper airway for expiration.

The obstruction to expiration at the laryngeal level heightened the risk of developing increased intrathoracic pressures and tension pneumothorax. There was also the risk of carbon dioxide retention, so jet ventilation was relatively contraindicated. Hence, we adopted the inhalational induction technique.

The paediatric tube was short as its length is only 21cms. In this patient it did not reach beyond the stenotic region. Therefore, a long (24cms), preformed north facing RAE tube was used over a stylet.

## **References**

1. Erickson-Vanessa-R, Hwang-Peter-H. Wegener's granulomatosis: Current trends in diagnosis and management. Current opinion in otolaryngology & head and neck surgery 2007; 15: 170-6.
2. Gluth-Michael-B, Shinnars-Patrick-A, Kasperbauer-Jan-L. Subglottic stenosis associated with Wegener's granulomatosis. The Laryngoscope 2003; 113:1304-7.
3. Watters-Karen, Russell-John. Subglottic stenosis in Wegener's granulomatosis and the nitinol stent. The Laryngoscope 2003; 113: 2222-4.
4. Hoffman GS, Thomas-Golbanov CK, Chan J, et al. Treatment of subglottic stenosis, due to Wegener's granulomatosis, with intralesional corticosteroids and dilation. The Journal of Rheumatology 2003; 30: 1017-21.

**Author Information**

**Naveengopal Venugopal, FRCA**

Department of Anaesthetics, Manor Hospital

**Mamdou Youssef, FRCA**

Department of Anaesthetics, Manor Hospital

**Sally Ann Nortcliffe, FRCA**

Department of Anaesthetics, Manor Hospital