

Primary Myeloid Sarcoma of Urinary Bladder

D Pan, Y Tay, S Appu, M Frydenberg

Citation

D Pan, Y Tay, S Appu, M Frydenberg. *Primary Myeloid Sarcoma of Urinary Bladder*. The Internet Journal of Urology. 2010 Volume 8 Number 2.

Abstract

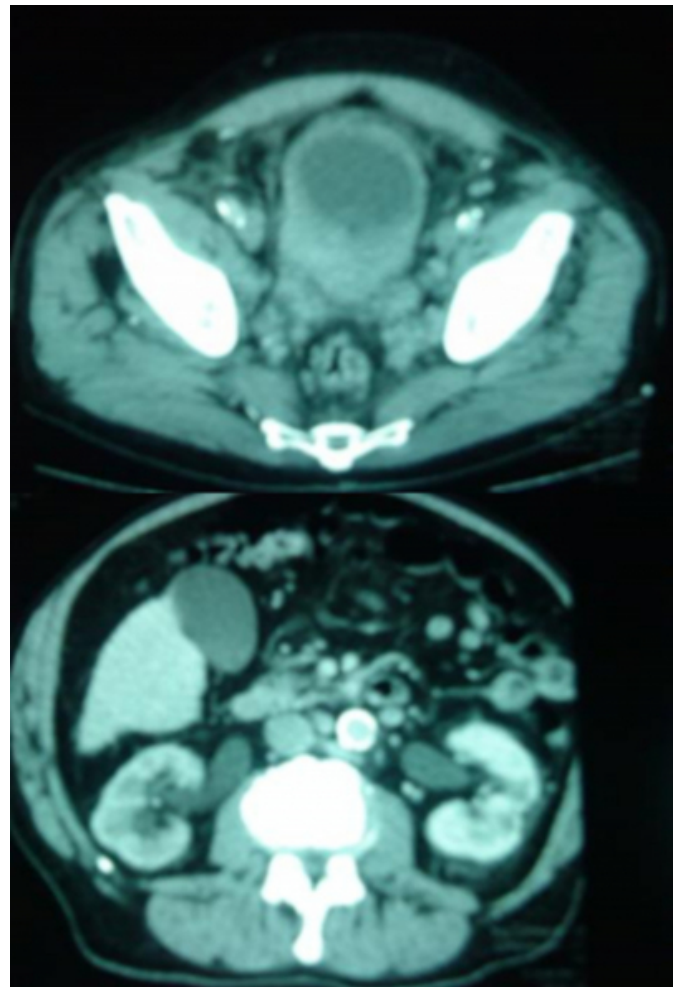
Leukaemia is a systemic disease affecting both haematological system and extra-medullary sites alike. Myeloid sarcoma has been defined as a localised tumour mass of immature cells of granulocytic lineage in extramedullary sites. Myeloid sarcoma usually occurs with or after the onset of systemic leukaemia but much rarely before it. Localised myeloid sarcoma presenting before the onset of systemic leukaemic disease has been termed primary myeloid sarcoma. The most common extra-medullary sites affected by myeloid sarcoma are the central neurological system and the testes. The kidneys are the most common genitourinary organ affected by myeloid sarcoma, however, urinary bladder can be involved. Here we report a rare case of primary myeloid sarcoma of urinary bladder.

CASE

A 79 years old man with a past history of atrial fibrillation, hypertension and gastric reflux presented with one-week history of painless haematuria, incontinence and lower urinary tract symptoms. On examination, there was a palpable mass in the suprapubic area extending to the umbilicus. Rectal examination demonstrated a fixed pelvic mass and a normal prostate. His renal function was impaired with a creatinine level of 166 mg/dL. Serum PSA was within the normal range at 2.5 ng/ml. A CT-scan of his abdomen and pelvis revealed bilateral hydronephrosis, a thickened bladder wall and pelvic lymphadenopathy (Figure 1). Initial management included bilateral percutaneous nephrostomy and indwelling catheter insertion. His renal function improved quickly and he proceeded to cystoscopic resection biopsy. Intra-operatively the bladder was grossly abnormal with extensive tumour noted throughout the bladder, with an oedematous mucosa and a firm yellow lamina propria and muscle layer. The bladder was of small capacity of approximately 50mLs. Examination under anaesthesia revealed a hard rigid malignant pelvis.

Figure 1

Figure 1

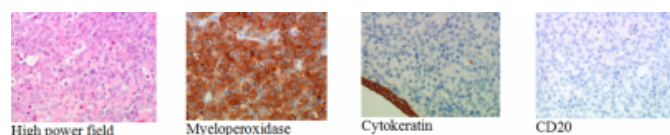


Pathology revealed acute myeloid leukaemia of the bladder.

Bone marrow biopsy was normal. A diagnosis of extra-medullary presentation of leukaemia, otherwise known as myeloid sarcoma was reached. (Figure 2.)

Figure 2

Figure 2



The patient declined to receive chemotherapy but underwent 16 Gy of radiotherapy over four fractions to control his local symptoms. His bilateral urinary obstruction responded partially to radiotherapy for a short period of time, allowing removal of percutaneous urinary diversion. The patient was treated conservatively and passed away 3 months later from renal failure.

DISCUSSION

Myeloid sarcoma is a tumor composed of cells of myeloid lineage derivation, or myeloblasts. It is an extra-medullary manifestation of acute myeloid leukaemia. This rare entity was first described by Burns in 1811 and referred to as chloroma by King in 1853 due to its characteristic green color given by myeloperoxidase. The term chloroma was replaced by granulocytic sarcoma in 1966 by Rappaport. (13) The term myeloid sarcoma was recently favored. (17) Myeloid sarcoma most commonly present as complication of acute myeloid leukaemia however, rarely it can present before any evidence of systemic leukaemia. This is termed primary myeloid sarcoma. In majority of reported cases, system leukaemic disease follows after a mean period of 7 months (18) hence myeloid sarcoma should be regarded as heralding manifestation of systemic disease and treated as such.

The most common form of leukaemia affecting genitourinary tract is acute lymphoblastic leukaemia and less commonly acute myelocytic leukaemia. The kidneys are the most commonly involved genitourinary organs in patients with myeloid sarcoma and the pattern of involvement is commonly bilateral. Myeloid infiltration of the urinary bladder is very rare. It usually occurs in children however it can affect octogenarians (5). There is a male dominance of 2:1. Bladder infiltration with myeloid cells is seen usually in the setting of primary localised disease and there has been no report in the literature of patient presenting with relapsing leukaemia affecting the bladder.

Most common presenting symptom of primary myeloid sarcoma of bladder is haematuria. This occurs because of diminution in the number of platelets with increased capillary permeability or stasis of the smaller blood vessels with rupture and haemorrhage caused by local infiltration. Occasionally patient presents with suprapubic pain, obstructive symptoms and upper urinary tract compromise. There are a total of 13 cases in the literature describing leukaemic infiltration of the bladder and of those, 4 cases had primary myeloid sarcoma of the urinary bladder (Case 2,3,8,13). (Table 1)

Figure 3

Table 1: Summary of 13 cases of leukaemic infiltration of the bladder

Case	Ref	Age(Y)	Sex	Type	Treatment	Survival	Other organs involved
1	2	19	Male	ALL	Unknown	5 days	Bone marrow
2	4	13	Female	AML	Chemotherapy	unknown	Bone marrow
3	5	9 months	Male	AML	Unknown	Unknown	Stomach, intestine, kidney
4	5	81	Male	ALL	Unknown	Unknown	Bone marrow, kidney
5	1	4	Female	ALL	Chemotherapy	14 months	N/A
6	6	18	Male	ALL	Unknown	65 hours	Heart, lung, kidney, spleen, bone marrow
7	7	69	Female	Follicular lymphoma	Radiotherapy	Unknown	Nil
8	8	13	Male	AML		3 days	Bone marrow
9	8	9	Female	ALL	Chemotherapy	unknown	Bone Marrow
10	8	5	Male	ALL	Radiotherapy	6 months	Bone marrow
11	10	60	Female	B- CLL	Chemotherapy	Unknown	Nil
12	10	67	Female	B- CLL	Chemotherapy	Unknown	Nil
13	14	36	Male	AML	Chemotherapy Radiotherapy	16 days	Nil

So far there is no effective therapy for myeloid sarcoma of bladder and it carries a poor prognosis. It is not known whether the prognosis of localized bladder leukaemia differs from disseminated disease but it should always be treated as early manifestation of more sinister systemic disease. Control of local disease is achieved with combination of endoscopic bladder resection and palliative radiotherapy. Systemic chemotherapy with agents such as cytoxan, vincristin, chlorambucil and fludarabine are used to defer the onset of systemic leukaemia following diagnosis of myeloid sarcoma. Long-term survival beyond 6 months with systemic disease is poor. Due to the rarity of the disease there is no well-defined chemotherapy regime specific for myeloid sarcoma.

CONCLUSION

Primary myeloid sarcoma of bladder is an extremely rare disease. It should be regarded as initial manifestation of systemic leukaemia disease and treated as such with chemotherapy. Local symptoms should be palliated with a combination of endoscopic resection and radiotherapy. Long-term survival of this disease is poor.

References

1. Troup CW, Thatcher G, Hodgson NB: Infiltrative lesion of the bladder presenting as gross hematuria in child with leukemia: case report. *J Urol*; 1972 Feb; 107(2): 314-315.
2. Pentecost CI, Pizzolato P: Involvement of the genito-urinary tract in leukemia, with the report of a case of involvement of the urinary bladder. *J Urol*; 1945; 53: 725.
3. Chang CY, Chiou TJ, Hsieh YL, Cheng SN: Leukemic infiltration of the urinary bladder presenting as uncontrollable gross hematuria in a child with acute lymphoblastic leukemia. *Journal of Pediatric Hematology Oncology*; 2003 Sep; 25(9): 735-739.
4. Persky L, Newman AJ, Tucker AS: Urologic manifestations of childhood leukemia. *J Urol*; 1972 Jun; 107(6): 1073-1077f.
5. Barney JD, Hunter FT, Mintz ER: The urologic aspects of radiosensitive tumors of blood forming organs. *JAMA*; 1932; 98: 1245.
6. Tribedi B.P: An unusual manifestation of lymphatic leukemia. *J Indian Med Assoc*; 1943; 12: 139.
7. Pontius EE, Myron HN, Paz L, McCallum DC: Primary malignant lymphomas of the bladder. *J Urol*; 1963; 90: 58-61.
8. Tucker AS, Persky L, Am J Roentgenol: Cystography In childhood. Tumors and pseudotumors; 1970; 107: 1073-1077.
9. Kirshbaum JD, Preuss FS: A clinical and pathologic study of one hundred and twenty three fatal cases in a series of 14400 necropsies. *Arch Intern Med*; 1943; 71: 777.
10. Ramadan KM, Kyle A, Mcmanus D: Urinary bladder infiltration with chronic B-lymphocytic leukemia: two cases with unusual presentation. *Leuk Lymphoma*; 2006 Jun; 47(6): 1184-1187.
11. Lall A, Webb NJA, Dickson A: Episodic painless hematuria of unusual etiology – case report and review of literature. *J pediatr Surg*; 2007 Aug; 42(8): 1460-2.
12. Rai Kr, Peterson BI, Appelbaum FR, Kolitz J, Elias L: Fludarabine compared with chlorambucil as primary therapy for chronic lymphocytic leukemia. *N Engl J Med*; 2000; 343: 1750-1757.
13. Tumors of the hematopoietic system, in Atlas of Tumor Pathology, Section3, Fascicle 8 Rappaport H, Washington, DC, Armed Forces Institute of Pathology, 1966; p241-243
14. Hilal A, Zafer B, Nesrin U, Mustafa O, Nukhet, T: Primary granulocytic sarcoma of the urinary bladder: case report and review of the literature. *Urology*; 2002; 60 (2): 345-346.
15. Yamauchi K, Yasuda M: Comparison in treatment of nonleukaemic granulocytic sarcoma. Report of two cases and a review of 72 cases in the literature. *Cancer*; March 2002; 94(6): 1739-1745.
16. Neiman RS, Barcos M, Berard C, Bonner H, Mann R, Fydell RE, Bennett JM: Granulocytic sarcoma: a clinicopathologic study of 61 biopsied cases. *Cancer*; 1981; 48: 1426-1437.
17. Chevallier P, Mohty M, Lioure B, Michel G, Contentin N, Deconinck E, Bordigoni P, Vernant JP, Hunault M, Vigouroux S, Blaise D, Tabrizi R, Buzyn A, Socie G, Michallet M, Volteau C, Harousseau JL: Allogeneic Hematopoietic Stem-Cell Transplantation for Myeloid Sarcoma: A Retrospective Study From the SFGM-TC. *J. Clin. Oncol*; 2008 Oct 20; 26(30): 4940-4943.
18. Byrd JC, Weiss RB: Recurrent granulocytic sarcoma: an unusual variation of acute myeloid leukemia associated with 8;21 chromosomal translocation and blast expression of the neural cell adhesion molecule. *Cancer*; 1994; 73: 2107-2112.

Author Information

David Pan

Urology Registrar, Southern Health, Monash Medical Centre

Yeng Kwang Tay

Urology Resident, Southern Health, Monash Medical Centre

Sree Appu

Urologist, Southern Health, Monash Medical Centre

Mark Frydenberg

Head of Urology Department, Southern Health, Monash Medical Centre