

Interactive Hand Clinics Number 1: Shrapnel injury to the arm with median and ulnar nerve dysfunction

D Power, A Martin

Citation

D Power, A Martin. *Interactive Hand Clinics Number 1: Shrapnel injury to the arm with median and ulnar nerve dysfunction*. The Internet Journal of Hand Surgery. 2006 Volume 1 Number 1.

Abstract

INSTRUCTIONS

The authors present a series of self assessment cases in hand surgery that demonstrate the many pathologies presenting to our tertiary referral hand unit. This case discusses the diagnosis and reconstructive strategy for a complex gunshot injury to the upper arm. Read the case report and accompanying questions and answer them in order. The solutions to the questions follow at the end.

CASE REPORT

A 26 year old soldier sustained a penetrating wound to the right upper arm at mid-humeral level whilst on active service in an international war zone. He was evacuated by helicopter support and taken to the nearest field hospital with surgical facilities.

Q1 What are the initial treatment priorities?

He was haemodynamically unstable with a pulse of 110 and a BP of 100/85. Respiratory rate was 18. He was noted to have pulsatile arterial bleeding from the exit wound on the medial side of the arm.

Q2 What are the important steps in investigating the injured limb?

He was noted to have reduced pulses at the wrist and capillary return in the hand was 2 seconds to all fingers.

Q3 What additional investigations are necessary?

Q4 What is the surgical priority in dealing with this injury in the field?

He underwent immediate surgical exploration under general anaesthesia and without a tourniquet. The brachial artery was found to be injured with a 50% division which explained the ongoing haemorrhage. A trial clamp was

applied proximally without loss of finger perfusion.

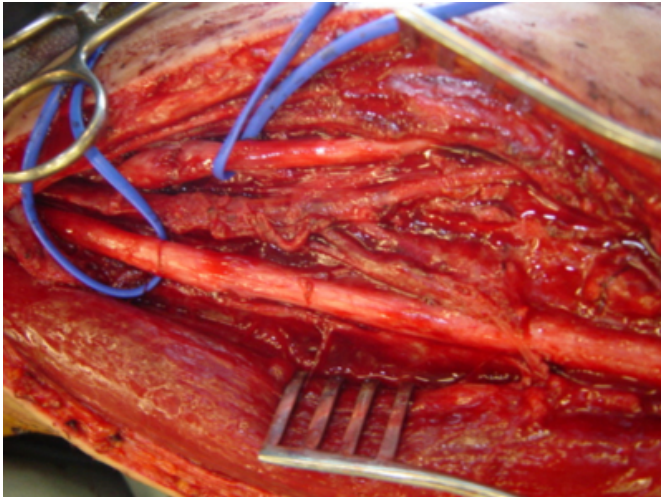
Definitive haemostasis was achieved by double ties to the artery above and below the level of injury. The median nerve was noted to be grossly intact. A second look was performed on the ward at 48 hours and the patient was repatriated to the UK.

Q5 What follow-up should be arranged?

He was seen in our Hand Unit at 5 days following the injury. He was noted to have clean entry and exit wounds. The distal arterial pulses were normal and the hand was well perfused. There was a subjective reduction in sensation in the median nerve distribution with mild weakness MRC grade 4/5 in the thenar muscles. The sensation in the ulnar nerve territory was absent and there was an early mild clawed posture in the ring and small fingers. In view of the documented injury to the brachial artery and the mechanism of injury, it was decided that early re-exploration was appropriate to document the extent of any nerve injury and to allow for early reconstruction should disruption be identified.

He underwent further surgical exploration without tourniquet 6 days after this injury. An extended anteromedial approach was used to identify the neurovascular structures above and below the zone of injury.

Figure 1



Q6 Describe the findings in the intra-operative photo?

The photograph shows the right arm viewed from the right side with proximal on left of picture.

Q7 How should this injury be treated at this stage?

The ulnar nerve was explored with internal neurolysis and the damaged fascicles resected. The injured fascicles represented approximately 20% of the nerve over a 2 cm length and numbered 3 fascicular disruption.

Q8 Which donor nerves are available for reconstruction?

Q9 Why should a sural donor nerve graft be reversed?

Q10 Describe rehabilitation and follow-up for this patient.

The wounds were closed directly and the patient made a good postoperative recovery without infection. Antibiotics were stopped 48 hours after wound closure. There is evidence of good recovery in the ulnar nerve with an advancing Tinel sign at 5 months. The median nerve recovery was full.

Shrapnel injury to the arm with median and ulnar nerve dysfunction

ANSWERS

Q1 What are the initial treatment priorities?

As when dealing with any trauma patient it is advisable to follow a treatment algorithm that will allow simultaneous assessment and treatment of life threatening injuries in the order of maximum priority. The ATLS system was used. Airway was patent and cervical spine was cleared clinically.

Oxygen was administered and breathing assessed. There was no evidence of torso injury. Haemorrhage control was obtained with external pressure applied to the wound with an iodine soaked pad. Intravenous access was obtained and fluid resuscitation commenced.

Q2 What are the important steps in investigating the injured limb?

The location, size and degree of contamination of the wound should be assessed. Pulses distal to the zone of injury should be palpated and documented as to normal or reduced volume or absence. Distal neurological status should be assessed and this should include motor and sensory function of all nerves passing through the zone of injury.

Q3 What additional investigations are necessary?

Radiographs of the zone of injury. These will identify bone injury, retained foreign material and shrapnel. Invasive angiography is not available in the field and is not necessary in cases of established vascular injury where surgical exploration is mandatory.

Q4 What is the surgical priority in dealing with this injury in the field?

The priority is to save life, then limb and to prevent infection. The artery may be safely tied after trial clamp because of the rich vascular anastomoses found around the elbow. This allows rapid arrest of haemorrhage. The entry and exit wounds should be debrided and the tract thoroughly irrigated. The wounds should be left open. In a civilian environment where it is unlikely that casualty numbers will swamp the surgical facilities and the surgical intervention is more controlled, vein graft interposition reconstruction of the brachial artery would be the gold standard.

Q5 What follow-up should be arranged?

The patient should be repatriated to a specialist Hand Unit for further wound care, assessment and follow-up. Copies of all clinical notes including the operative record, should be sent with the patient. The wounds should be inspected after a further 48 hours and if they remain clean, definitive closure should be recommended at about 1 week.

Q6 Describe the findings in the intra-operative photo?

The brachial artery lies thrombosed at the centre of the picture. The medial nerve lies below in the blue sloop and appears externally intact. The ulnar nerve has evidence of

partial neurotmesis and lies in the sloop at the top of the picture. There is no evidence of further tissue necrosis or infection.

Q7 How should this injury be treated at this stage?

The median nerve is most likely to have sustained a percussive injury and with near intact function is likely to resolve spontaneously. The Ulnar nerve injury is more severe. Internal neurolysis of the ulnar nerve will identify the extent of the injury and damaged fascicles may be resected and grafted as there is no infection.

Q8 Which donor nerves are available for reconstruction?

The sural nerves are the commonest nerves used for cable reconstruction of a mixed peripheral nerve. In this case the defect was small and only 3 fascicles needed to be grafted. A 6 cm piece of the distal posterior interosseus nerve at the wrist was harvested and used to bridge the defect with fibrin glue fixation.

Q9 Why should a sural donor nerve graft be reversed?

The sural nerve is a sensory nerve that has frequent branches. If used in an orthodromic alignment there is axonal escape of the regenerating axonal buds along side branches, without functional recovery. By reversing the graft, escape is eliminated and functional recovery is improved.

Q10 Describe rehabilitation and follow-up for this patient.

The wounds are closed and antibiotics stopped at 48 hours. Limited neural glide exercises are commenced. It is not necessary to fully immobilise the limb as the graft is partial. Glide reduces the perineural fibrosis that may impair neural recovery. The hand is rehabilitated with self administered daily passive range of motion exercises for the small joints within the hand. An anti-claw splint may be fitted to help in function. Education is important to reduce the risk of secondary injury to asensate trophic areas within the hand. Longterm follow-up is needed to establish full recovery. Sensory recovery will continue for 18 months. Should motor recovery be poor, a tendon transfer anti-claw procedure may be performed at a later date.

References

Author Information

D. M. Power

Department of Hand Surgery, Royal Orthopaedic Hospital

A. Martin

Birmingham Hand Service, Selly Oak Hospital