

Complex Seminal Vesicle Fistula: A Rare Complication Of Abdomino-Perineal Resection

S Raman, P Shah, A Joseph, R Davies, P Haray

Citation

S Raman, P Shah, A Joseph, R Davies, P Haray. *Complex Seminal Vesicle Fistula: A Rare Complication Of Abdomino-Perineal Resection*. The Internet Journal of Surgery. 2003 Volume 5 Number 2.

Abstract

Seminal vesicle fistula is a very rare and unusual complication of abdomino-perineal resection for carcinoma of the rectum. Persistent, discharging perineal sinus should prompt the clinician to consider this unusual entity in the remote post-operative period. Pre-operative radiotherapy may be a contributing factor. CT or MR sinography may prove to be a valuable investigational tool for delineating the fistulous tract. Here we report one such case that serves to highlight the nature of existence of this unusual complication in pelvic surgery.

INTRODUCTION

Abdomino-perineal resection for carcinoma of the rectum has been reported to cause a seminal vesicle fistula only twice previously^{1, 2}. The onset may be remote in the postoperative period. Here we report one such case that serves to highlight the nature of existence of this unusual complication in pelvic surgery that may impact on the management.

CASE REPORT

A 61-year-old gentleman was diagnosed to have a rectal cancer. This was a palpable, circumferential tumour extending from the dentate line to 7 cm proximally.

Pre-operative staging did not reveal any other synchronous or metastatic lesions. Three days following a short course (5 days, 25Gy) of pre-operative pelvic field radiotherapy, a standard abdomino-perineal resection with total mesorectal excision was performed. At laparotomy, the rectal tumour was mobile with no fixity to adjacent structures. There was no evidence of disseminated disease and no apparent intra-operative complications were encountered. The total operating time was 200 minutes with 600ml of blood loss. Recovery was uneventful and the patient was discharged on the 10th post-operative day. Histology showed a moderately differentiated, T3 N1 (1/6) M0 adenocarcinoma of the rectum. Post-operatively, he had weekly adjuvant chemotherapy with 5-fluorouracil for 6 months.

Subsequently, he was readmitted in the 7th post-operative week with a history of recent onset of purulent discharge

from the perineal wound. There were no associated urinary, bowel or systemic symptoms. Local examination, revealed three sinuses to the left of his perineal scar. Urine microscopy and culture was essentially normal.

Computed tomography, arranged to exclude a localised pelvic sepsis, revealed a suspicion of a complex fistula communicating between the prostate and cutaneous orifices. Subsequent sinography confirmed the complex nature of the fistula, which was found to communicate from the skin to a 3cm x 4cm cavity in the pelvis. This cavity was seen to drain into the contra-lateral (right) seminal vesicle and thereafter into the base of the prostate and the right vas deferens (Fig. 1 and 2).

Figure 1

Fig. 1: Sinography demonstrating the complex seminal vesicle fistula (arrowed)

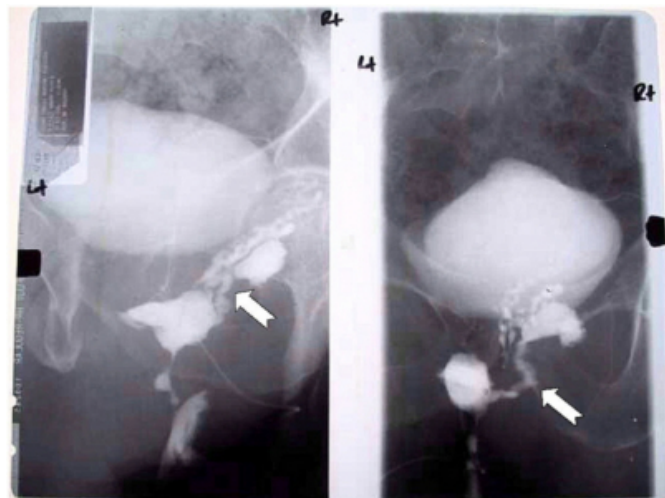
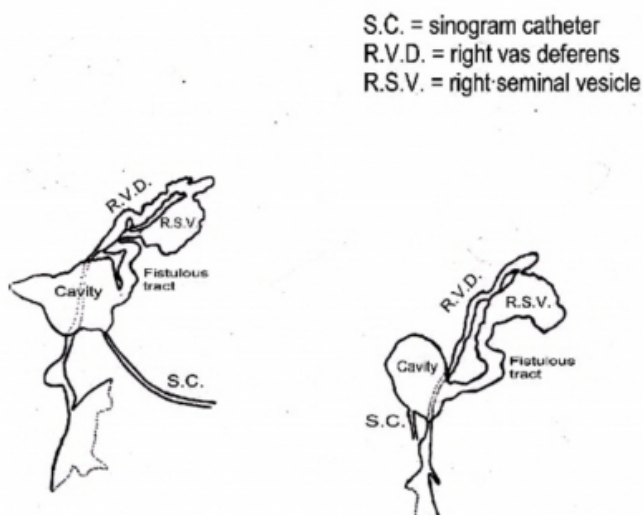


Figure 2

Fig. 2: Line diagram of the sinography as shown in Fig. 1



The patient was treated conservatively, as he denied further surgical intervention. The perineal discharge decreased gradually over a period of one year and he was noted to be asymptomatic during his second year follow up.

DISCUSSION

Urological complications after an abdomino-perineal resection are usually due to pelvic nerve damage resulting in neurogenic bladder, sexual dysfunction with impotence and retrograde ejaculation^{3, 4}. Unusual complications including direct injury to the bladder or urethra have also been reported⁵. Although seminal vesicle fistula is rare, injury to the seminal vesicles probably occurs more often than is

generally suspected⁶.

These fistulae may present as chronic and persistent discharging perineal sinuses late in the post-operative period without any associated clinical manifestations as was evident in our case². Patients can also present with systemic signs of pelvic sepsis or frequency, dysuria, occasionally pneumaturia, if there is communication with bowel^{1, 7, 8}. The fluid tends to be clear and may contain spermatozoa⁸.

In 1989, Goldman reported the first such case following a low anterior resection of rectum⁸. Post operatively, antibiotic induced colitis led to anastomotic dehiscence, abscess formation and subsequent fistulization of the seminal vesicle. It has also been reported secondary to Crohn's disease, immunosuppression, trauma, radiation fibrosis and scarring from previous pelvic surgery. The possible factors that may have contributed to development of this unusual complication in our case include pelvic irradiation, immuno-suppression from chemotherapy, and probably iatrogenic trauma during dissection of a large tumour deep in the pelvis.

Although simple sinography keeps an interesting place in the evaluation of the cutaneous sinus(es), sinography in combination with computed tomography is usually required to delineate the anatomy of the tract more precisely. Over recent years, magnetic resonance imaging has been shown to be helpful in complex perineal fistulae^{9, 10}.

Management of this condition is difficult. Spontaneous improvement with conservative approach, as in this case, has been reported previously. Proscar, a 5HT alpha-reductase enzyme inhibitor has been used in view of its ability to decrease the prostatic/ejaculate volume, though its efficacy remains to be proved¹. Transurethral endoscopic drainage of seminal vesicle using pigtail catheter has also been reported as one of the therapeutic options². Surgical re-exploration is likely to be difficult and may require plastic surgical procedures such as a scrotal inlay flap¹¹.

CORRESPONDENCE TO

Prof. P N Haray, MS, DNB, FRCS Department of General Surgery Prince Charles Hospital Merthyr Tydfil, S. Wales (UK) CF47 9DT Tel: 01685 728354 Fax: 01685 728649 Email: Mr.Haray@nglam-tr.wales.nhs.uk

References

1. Kollmorgen TA, Kollmorgen CF, Lieber MM, Wolff BG. Seminal vesicle fistula following abdominoperineal resection for recurrent adenocarcinoma of the rectum. Report

- of a case. *Dis Colon Rectum* 1994; 37(12): 1325-7.
2. Okubo K, Maekawa S, Aoki Y, Okada T, Maeda H, Arai Y. In vivo endoscopy of the seminal vesicle. *J of Urology* 1998; 159(6): 2069-70.
3. Janu NC, Bokey EL, Chapuis PH, Watters GR, Maher PO, Angstreich D. Bladder dysfunction following anterior resection for carcinoma of the rectum. *Dis Colon Rectum* 1986; 29(3): 182-3.
4. Boccon-Gibod L, Chiche R, Steg A. Urogenital complications of abdominoperineal resection of the rectum for cancer. *Ann Urol (Paris)* 1984; 18(3): 169-71.
5. Williams IM, Haray PN, Lloyd-Davies E, Foster ME. Bladder injury during laparoscopic abdominoperineal resection. *Br J Surg* 1995; 82(9): 1207.
6. Corman ML. *Colon and Rectal Surgery*. Lippincott-Raven (New York). 1998; Ch 23; Page 772.
7. Carlin J, Nicholson DA, Scott NA. Two cases of seminal vesicle fistula. *Clin Radiol* 1999; 54(5): 309-11.
8. Goldman HS, Sapkin SL, Foote RF, Taylor JB. Seminal vesicle-rectal fistula. Report of a case. *Dis Colon Rectum* 1989; 32(1): 67-9.
9. Shankar PJ, Haray PN. Pilonidal fistula-in-ano. *The Internet Journal of Surgery*. 2001; 3(1).
10. Tissot O, Bodnar D, Henry L, Dubreuil A, Valette PJ. Ano-perineal fistula in MRI. Contribution of T2 weighted sequences. *J Radiol* 1996; 77(4): 253-60.
11. McGuire EJ, Kozminski M, Wang SC. A scrotal graft technique for the repair of prostatic-cutaneous fistulas. *J Urol* 1989; 142(6): 1502-3.

Author Information

Sudarsanam Raman, MRCS

Clinical Research Fellow, Prince Charles Hospital

Parin R. Shah, MS, MRCS

Senior House Officer, Prince Charles Hospital

Anton Joseph, FRCS

Staff Grade Surgeon, Prince Charles Hospital

Rhodri A. Davies, FRCR

Consultant Radiologist, Prince Charles Hospital

Puthucode N. Haray, MS, DNB, FRCS

Consultant Laparoscopic and Colorectal Surgeon, External Professor of Coloproctology, Prince Charles Hospital, University of Glamorgan