

# Provision of High Frequency Jet Ventilation through a Tracheostomy Tube

M Attar, M Becker, J Van Looy, R Rock, S Donn

## Citation

M Attar, M Becker, J Van Looy, R Rock, S Donn. *Provision of High Frequency Jet Ventilation through a Tracheostomy Tube*. The Internet Journal of Pediatrics and Neonatology. 2006 Volume 7 Number 1.

## Abstract

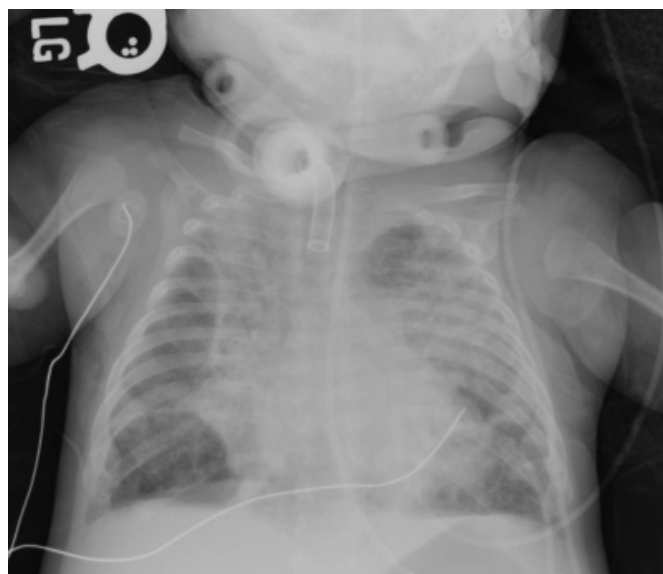We report the case of 4 month old infant, born prematurely at 27 weeks with respiratory distress syndrome, who developed severe bronchopulmonary dysplasia and pneumonia. The infant was dependent upon mechanical ventilation and underwent tracheostomy. Persistent hypoxemia and hypercarbia unresponsive to conventional ventilation led to the provision of high frequency jet ventilation (HFJV) directly through the tracheostomy tube (TT) using a novel method of attachment. We describe a new method to connect the jet ventilator to the TT.

## CASE REPORT

A 910 g male infant was delivered at 27 6/7 weeks' gestation by cesarean section to a multigravida mother whose pregnancy was complicated by pre-eclampsia. The mother received a course of betamethasone. Apgar scores were 3, 6, and 9 at 1, 5 and 10 minutes, respectively. He developed respiratory distress syndrome (RDS) treated with surfactant and mechanical ventilation. At 3 weeks, he received treatment for enterobacter pneumonia. He progressed to bronchopulmonary dysplasia (BPD) and was treated with diuretics, inhaled bronchodilators, and a prolonged 42 day course of dexamethasone. He was subsequently transferred from a community Neonatal Intensive Care Unit (NICU) to the regional subspecialty NICU at 101 days of age for a tracheostomy. Bronchoscopy revealed bilateral granulation tissue in the posterior commissure, in the interarytenoid space. A tracheostomy was performed. Subsequently, respiratory failure ensued while receiving conventional mechanical ventilation through a 3.0 Bivona (Smiths Medical, London, UK) tracheostomy tube, secondary to recurrent enterobacter pneumonia. He was switched to the SensorMedics 3100A High Frequency Oscillatory Ventilator (HFOV) (Viasys Healthcare, Yorba Linda, CA, USA) (Figure 1).

## Figure 1

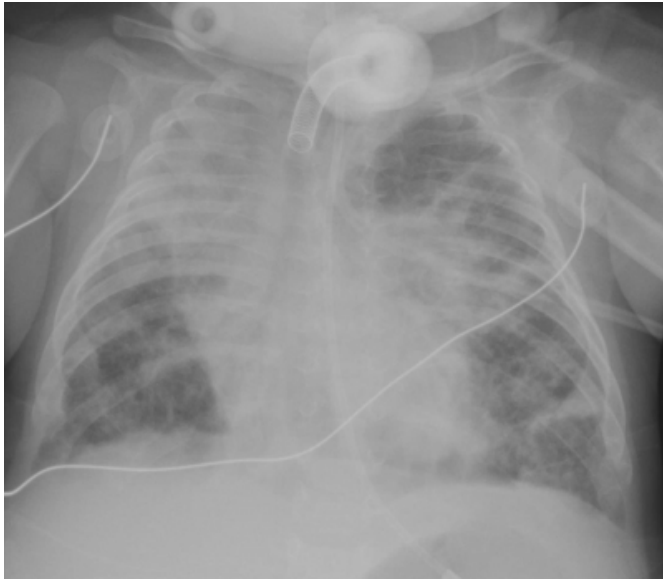
Figure 1: Chest radiograph obtained while receiving HFOV.



After a brief improvement, oxygenation deteriorated. He was then tried on the Life Pulse High Frequency Jet Ventilator (HFJV) (Bunnell Inc., Salt Lake City, UT, USA), using the volume strategy described by Keszler et al<sub>1</sub> (Figure 2).

### Figure 2

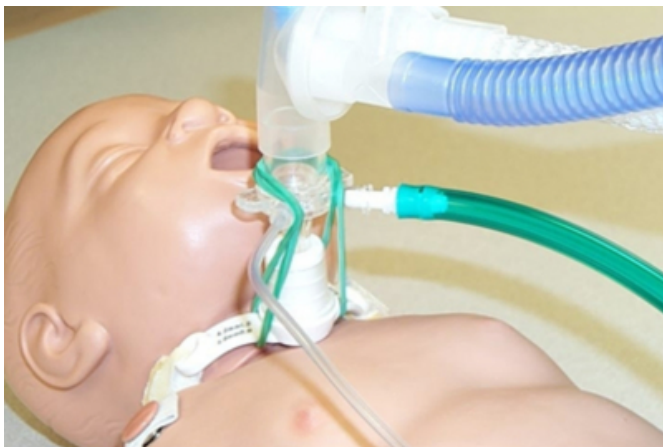Figure 2: Chest radiograph obtained after institution of HFJV.



Before HFJV could be provided, it was necessary to devise a method to connect the ventilator circuit directly to the tracheostomy tube. A review of the literature and consultation with colleagues failed to provide a precedent. However, we were able to find a means to connect the HFJV directly to a Bivona tracheostomy and Life Port endotracheal tube adapter (Bunnell Inc. Salt Lake City, UT) using a rubber band to stabilize the connection as shown in Figure 3.

### Figure 3

Figure 3 : Method for attaching the HFJV to the Life Port adapter and securing it to the tracheostomy tube using a rubber band.



The infant had a marginal improvement in oxygenation on HFJV but remained in need of 1.0 FiO<sub>2</sub>. After four days without improvement, a mutual decision to discontinue support was made between the parents and the care team in

consideration of the irreversible respiratory failure.

## DISCUSSION

High frequency ventilation (HFV) aims to achieve adequate gas exchange by delivering small tidal volumes at high frequencies to avoid the larger tidal volumes and lung expansion usually needed by conventional ventilation to achieve similar gas exchange goals.<sup>2</sup> HFJV and HFOV are two forms of HFV. Among the differences between these two forms of HFV is the mechanism of expiration. Expiration is active in HFOV, but it is passive and relies on the elastic recoil of the chest wall and lungs in HFJV.<sup>2</sup> HFJV is used to treat various forms of neonatal respiratory failure, including pulmonary interstitial emphysema (PIE), and pneumothorax.<sup>3, 4</sup> It is used to ameliorate or prevent neonatal lung injury and is an alternative rescue form of ventilation when acceptable gas exchange cannot be achieved with conventional mechanical ventilation or HFOV.<sup>5</sup> Infants with BPD may demonstrate increased collapsibility of the large airways during active expiration, supporting the theory that HFJV is a more suitable modality than HFOV for infants with BPD and respiratory failure.<sup>3, 6</sup>

The HFOV circuit can be attached to the TT without the need for a special adapter. However, the attachment of the HFJV to the TT has not been previously reported. One option for using HFJV in this infant with a tracheostomy included re-intubating the patient through the glottis as described by Donn et al.<sup>7</sup> However, endotracheal intubation might not be a practical choice in the presence of significant upper airway edema or an anomalous airway. The use of a trans-laryngeal 8F catheter was described as another way to provide brief pulmonary support with HFJV during laryngeal or tracheal operations, while leaving adequate surgical access during the operation.<sup>8</sup>

The Life Port endotracheal tube adapter gives the clinician the opportunity to provide HFJV using a standard single lumen endotracheal tube. We felt that this would be the safest approach for this patient, if we were able to find a reliable way to stabilize the connection between the Life Port adapter and the TT. Figure 3 demonstrates how this can be accomplished easily and simply with the use of a rubber band.

Friedlich et al have suggested that HFJV might be used as a rescue therapy for infants not responding adequately to HFOV.<sup>9</sup> We did find marginal improvement in oxygenation and equivalent ventilation in this infant with severe BPD and

pneumonia after the switch from the HFOV to HFJV. Infants who have undergone a tracheostomy can thus be effectively supported by HFJV without requiring laryngoscopy and re-intubation, using the methods of fixation described above.

### **ACKNOWLEDGEMENTS**

We thank JB Bunnell, ScD and DR Platt MS, RRT for their technical suggestions.

### **CORRESPONDENCE TO**

Attar, Mohammad A, M.D Address F5790 Mott Hospital,  
1500 E. Medical Center Drive, Ann Arbor, MI 48109-0254  
Phone Number (734)763-4109 Fax Number (734)763-2278  
E-mail Address mattar@umich.edu

### **References**

1. Keszler M, Modanlou HD, Brudno DS, et al. Multicenter controlled clinical trial of high-frequency jet ventilation in preterm infants with uncomplicated respiratory distress syndrome. *Pediatrics* 1997;100:593-9.
2. dos Santos CC, Slutsky AS. Overview of high-frequency ventilation modes, clinical rationale, and gas transport mechanisms. *Respir Care Clin N Am* 2001;7:549-75.
3. Keszler M. High-frequency Ventilation: Evidence-based Practice and Specific Clinical Indications. *Neoreviews* 2006;7:e234-249.
4. Keszler M, Donn SM, Bucciarelli RL, et al. Multicenter controlled trial comparing high-frequency jet ventilation and conventional mechanical ventilation in newborn infants with pulmonary interstitial emphysema. *J Pediatr* 1991;119:85-93.
5. Donn SM, Sinha SK. Minimising ventilator induced lung injury in preterm infants. *Arch Dis Child Fetal Neonatal Ed* 2006;91:F226-30.
6. Donn SM, Sinha SK. Invasive and noninvasive neonatal mechanical ventilation. *Respir Care* 2003;48:426-39; discussion 439-41.
7. Pryce CJ, Donn SM. Ventilatory casebook. Respiratory syncytial virus infection complicating bronchopulmonary dysplasia. *J Perinatol* 1991;11:390-3.
8. Koomen E, Poortmans G, Anderson BJ, Janssens MM. Jet ventilation for laryngotracheal surgery in an ex-premature infant. *Paediatr Anaesth* 2005;15:786-9.
9. Friedlich P, Subramanian N, Sebald M, Noori S, Seri I. Use of high-frequency jet ventilation in neonates with hypoxemia refractory to high-frequency oscillatory ventilation. *Journal of Maternal-Fetal & Neonatal Medicine* 2003;13:398-402.

**Author Information**

**Mohammad A. Attar, M.D.**

Department of Pediatrics and Communicable Diseases, University of Michigan Health System

**Michael A. Becker, RRT**

Department of Critical Care Support Services, University of Michigan Health System

**James Van Looy, M.D.**

Department of Pediatrics and Communicable Diseases, University of Michigan Health System

**Rob Rock, M.D.**

Department of Pediatrics and Communicable Diseases, University of Michigan Health System

**Steven M. Donn, M.D.**

Department of Pediatrics and Communicable Diseases, University of Michigan Health System