

Terminal, Vegetable-state Colon Cancer Patient Revived by Herbal Therapy: A Case Study

C Teo, C Im-Teo

Citation

C Teo, C Im-Teo. *Terminal, Vegetable-state Colon Cancer Patient Revived by Herbal Therapy: A Case Study*. The Internet Journal of Third World Medicine. 2005 Volume 3 Number 2.

Abstract

Poh (not the real name), a 54-year old female was diagnosed with Duke's C colon cancer. She underwent surgery, followed by radiotherapy and oral chemotherapy. She suffered severe side effects and consequently was unable to walk. She was confined to bed unable to move and was reduced to a state of vegetable. She was only bones and skin and was under palliative care. She was started on herbs and within three months she was able to walk and bounced back to a normal life.

DECLARATION OF INTEREST

The senior author is a practising herbalist and therefore has financial interest in the herbs mentioned in this article. However, please note that these herbs are not commercially available and has to be specially prescribed by the author.

INTRODUCTION

Colorectal cancer represents the third most common cancer we encountered at our centre in Malaysia. The disease affect both male and female (43.2% and 56.8% respectively). Our data also showed that this cancer predominantly affect those 50 years old and above. Our experience with colorectal cancer fairly reflects the world situation. In the US, colorectal cancer is also the third most common cancer affecting Americans. (1). According to the World Health Organization (WHO) lung cancer is the most common cancer worldwide, followed by cancer of the breast, and colorectal cancer (2).

CAUSES

Colorectal cancer is said to be a disease of the affluent societies. The causes of colorectal cancer are attributable to environmental factors (80%) and genetic predisposition (20%) (3). It is also said that a major cause of colorectal cancer is a diet rich in fat, refined carbohydrates and animal protein, combined with low physical activity. Epidemiological studies suggest that risk of colorectal cancer can be reduced by decreasing meat consumption (particularly processed meat) and increasing the intake of vegetables and fruit (2).

Diets high in fiber are associated with a decreased risk. The mechanism for protection by high-fiber diets may be related to less exposure of the colon lining to environmental carcinogens, as the transit time through the bowel is faster with a high-fiber diet than it is with a low-fiber diet (3).

TREATMENT

In Malaysia, surgery is the most popular, first line treatment for colorectal cancer, followed by chemotherapy and radiotherapy. It is claimed that for those with early stage disease which has not spread, surgery is curative. The five-year survival for this group of people is greater than 90%. However, not many people are so fortunate as to detect the cancer early enough. Most of the time (61% of the cases) the disease is detected or diagnosed too late. Once the cancer has metastasised to nearby organs (such as the lymph nodes, liver, etc.) the 5-year relative survival rate is less than 10% (1).

Radiation therapy is used as an adjunct to surgery. But its usefulness is limited as the small and large intestine do not tolerate radiation well (3).

Chemotherapy is a standard treatment after surgery. The drug 5-fluorouracil (5-FU) combined with leucovorin or levamisole is often used. For those who do not tolerate intravenous injection, oral drugs such as Xeloda or capecitabine or UFT (ftorafur and uracil) are used. Both these drugs are converted into the active form of 5-fluorouracil within the body (4).

The treatment with chemo-drugs after surgery is said to

reduce the rate of recurrence by about 17% and reduce mortality by about 13.5% as compared to surgery alone without chemotherapy (5). The work of Wolmark et al. (6) indicated that additional treatment with chemotherapy after surgery resulted in 8% increase of 5-year survival compared to surgery alone. However, chemotherapy does come with severe side effects and toxicity.

However, the analysis made by Morgan et al. (7) showed that the contribution of chemotherapy to the 5-year survival of patients with colon and rectum cancer was only 1.0% and 3.4% respectively.

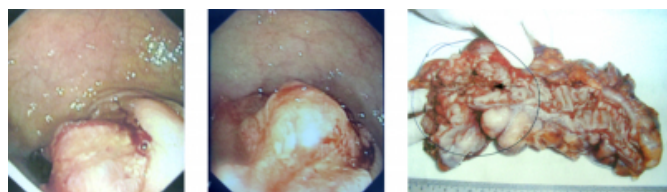
Given the above facts, we propose that there is a role of complementary therapy in the management of colorectal cancer. We also propose that the advantage of 17%, 6% or 1.0% due to chemotherapy may perhaps be replaced by herbal and diet-lifestyle change. This is not only cost-effective but is also free from severe chemotherapy-induced side effects. Complementary herbal therapy is one modality which we, in the developing nations, may wish to consider looking at seriously.

CASE PRESENTATION

Poh, 54-year old female, had a 14 cm tumour in her distal sigmoid colon (Figure 1). She underwent surgery. The cancer was staged as Duke's C. About two weeks after surgery, Poh underwent twenty-five times of radiation treatment and at the same time took the oral chemo-drug, Xeloda. Within a week after being on Xeloda, Poh became uncomfortable. Her heart beat was rapid and she had difficulty breathing. The doctor stopped her Xeloda and replaced it with UFT. Before Poh could even finish a course of UFT, her legs weakened and her entire person had lost strength. She could not walk and had to be confined to a wheelchair. MRI of her brain did not show any evidence of metastasis. There were, however, disc bulges at C5/C6, L3/L4, L4/L5 and L5/S1. This was diagnosed as lumbar spondylosis.

Figure 1

Figure 1: The tumour and the resected specimen.



Poh was under palliative care at a nursing home. She was indeed in bad shape. She was on morphine and had to lie

down in bed unable to move by herself. If she were to get up, she would feel breathless. At one time, she had to be admitted into the ICU for twelve days.

Poh's husband and son came to seek our help on 4 November 2005. With tears in his eyes, he related his wife's story. He said: After the surgery, my wife was alright. She was normal – she could walk around perfectly, could eat and do the normal chores in the house. It was only after she started radiotherapy and took the oral chemo-drugs that her condition deteriorated. This happened within about two months after the surgery.

The family spent about RM 50,000 for her treatment. With anger and frustration her husband said: To spend money is OK, but how could she end up like this. In total, Poh was a month in the hospital and another month in Pure Lotus Home existing as a living vegetable. There is no doubt that this episode is most upsetting for everybody.

The first thing I (Chris) suggested to the family was to move her out of the Lotus Home and bring her home. I suggested that the family take care of her diet, for eating anything you like is never the answer for cancer. The family did exactly as told and brought Poh home the next day. Poh was prescribed Capsule A, GI 1 and GI 2 and C-tea.

These were what happened after Poh started taking the herbs. Every conversation between Chris and her family members during each visit was videotaped.

04 November 2005: The family's first visit to us. Poh was in a "vegetable" state in Pure Lotus Home, unable to even move her head or legs. She was started on the herbs.

11 November 2005: She passed out black stools, sometimes she had diarrhea. For the first few days, she felt tired. Her feet were cold. Her appetite improved, and she was more alert and there was more oomph when she talked. By the end of the week, she was able to walk about ten steps. Take note: this was only about a week on the herbs.

18 November 2005: She was unable to feel any pain at this point in time. She passed out lots of stools, two to three times per day.

25 November 2005: She felt pains in her back. Feelings in both legs started to come back. Previously, both of her legs had no feelings. If provided with support, she was able to hold on to it and wake up by herself. Previously, she was unable to even turn her head or move her legs.

11 December 2005: She could sit up for at least an hour – if too long, she felt tired. She was able to get up from bed by herself. If given something to hold on, she was able to stand up by herself.

16 December 2005: She still could not walk by herself, but she was able to walk slowly with support.

13 January 2006: She had more strength. She could move around the house using a walking frame. She could do all her personal chores without help – bathing, dressing, etc.

3 February 2006: It was a great surprise, to see Poh walking slowly into our centre with the use of a walking frame. Her face appeared radiant. The following are excerpts of our conversation that Friday afternoon (Figure 2).

Figure 2

Figure 2: Poh was walking slowly towards Chris with the help of a walking frame.



Chris: If there is no walking frame, can you still walk?

Poh: Yes.

Husband: She is afraid that she will fall down.

C: When you walk, do you feel any pain?

P: No. My problem is the stoma (the hole that the doctor made in the abdomen to let the stool pass out). I cannot use the bag. I develop rashes and it gives me a lot of pain. Because of that I cannot sleep.

C: Oh, now you are not carrying any colostomy bag?

H: No, how to use it? If she uses it, the next day her skin

become swollen and she develop rashes. Her skin is very sensitive. Even using a plaster makes her skin turn red. The doctor gave zinc oxide – still not effective.

C: At night, you can you sleep?

P: Yes, I can sleep but with this stoma problem I cannot sleep well. Also because I was too long sleeping on my back, now feel “heaty” in the back and sometime it is a bit sore.

C: Now that you are able to sleep. Can you turn around and sleep on your left or right?

P: Yes, no problem – except when I turn to one side, the stoma gives me the problem. Before this, I was not able to turn at all. Even my legs, I need to have people move them for me. I could not move the legs by myself. After I took your herbs for about over one month, I was able to slowly move my legs. Then, I was able to sit up.

C: So, now you have no problem walking?

P: No problem except that I am afraid of falling. My legs are not very strong yet. When I stand for too long, the legs tremble. When I sit on too low a chair, I am not able to stand up by myself.

C: You have been lying in bed for two months, it will take time to recover.

P: No, not two months. In all, at least six months already.

H: Before going to the hospital, she was alright. Then she had her operation. She was still alright. But soon after the radiotherapy, around May 2005, problems started. Then about one month after she took the chemo-drugs all her muscles shrunk and seemed to disappear.

P: No flesh at all.

C: Now, you look good and fat.

P: Yes, I have put on a lot of flesh now.

C: You mean before taking the herbs, you were thin?

P: Yes, there was no flesh in my arms and legs. It was just skin hanging down the bone. But after I came home (from the Pure Lotus Home) within three months, I put on a lot of flesh now. Now, at home I can wake up by myself, I can eat and go to toilet and move around without having anyone to help me. Yes, I want to do everything by myself. This is my exercise.

C: You need time to recover, so take it easy for a while.
After all, your health is picking up and you are getting well.

As of this writing, Poh is doing well. She is able to do all her house chores and is regaining her health with each passing day.

Figure 3

Figures 3 & 4: Poh on 19 March 2006. She was able to walk without any need of a walking frame.



Figure 4



She was chatting with the author without any problem.

CORRESPONDENCE TO

Chris K. H. Teo Fax: 604-6580422 Email:
chris@cacare.com Website: <http://www.cacare.com>

References

1. http://www.cancer.org/docroot/CRI/content/CRI_2_4_1X_What_are_the_key_statistics_for_colon_and_rectum_cancer.asp Access 21 March 2006.
2. <http://www.who.int/dietphysicalactivity/publications/facts/cancer/en/> Access 21 March 2006.
3. http://www.healthatoz.com/healthatoz/Atoz/ency/colon_cancer.jsp Access 21 March 2006.
4. Wilkes, G.M and Ades, T. B. 2004. Consumers Guide to Cancer Drugs. American Cancer Society. Jones and Bartlett Publishers.
5. Moertel, C. G. et al. 1995. Fluorouracil plus levamisole as effective adjuvant therapy after resection of stage III colon carcinoma. *Annals of Internal Medicine* 122: 321-326.
6. Wolmark, N. et al. 1988 Postoperative adjuvant chemotherapy or BCG for colon cancer: results from NSABP protocol C-01. *J. National Cancer Inst.* 30: 30-36.
7. Morgan, G., Ward, R and Barton M. 2004. The contribution of cytotoxic chemotherapy to 5-year survival in adult malignancies. *Clinical Oncology* 16: 549-560.

Author Information

Chris K. H. Teo, Ph.D.

Care Care Project, Teo Herbal Centre

Chn'g Beng Im-Teo, B. Sc (Hons)

Care Care Project, Teo Herbal Centre