

Unexplained Unilateral Absence Of Fallopian Tube And Ovary

N Elkington, R Rahman

Citation

N Elkington, R Rahman. *Unexplained Unilateral Absence Of Fallopian Tube And Ovary*. The Internet Journal of Gynecology and Obstetrics. 2008 Volume 11 Number 2.

Abstract

Unexplained absence of an ovary and fallopian tube is a rare finding. Our case focuses on a 32 year old patient presenting with pelvic pain. The patient reported no history of previous abdominal surgery, significant medical problems and no history of menstrual irregularities or difficulties conceiving. In the past she had two vaginal deliveries, one complicated only by post nasal depression. A diagnostic laparoscopy revealed absent left fallopian tube and ovary. Otherwise the findings were normal. An abdominal ultrasound performed later confirmed the presence of both ureters and kidneys. Possible causes include congenital absence of both structures or absence secondary to asymptomatic tubal torsion.

INTRODUCTION

The congenital absence of one or both tube and ovary has rarely been discussed in literature. The probability of encountering such a finding has been quoted by one source as being one in 11241 females¹. There have been two possible causes suggested: congenital absence and asymptomatic tubal and ovarian torsion.

CASE REPORT

A 32 year old patient was referred by her general practitioner with an eighth month history of right sided pelvic pain, following a normal vaginal delivery at 42 weeks gestation. She had two normal deliveries and one spontaneous abortion at eleven weeks gestation. Other than mild asthma she had no significant medical history. There also appeared to be no significant gynaecological history; the patient denied any history of subfertility, Chlamydia or menstrual abnormalities and there was no record of any previous surgery.

The patient's pain appeared to be mainly midcycle and was associated with mild bowel disturbance. A transvaginal ultrasound scan revealed a slightly bulky uterus with early fibroid changes; the endometrium measured 3.3mm. A right ovary was visualized measuring 3.3 x 2.9 x 2.4 cm with multiple follicular cysts. The left tube and ovary were not seen. After initially being discharged back to her general practitioner, she was admitted for a day case diagnostic laparoscopy due to worsening symptoms of right sided pelvic pain.

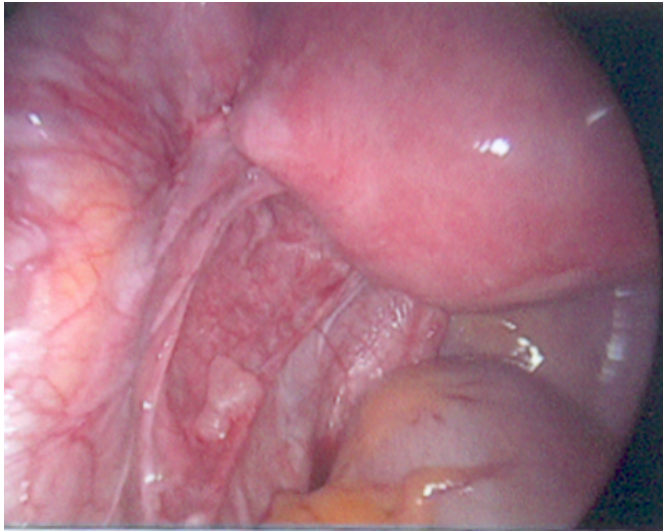
The procedure was performed on day 4 of her menstrual cycle. Examination under anaesthetic revealed a normal vagina, vulva and cervix. The uterus was examined and was felt to be of anteverted, mobile and to be normal size. A right adnexal mass was felt on palpation. Laparoscopy revealed a normal uterus with a small subserosal fibroid. The right ovary was present and appeared to have multiple follicles and the right tube was normal.

The left tube and ovary however were both absent (see figures 1). On close inspection there appeared to be no underlying pathology to account for it. Neither were there any remnants of the missing structures. All other pelvic organs inspected including bowel and liver appeared normal.

As there appeared to be no serious underlying pathology to explain this woman's pelvic pain, she was discharged back to her GP with an outpatient ultrasound scan, which excluded any renal tract abnormality.

Figure 1

Figure 1: Laparoscopic view of pelvis demonstrating absent tube and ovaries



DISCUSSION

The absence of one or both fallopian tubes or ovaries at laparoscopy has rarely been described. Two case reports were described at St. Thomas hospital in 1992 with similar findings. As in our case, the anomaly was discovered on routine laparoscopy². In a case report by the University of Padua, two possible explanations are given. The first being a congenital absence of either one or both tubes. This arises from a defect in the development of the mesonephric duct,

followed by a homolateral defect in the paramesonephric duct. This can result in the absence of not only the fallopian tube, but also the kidney and ureter. The second explanation given is an asymptomatic episode of tubal torsion. This could have occurred at any stage of the reproductive life of the woman. The torsion results in the eventual breakdown of the tube. Risk factors for tubal torsion include ovarian cysts, pregnancy, pelvic congestion induced by constipation and adhesions³.

The patient presented in our case had some of the risk factors for asymptomatic tubal torsion. However, the cause of the complete absence of both tube and ovary is still elusive. Possible consequences of unilateral absence of fallopian tube and ovary could potentially include subfertility. This is especially true if the right tube and ovary were to be affected by either salpingitis or ectopic pregnancy, necessitating its removal. Fortunately, our patient has had two successful pregnancies and has now completed her family.

References

1. Sivanesaratnam V. Unexplained unilateral absence of ovary and fallopian tube. *Eur J Obstet Gynecol Reprod Bio.* 1986 Jun; 22 (1-2): 103-5.
2. Eustace DL. Congenital Absence of tube and ovary. *Eur J Obstet Gynecol Reprod Biol.* 1992 Sep 23; 46 (2-3): 157-9.
3. Perternoster DM, Costantini W, Uglietti A, Vasile C, Bocconi L. Congenital or torsion- induced absence of Fallopian tubes. Two case reports. *Minerva Ginecol*, 1998 May; 50 (5): 1991-4.

Author Information

Nick Elkington

Consultant Obstetrician and Gynaecologist, Frimley Park Hospital

Ronnie Zahidur Rahman

Specialist Trainee Registrar Obstetrics and Gynaecology, Frimley Park Hospital