

Cysticercosis Of The Cheek

R Meher, A Sabherwal

Citation

R Meher, A Sabherwal. *Cysticercosis Of The Cheek*. The Internet Journal of Tropical Medicine. 2004 Volume 2 Number 2.

Abstract

The cheek is a rare site for cysticercosis cellulosae. Very few cases of solitary cysticercosis of cheek have been reported. We report one such case and discuss the review of literature, etio-pathogenesis, clinical course and management.

CASE REPORT

An 11-year old male presented to ENT OPD with a swelling on left cheek 8 months. The swelling was around 2cm x 2cm, firm and non-tender and mobile. FNAC of swelling showed only blood. An excisional biopsy was done from intraoral route and specimen was sent for histopathological examination, which revealed cysticercosis. Patient was then taken up for CT scan head and thorough clinical examination to rule out cysticercosis elsewhere. Stool examination for ova and cyst and blood examination for eosinophilia was within normal limits. Patient was given tablet albendazole 400mg daily for 8 days. Review of personal history revealed that the patient was not a meat eater.

Figure 1

Table 1: Reported Cases of Cysticercosis of the Head and Neck (excluding orbital and neurocysticercosis)

CASE	YEAR	AUTHORS	AGE	SEX	SITE	SIZE (CM)	SOLITARY / MULTIPLE	DURATION	TENDERNESS
1	1974	TIMOSCA AND GAVRILITA	9	F	submental	hazel nut	solitary	2 months	nontender
2	1974	TIMOSCA AND GAVRILITA	53	M	lower lip and cheek	peanut	multiple	4 years	nontender
3	1974	TIMOSCA AND GAVRILITA	20	F	cheek	0.9 X 0.9	solitary	3 month	nontender
4	1974	TIMOSCA AND GAVRILITA	30	F	cheek	peanut	solitary	-	nontender
5	1974	TIMOSCA AND GAVRILITA	22	F	chin, lower lip and cheek	0.5 X 1	multiple	3 months	nontender
6	1976	KINMANN ET AL	30	M	neck (midline)	0.5 X 1 cm	solitary	5 months	nontender
7	1976	KINMANN ET AL	55	F	tongue	0.5 X 1 cm	multiple	3 years	tender
8	1976	KINMANN ET AL	32	M	cheek	0.5 X 1 cm	solitary	4 years	nontender
9	1981	MAHINDRA ET AL	30	F	soft palate	2.5 X 3 cm	solitary	3 months	nontender
10	1981	MAHINDRA ET AL	11	M	submental	walnut	solitary	2 months	nontender
11	1989	JAIN ET AL	42	F	tongue	4 X 4 cm	solitary	3 years	nontender
12	1995	GUPTA AND GUPTA	N. A.	N. A.	tongue	-	-	-	nontender
13	1995	LAPENA	22	F	tongue	1 X 1 cm	solitary	11 years	nontender
14	1997	Jarin	31	F	tongue	1.5 X 1.5 cm	solitary	12 years	nontender

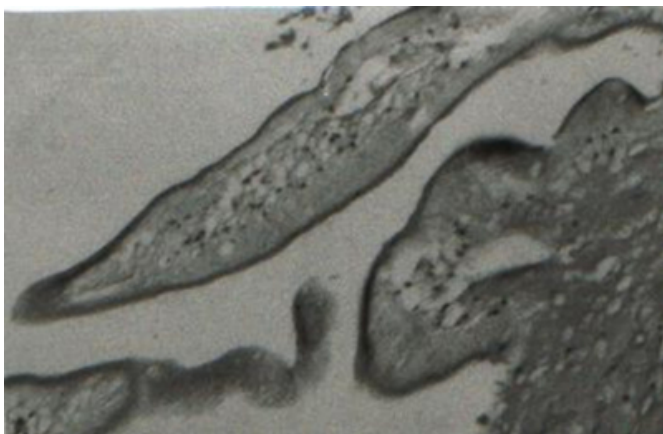
Figure 2

Figure 1: clinical photograph of the patient showing swelling in the cheek

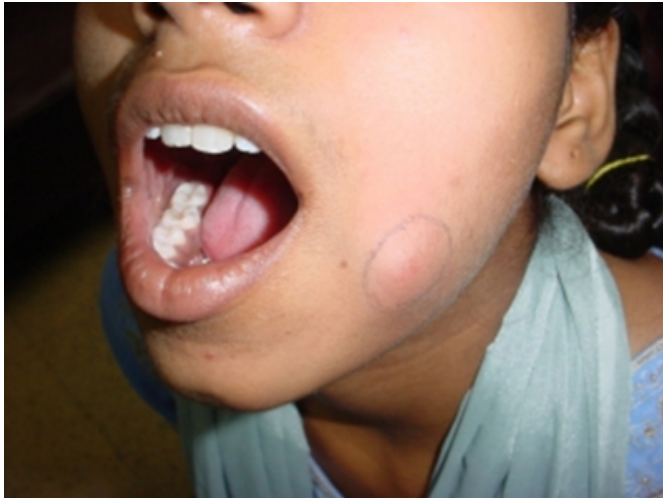

Figure 3

Figure 2: microphotograph of a cyst



DISCUSSION

ETIOLOGY AND PATHOGENESIS

The pork tapeworm (*T. solium*) can cause two distinct forms of infection. The form that develops depends on whether humans are infected with adult tapeworms in the intestine or with larval forms in the tissues (cysticercosis). Humans are the only definitive hosts for *T. solium*; pigs are the usual intermediate hosts, although dogs, cats, and sheep may harbor the larval forms. The adult tapeworm generally resides in the upper jejunum. Its globular scolex attaches by both sucking disks and two rows of hooklets. The tapeworm, usually about 3 meters in length, may have as many as 1000 proglottids each of which produces up to 50,000 eggs. Groups of 3 to 5 proglottids generally are released and excreted into the feces, and the eggs in these proglottids are infective for both humans and animals. The eggs survive in

the environment for several months. After ingestion by the intermediate host (pig), eggs embryonate, penetrate the intestinal wall, and are carried to many tissues via systemic circulation, with a predilection for striated muscle of the neck, tongue, and trunk. Within 60 to 90 days, the encysted larval stage develops. These cysticerci can survive for long periods. Humans acquire infections that lead to intestinal tapeworms by ingesting undercooked pork containing cysticerci. Infections that cause human cysticercosis follow the ingestion of *T. solium* eggs, usually from fecally contaminated food. Autoinfection may occur if an individual with an egg-producing tapeworm ingests eggs derived from his or her own feces or if eggs pass by reflux from the intestine into the stomach. The growing larva in cysticercosis may provoke a series of inflammatory reactions including infiltration of neutrophils and eosinophils, lymphocytes, plasma cells, and at times giant cells, followed by fibrosis and necrosis of capsule with eventual caseation or calcification of the larva.

CLINICAL FEATURES

Intestinal infections with *T. solium* may be asymptomatic. Epigastric discomfort, nausea, a sensation of hunger, weight loss, and diarrhea are infrequent. Human cysticercosis may be seen in brain, meninges, liver, lungs, orbit and peritoneum, however it is rare in tongue muscle. Clinical symptoms vary according to the site of involvement. Dead cysts in brain can swell, causing surrounding nerve tissue reactions and manifests as space occupying lesions with headache, vomiting and seizures. These may be asymptomatic as in case of tongue or cheek.

DIAGNOSIS

The diagnosis of intestinal *T. solium* infection is made by the detection of eggs or proglottids in stool. For cysticercosis, definitive diagnosis requires examination of the cysticercus in an involved tissue, but a diagnosis often can be based on clinical presentation in conjunction with compatible results in radiographic studies, especially computed tomography (CT) and magnetic resonance imaging (MRI) and serologic tests. For soft tissue involvement, plain films may reveal multiple calcified "puffed-rice" lesions.

TREATMENT

The management of cysticercosis can involve chemotherapy, surgery, and supportive medical treatment. Intestinal *T. solium* infection is treated with praziquantel. Asymptomatic patients with calcified soft tissue or neural lesions generally

require no treatment. For symptomatic patients with neurocysticercosis, both praziquantel (50 mg/kg per day in three doses for 15 days) and albendazole (15 mg/kg per day in three doses for 8 to 28 days) are effective. Because both agents provoke inflammatory responses around dying cysticerci, patients receiving either drug should be hospitalized and given high doses of glucocorticoids during treatment. For ocular and spinal lesions, drug-induced inflammation may cause irreversible damage; thus, these lesions as well as those within the ventricles are best managed by surgical resection. Not all neurological deficits resolve after therapy, and some patients may require continued anticonvulsive treatment. Soft tissue lesion if causing problem or looking cosmetically bad should be surgically excised.

PREVENTION

The major means of preventing infection is the adequate cooking of pork. The prevention of cysticercosis involves minimizing the opportunities for ingestion of fecally derived eggs by means of good personal hygiene, effective fecal disposal, and treatment and prevention of human intestinal infections.

CONCLUSION

For an ENT surgeon who encounters a cheek mass or any head and neck mass, which are histopathologically “cysticercosis”, may have a diagnostic and a therapeutic dilemma owing to the rarity of the disease. Infestation in this area is relatively benign as compared to ocular- and neuro-

cysticercosis. Most of the cases reported present as an asymptomatic mass. Treatment with cure is primarily surgical; however, a basic blood examination with focus on the eosinophils; a stool exam, and radiographic examination (cyst calcification) would rule out multiple organ involvement. The patient should be followed up for ophthalmologic, neurologic, as well as otolaryngologic signs and symptoms of cysticercosis cellulosae.

CORRESPONDENCE TO

Dr Ravi Meher Assistant professor Himalayan Institute of Medical Sciences, Jollygrant, Dehradun, Uttarakhand India E mail- meherravi@hotmail.com

References

1. Gupta SC, Gupta SC, Cysticercosis of the tongue. ENT Journal 1995; 74(3): 174-178.
2. Jain et al. Cysticercosis of the tongue. Journal of Laryngology and Otology 1989; 103:1227-1228.
3. Kinnman J et al. Cysticercosis in Otolaryngology. Archives of Otolaryngology 1976; 102:144-147.
4. Nigam S, Singh T, Mishra A, Chaturvedi KU. Oral cysticercosis--report of six cases: Head Neck 2001 Jun; 23(6): 497-9.
5. Saran RK, Rattan V, Rajwanshi A, Nijkawan R, Gupta SK. Cysticercosis of the oral cavity: report of five cases and a review of literature. Int J Paediatr 1998 Dec;8(4): 273-8.
6. Harrison's Principles of Internal Medicine 13th Edition, volume 1, chapter 184,931-932.
7. Timosca G. and Gavrilita L. (1974) Cysticercosis of maxillo-facial region. Oral Surgery, Oral Medicine, Oral Pathology, 37. 390-400.
8. Mahindra S, Daljit R, Sohail M. A. and Maheshwari H. B. (1981) Cysticercosis in the practice of otolaryngology. Acta otolaryngologica, 92: 189-191.

Author Information

Ravi Meher, MS(ENT), DNB(ENT)

Assistant Professor, Himalayan Institute of Medical Sciences

Anup Sabherwal, MS(ENT)

Consultant, Max Hospital