

Anaesthetic management of Wolff Parkinson White syndrome for caesarean section

A Shora, S Gurkoo, A Farooqi, M Qazi, W Nisa

Citation

A Shora, S Gurkoo, A Farooqi, M Qazi, W Nisa. *Anaesthetic management of Wolff Parkinson White syndrome for caesarean section*. The Internet Journal of Anesthesiology. 2007 Volume 16 Number 2.

Abstract

We present two cases of WPW syndrome in pregnancy. Risk factors for development of supraventricular tachycardia and the anaesthetic management during caesarean section are discussed. We recommend that regional anaesthesia can be given in patients with WPW syndrome; Phenylephrine is the best vasopressor for treatment of hypotension during spinal blockage and Adenosine is the first line therapy for the acute termination of PSVT.

In women of reproductive age, the commonest arrhythmia seen is paroxysmal supraventricular tachycardia (SVT).¹ Wolff Parkinson White syndrome accounts for the majority of supraventricular tachycardia in this population; with an incidence of 1.2 per 1000 people. Over half of these patients are asymptomatic.² Patients may complain of palpitation, dizziness, syncope or shortness of breath. The diagnosis is confirmed by E.C.G.

The incidence and severity of tachyarrhythmia in these patients may increase during pregnancy. Although reasons for this observation are unclear, some explanations have been proposed. Increased awareness, hemodynamic, hormonal, autonomic and emotional changes related to pregnancy, which may include increase in plasma catecholamine concentrations and adrenergic receptor sensitivity, atrial stretch and increased end diastolic volumes due to intravascular volume expansion have been implicated as some of the reasons.³

We present two cases of Wolff Parkinson White syndrome who underwent caesarean section under regional anaesthesia.

A 28 year old female, primigravida, was planned for caesarean section for cephalopelvic disproportion. The patient gave history of palpitations occasionally before pregnancy. But her symptoms increased during pregnancy. The patient did not give any history of syncope, dizziness or chest pain. In preanaesthetic check up, ECG showed features of WPW syndrome. The patient was advised cardiologist consultation who confirmed the diagnosis. She was not put

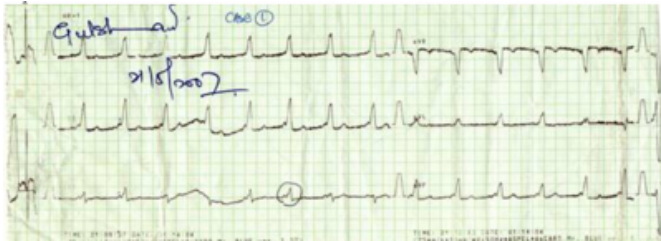
on any medication except anxiolytics.

She was planned for caesarean section under spinal anaesthesia. Her preoperative heart rate and blood pressure was normal. She was preloaded with 500 ml of normal saline. Routine monitoring included ECG, NIBP and pulse oximetry. Spinal anaesthesia was achieved with 2.5 ml hyperbaric Bupivacaine (12.5 mgs) using 25 G pencil point needle in sitting position. The patient was given a left lateral tilt of 15-20 degrees to prevent supine hypotensive syndrome.

A live healthy baby was delivered. Soon after the delivery of the baby, syntocinon 5 units were given as bolus and an infusion of 15 units in 500 ml of normal saline commenced. At this moment patient complained of palpitations and dizziness. Her heart rate increased from 84 to 180 beats / min and her blood pressure dropped to 80 mm Hg. Initially vagal manoeuvres were tried but without any improvement. Injection Phenylephrine 10 µg iv bolus was given which was repeated to treat hypotension. Adenosine 6 mg iv push was given which terminated arrhythmia and sinus rhythm was restored. There were no further episodes of PSVT and post operative period was uneventful. She was discharged after four days and was advised to follow cardiology department.

Figure 1

Figure 1: Pre operative ECG showing WPW syndrome

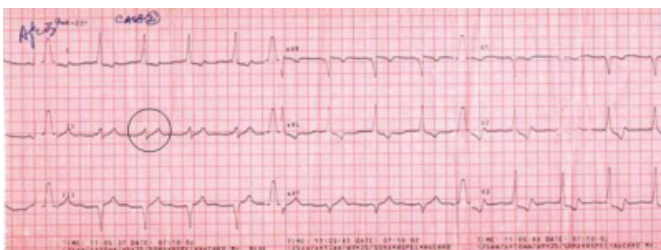


A 25 yr old female, primigravida presented for emergency caesarean section at 37 weeks of gestation. She didn't give any history of cardiac ailment in the past. She was planned for emergency caesarean section under spinal anaesthesia. Routine monitoring including ECG, NIBP and Pulse oximetry was started. ECG monitor showed short PR interval and slurred QRS complex. WPW syndrome was suspected. An ECG was done on the operating table and emergency cardiology evaluation was done. WPW syndrome was diagnosed.

After preloading the patient, hyperbaric bupivacaine 2.5 ml (12.5 mgs) was given with 25 G Sprotte pencil point needle to achieve a sub arachnoid block upto T4. Intraoperatively the patient remained hemodynamically stable. A live female baby was born. Her heart rate remained below 100 beats / minute and systolic blood pressure always remained above 100 mm HG. Ergometrine was avoided in this patient and syntocinon 5 units iv was given after delivery of baby and 15 units were added to 500ml of saline with no adverse effects. Post operative period was uneventful. She was discharged after 4 days and was advised to follow cardiology department.

Figure 2

Figure 2: Pre operative ECG showing WPW syndrome



Wolff-Parkinson-White syndrome (WPW), first described in 1930, is characterized by a short PR interval and a wide QRS complex with delta wave corresponding to ventricular Preexcitation.⁴ It is often asymptomatic although in a small percentage of cases may cause significant morbidity and occasionally mortality. Two types of arrhythmias are seen in

these patients.

Atrial fibrillation which can progress to ventricular fibrillation.

Circus movement type of re-entrant tachycardia causing paroxysmal supraventricular tachycardia.

Pregnancy may predispose to exacerbate symptoms of paroxysmal SVT. Clearly, both mother and fetus are at risk when SVT occurs during pregnancy.⁵

Treatment of tachyarrhythmias during pregnancy is complicated by concerns regarding safety and tolerability for the fetus. All commonly used anti arrhythmic drugs cross the placenta and so have direct effects on the fetus as well.⁶

Asymptomatic patients with WPW syndrome usually require no treatment and they have less chances of developing PSVT⁷ during surgery, if precautions are taken as was the case in our second case.

Drug use during labour for caesarean section may also precipitate SVT. Tocolytics and oxytocics have been implicated. Our patients were given oxytocin in low dose only. Present recommendations are that oxytocin should only be given as a bolus of 5 units maximum and administered slowly or as an iv infusion especially in the presence of cardiovascular compromise.⁸ Vasopressors used for the treatment of hypotension because of spinal block can also be the initiators of tachycardia. Phenylephrine has been found to be effective in treatment of hypotension without causing increase in heart rate in patients of WPW syndrome.⁹ It increases vagal tone by indirectly stimulating baroreceptor reflexes and therefore reduces SVT occurrences.

The reduced atrial filling after regional anaesthesia has also been implicated in increasing arrhythmogenicity of heart. A fluid preload not only helps to prevent reduction in atrial filling, but also reduces sympathomimetic requirements which may trigger SVT.¹⁰

Adenosine is rapidly becoming first choice of therapy for termination of SVT. It transiently depresses sinus node activity and slows atrioventricular conduction and is effective in terminating the SVT.¹¹ Since it is an endogenous nucleoside and has an estimated elimination half life of less than 10 seconds, it seems more suitable for the use during pregnancy and its safety and efficacy has been proved by various case reports and studies.¹² One of our cases was treated with only single 6mg bolus dose of adenosine. Since

there is an increase in intravascular volume during pregnancy the concentration of adenosine deaminase, the enzyme responsible for adenosine degradation declines, so doses of 6 – 12 mg should be adequate. Although no serious complications have been reported with use of adenosine during pregnancy, one report of transient fetal bradycardia¹³ has been reported. So monitoring of fetal heart rate should be done during its use in pregnancy.

If adenosine fails, other anti arrhythmics like beta blockers can be used especially where AV nodal blocking drugs may lead to acceleration of conduction through the accessory pathway. Verapamil, Diltiazem are also effective in converting SVT to sinus rhythm. Digoxin has been used in all stages of gestation for maternal and fetal indications without causing any harm. Amiodarone is perhaps best avoided because of its potential teratogenic effects and reports of fetal toxicity; but again there are reports of its safe use in pregnancy. Synchronised electrical cardio version may become necessary for PSVT resistant to pharmacological therapy particularly if hypotension develops. Radio-frequency ablation should be considered preferably before or after pregnancy.¹⁴

So to summarise WPW syndrome is one of the causes of supraventricular tachycardias occurring during pregnancy, labour or caesarean section. Avoidance of certain drugs and treatment of any precipitating factors, in particular hypotension by regional anaesthesia using a fluid preload and phenylephrine are appropriate. Adenosine is the first line treatment keeping a watch on fetal heart rate.

References

1. Nelson-Piercy C. Handbook of Obstetric Medicine, 2nd edn. London: Martin Dunitz, 2002; 22-3
2. Oakley C. Heart Disease in Pregnancy, 1st edn. London: British Medical Association, 1997; 248-9
3. Tan HL and Lie KI. Treatment of tachyarrhythmias during pregnancy and lactation. *European Heart Journal* (2001) 22;458-464.
4. Wolff L, Parkinson J, White PD. Bundle Branch block with short PR interval in healthy young people prone to paroxysmal tachycardia. *American Heart Journal* 1930;5: 685 - 704.
5. Rahul S, Patel RD, Dewoolkar. Anaesthetic management of WPW syndrome. *The internet Journal of Anaesthesia* ISSN : 1092-406X
6. Cox JL, Gardner MJ. Treatment of cardiac arrhythmias during pregnancy. *Progr. Cardiovasc Dis* 1993; 36 : 137 -78
7. Wellens HJJ, Smeets JL, Gorgeis AP. WPW syndrome in : Mandel WJJ ed. *Cardiac arrhythmias*, 3rd edition, J. B. Lippincott company, Philadelphia 1995; 389 -413.
8. Robbins K and Lyons G. Supraventricular tachycardia in pregnancy. Case reports. *BJA* 2004; 92 : 140-143.
9. Jacobson L, Turnquist K, Masley S. Wolf-Parkinson-White syndrome: Termination of paroxysmal supraventricular tachycardia with phenylephrine. *Anaesthesia* 1985; 40: 657-60
10. VanZijl DHS, Dyer A, Scott Millar RN, James MFM. Supraventricular tachycardia during spinal anaesthesia for caesarean section. *IJOA* 2001; 10: 202-5
11. Harrison JK, Greenfield RA, Wharton JM. Acute termination of supraventricular tachycardia by adenosine during pregnancy. *Am Heart J* 1992; 5: 1386-8
12. Elkayam U, Goodwin TM. Adenosine therapy for supraventricular tachycardia during pregnancy. *Am J Cardiol* 1995; 75: 521-3
13. Dunn JS, Brost BC. Fetal bradycardia after IV adenosine for maternal PSVT. *Am J Em Med* 2000; 18: 234-5
14. Rotmensch HH, Elkayam U, Frishman W. Antiarrhythmic drug therapy during pregnancy. *Ann Intern Med* 1983; 98: 487-97

Author Information

Asaf Nazir Shora, MD

Senior Resident, Department of Anaesthesiology and Critical Care, Sher-i-Kashmir Institute of Medical Sciences

Showkat Ahmad Gurkoo, MD

Additional Professor, Department of Anaesthesiology and Critical Care, Sher-i-Kashmir Institute of Medical Sciences

Ayaz Khalid Farooqi, MD

Associate Professor, Department of Anaesthesiology and Critical Care, Sher-i-Kashmir Institute of Medical Sciences

Moyd Syed Qazi, MD

Associate Professor, Department of Anaesthesiology and Critical Care, Sher-i-Kashmir Institute of Medical Sciences

Waqar Ul Nisa, MD

Senior Resident, Department of Anaesthesiology and Critical Care, Sher-i-Kashmir Institute of Medical Sciences