

An Unusual Case of Thrombocytopenia

M Khan, R Zaiden, D Pham, J House

Citation

M Khan, R Zaiden, D Pham, J House. *An Unusual Case of Thrombocytopenia*. The Internet Journal of Family Practice. 2009 Volume 9 Number 1.

Abstract

Sarcoidosis is a chronic granulomatous disorder characterized by multisystem involvement. We are reporting a case of sarcoidosis with severe thrombocytopenia and splenomegaly as presenting manifestations.

CASE REPORT

A 39 year old African American man presented with a sudden onset of bleeding gums and hematuria starting three days ago and progressively getting worse. There were no symptoms of frequency, urgency, burning micturition, fever or rigors. Past medical history was significant for sarcoidosis and uveitis diagnosed three years ago but in remission since then. He admitted to have used cocaine in past but denied using alcohol or tobacco. Family history was significant for diabetes and hypertension. Patient did not take any medications on regular basis. On admission his temperature was 99F, with heart rate of 120 bpm, blood pressure of 117/60 mmHg and Oxygen saturation of 99%. He had diffuse petechiae and bruising on both lower extremities. There was no evidence of lymphadenopathy but had palpable splenomegaly at 8 cm below the left costal margin. The remainder of his examination was within normal limits. His laboratory investigations revealed a platelet count of 1000/dl, leukocyte count of 3300/dl and a hemoglobin of 10.2 g/dl. His LDH level was 604 IU/L and his coagulation panel was within normal limits. His BUN was 26 mg/dl and Creatinine of 0.9 mg/dl. Coomb's test was negative. An abdominal CT showed bilateral non-obstructive ureteric calculi measuring 4-5 mm. He was also found to have moderate splenomegaly with bibasilar pulmonary interstitial fibrosis and hilar adenopathy. He was transfused 2 units of packed red cells, 7 units of platelet and was started on Methylprednisolone 1g/day IV. He was admitted to medical floor for further work up and management of anemia and thrombocytopenia. Bone Marrow biopsy and aspirate showed hypercellular marrow with trilinear hyperplasia. Flowcytometry was negative for lymphoproliferative disorders. Patient required multiple platelet transfusions after his admission to the hospital; however his platelets count did

not improve. Hematology as well as general surgery was consulted and splenectomy was recommended for ongoing bleeding and refractory thrombocytopenia. Patient underwent laparoscopic splenectomy and lymph node biopsy. Histological examination of spleen revealed red pulp hyperplasia consistent with hypersplenism and infiltration by non-caseating granulomas consistent with sarcoidosis (fig-1). A celiac lymph node biopsy showed enlarged lymph node virtually replaced by non-caseating granulomas (fig-2). His platelet count steadily improved and his bleeding resolved after splenectomy. He was discharged home on tapering dose of oral steroids and an outpatient follow up was arranged after his platelets count reached 76000/mm. Final diagnosed of Thrombocytopenia secondary to sarcoidosis related hypersplenism was made.

Figure 1

Fig-1: Histology of spleen revealing red pulp hyperplasia consistent with hypersplenism and infiltration by non-caseating granulomas consistent with sarcoidosis.

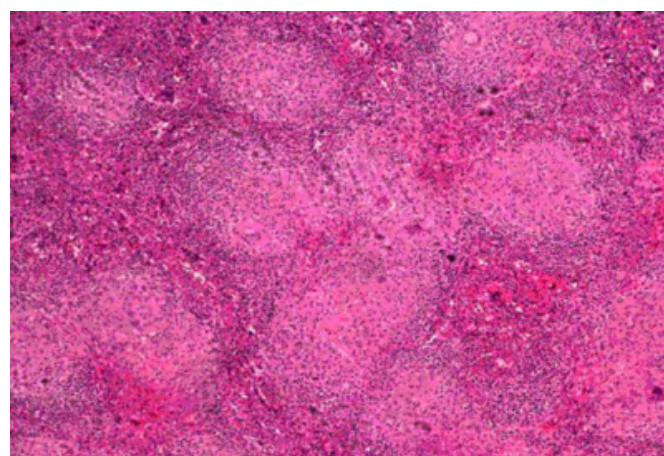
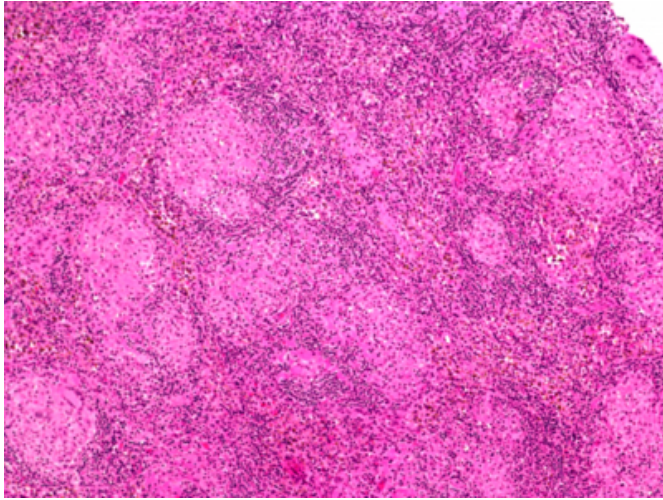


Figure 2

Fig-2: Lymph node with noncaseating granulomas.



DISCUSSION

Sarcoidosis is a chronic non caseating granulomatous disease that affects many organs and tissues, most commonly the lungs. The etiology remained incompletely understood since Sir Jonathan Hutchinson in 1869 first described the disease that today is believed to be sarcoidosis. The prevalence of sarcoidosis is 1-40 cases per 100,000 populations. In whites, the annual incidence is 10-14 cases per 100,000 populations, whereas in African Americans, especially women, the annual incidence is much higher, at 35.5-64 cases per 100,000 populations [1]. Scandinavians

have one of the highest incidence rates at 64 cases per 100,000 populations. Sarcoidosis is an inflammatory disease characterized by the presence of noncaseating granulomas, typically requiring the involvement of two or more organs for a specific diagnosis. The finding of granulomas is however not specific for sarcoidosis, and other conditions known to cause granulomas must be ruled out including mycobacterium and fungal infections. While virtually every organ of the body may be affected, the lung is most commonly involved. The clinical outcome of sarcoidosis varies, with remission occurring in over half the patients within a few years of diagnosis; however, the remaining patients develop a chronic disease that may persist for decades [2].

Sarcoidosis presenting as thrombocytopenia is very rare and only few such cases have been reported in literature. Our case has unusual manifestation of sarcoidosis including symptomatic thrombocytopenia which was most likely secondary to hypersplenism associated with sarcoidosis.

References

1. Rybicki BA, Major M, Popovich J Jr, Maliarik MJ, Iannuzzi MC. Racial differences in sarcoidosis incidence: a 5-year study in a health maintenance organization. *Am J Epidemiol.* Feb 1 1997;145(3):234-41.
2. Baughman Robert P, Lower Elyse E, "Chapter 322. Sarcoidosis" (Chapter). Fauci AS, Braunwald E, Kasper DL, Hauser SL, Longo DL, Jameson JL, Loscalzo J: *Harrison's Principles of Internal Medicine*, 17th Edition: <http://www.accessmedicine.com.lp.hscl.ufl.edu/content.aspx?aID=2863005>.

Author Information

Mohammad A. Khan, MD. MRCPI

College of Medicine, University of Florida

Robert Zaiden, MD

College of Medicine, University of Florida

Dat C. Pham, MD

College of Medicine, University of Florida

Jeff House, DO

College of Medicine, University of Florida