Fetal Demise Not Responding To Induction: A Case Report

P Deeksha, R Vani, S Jyoti, K Rupinder, S Kamath

Citation

P Deeksha, R Vani, S Jyoti, K Rupinder, S Kamath. *Fetal Demise Not Responding To Induction: A Case Report*. The Internet Journal of Gynecology and Obstetrics. 2007 Volume 9 Number 1.

Abstract

Report of a case of fetal demise not responding to induction and operative findings revealed abdominal pregnancy.

INTRODUCTION

Sometimes pregnancy ends tragically in the form of intrauterine demise. Commonly it occurs in pregnancies complicated with preeclampsia, diabetes, abruption, umbilical cord complications, infections, uteroplacental insufficiency or developmental disorders[1,2,3] . Sometimes, however the cause of fetal death is more complex and at times even unknown.

In the past, the convention of watchful delayed expectancy was popular, in anticipation that sooner or later the lifeless products will be expelled out by the body itself. With the advent of prostaglandins, however this has been entirely replaced by early induction.

CASE REPORT

A 22 year old gravida 2, abortion 1, was referred from a private practitioner with history of hypotension followed by loss of fetal heart sound at 30 weeks gestation. At the time of referral, the vital signs were stable, there was a midline infraumbilical scar and a drain site scar mark on the left iliac fossa, uterus was corresponding to period of amenorrhea, no bleeding per vaginum, os was closed, cervix was uneffaced and posterior. Transabdominal scan showed a dead fetus with placenta covering the os (Fig: 1).

The patient had past history suggestive of a gynecological surgery two years before marriage, and according to her pus was drained from the abdominal cavity (Fig: 2). We felt that a septic induced abortion could not be ruled out. She conceived one year after marriage, but spontaneously aborted at 2 months gestation which was followed by curettage. So considering all the risk factors (like suspected uterine scar following myomectomy or hysterotomy, curettage, history of loss of fetal heart sound following hypotension, and central placenta previa), we decided on expectant management.

On admission her hemoglobin was 8.25 g/dl, bleeding time 2 min 20 s, clotting time 4 min 55 s and platelet count 110,000/mm^3. Vital signs were stable throughout, she was moving her bowels and there was no bleeding per vaginum, and coagulation profile (repeated weekly) was within normal limits.

The patient however did not expel the dead fetus even after two weeks, so she was induced with PGE2 gel (instead of misoprostol for fear of scar rupture) but she didn't respond. After another 2 days, induction with PGE2 gel was tried for two consecutive days, with which she complained of some backache and abdominal pain with little cervical dilatation without effacement. The following day two more PGE2 gels were tried at 12 h interval after which her cervix became one finger loose but still it was thick and long, as earlier. After that, induction was tried with 150 ml of ethacridine lactate, extra-amniotically to which also patient did not respond.

She was taken up for laparotomy and to our surprise as soon as the thickened peritoneum was incised, the fetus was lying there. The pink colored dead fetus (with no signs of maceration) was removed from the peritoneal cavity and we could take out the placenta with ease, though piecemeal. Then on exploring the abdominal cavity we could see the organized slough all around, except on the left upper part from where the intestinal loops were peeping inside, nicely walling off the fetus, from other abdominal structures. On trying to explore in the downward direction, straw colored fluid came out with a gush, probably by the rupture of hydrosalpinx on the right side.

The uterus was around 8 – 10 weeks and well contracted, with its anterior wall shattered badly was lying in the pelvis,

however the left tube and ovary were absent (Fig: 3a). Right ovary was normal in size. As repair was impossible, total hysterectomy was done (Fig: 3b). Hemostasis secured and abdomen closed in layers. Postoperative period was uneventful.

Figure 1

Figure 1: TAS showing spalding sign in the dead fetus with contracted uterus giving a false impression of placenta praevia

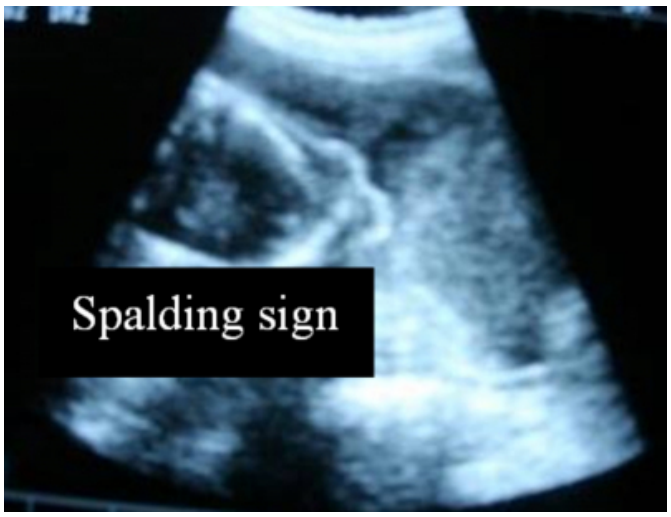

Figure 2

Figure 2: 30 weeks uterus with a drain site mark in the left iliac fossa

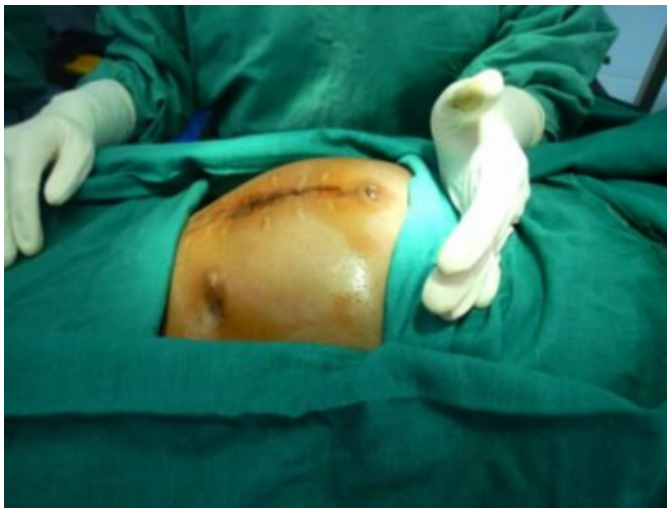

Figure 3

Figure 3a: uterus with its shattered anterior wall & right fallopian tube

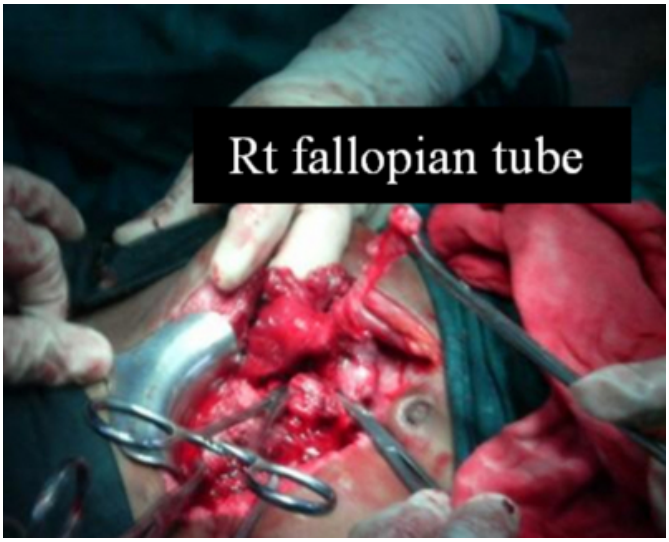

Figure 4

Figure 3b: hysterectomy specimen with shattered anterior wall

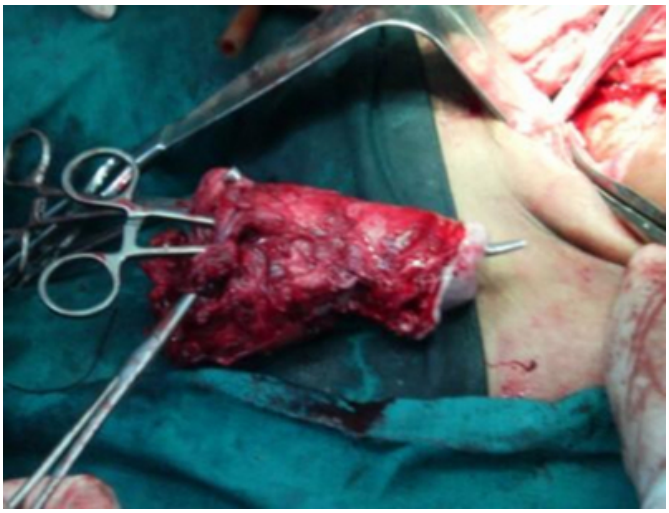

DISCUSSION

Though the patient gave a history of hypotension followed by disappearance of the fetal heart sound when she presented to us, the vital signs were stable and there was no other sign of rupture uterus like vaginal bleeding, abdominal tenderness or superficial fetal parts. Actually the ease of palpating fetal parts, so frequently talked of as a diagnostic sign of fetus in the abdominal cavity, is not a reliable sign[4]. Even with ideal conditions, a sonographic diagnosis of abdominal pregnancy is missed in half of the cases[5] and at times abdominal pregnancy has been incorrectly diagnosed as a placenta praevia[4]. So, the consensus is that sonography is not a

definitive diagnostic procedure for abdominal pregnancy[6,7]. Magnetic resonance imaging is more accurate and specific[8,9] Costa and associates (1991) maintain that computed tomography is superior to magnetic resonance imaging and should be considered in cases of fetal demise[10].

Keeping in mind the suspicion of a scarred uterus we decided on the old and time tested expectant management of intrauterine death. There is gradual depletion of maternal coagulation factors after intrauterine fetal demise, but the changes are not usually detectable, even in vitro, until after 3-4 weeks. Disseminated intravascular coagulation occurs in about one third of patients who retain the dead fetus for more than 4-5 weeks[11].

But when three weeks were over, without any sign of expulsion, we had no option but to intervene. Hence, she was induced with dinoprostone, the naturally occurring form of PGE2, because uterine hyper stimulation is more common with misoprostol[12].

In January 2004, the Cochrane Library commented on the paucity of data on the serious risks of induction with misoprostol and quoted that the studies reviewed were not large enough to exclude the possibility of rare but serious adverse events, particularly uterine rupture, which has been reported anecdotally following misoprostol use in women with and without previous caesarean section[12].

Our patient was repeatedly induced but did not respond and it has been mentioned that sometimes the presence of fetus in the abdomen is suspected only when repeated attempts at induction are unsuccessful[13]. In these cases cervix might dilate, but appreciable effacement is unusual[4], and the same happened in our patient.

Though prior cesarean is the most common reason for rupture, other common predisposing factors are previous traumatizing operations or manipulations such as curettage, perforation or myomectomy[14,15]. From the patient's history the nature of previous surgery was not clear but the peroperative finding of absent left ovary and tube suggests that the predisposing factor in our case might be the curettage following spontaneous abortion.

If the fetus dies after reaching a size too large to be resorbed, it may undergo suppuration, mummification or calcification[4], but in this case as the baby was lying inside the peritoneal cavity which is not in direct contact with the external environment, the fetus was not macerated.

CONCLUSION

Pregnancy sometimes ends tragically in intrauterine demise. Prostaglandins have revolutionized the management. Failure of repeated induction may point towards fetus in abdomen. Sonography is not a definitive diagnostic procedure for abdominal pregnancy. Magnetic resonance imaging is more accurate and specific. Still, definitive diagnosis is by laparotomy.

References

1. Kliman HJ: The placenta revealed. Amer J Pathol 1993;143:332-6.
2. Kliman HJ: Umbilical cord. In Knobil E, Neill JD (eds.): Encyclopedia of Reproduction, vol 4, pp 915-23. San Diego, Academic Press, 1999
3. Kliman HJ: Trophoblast to human placenta. In Knobil E, Neill JD (eds.): Encyclopedia of Reproduction, vol 4, pp 834-46. San Diego, Academic Press, 1999
4. Ectopic pregnancy, In Williams Obstetrics 22nd edition. F. Gary Cunningham, Kenneth J. Leveno, Steven L. Bloom, John C. Hauth, Larry Gilstrap III, Katherine D. Wenstorm (Eds). McGraw Hill, 2005; Chap 10:253-272
5. Costa SD, Presley J, bastert G: Advanced abdominal pregnancy. Obstet Gynecol Surv 1991;46:515
6. Angtuaco TL, Shah HR, Neal MR, Quirk JG: Ultrasound evaluation of abdominal pregnancy (review). Crit Rev Diagn Imaging 1994; 35:1
7. Sherer DM, Smith SA, Sanko SR: Uterine sacculation sonographically mimicking an abdominal pregnancy at 20 weeks gestation. Am J Perinatol 1994
8. Harris MB, Angtuaco T, Frazier CN, et al: Diagnosis of available abdominal pregnancy by magnetic resonance imaging. Am J obstet Gynecol 159:150, 1988
9. Wagner A, Burchardt AJ: Mr imaging in advanced abdominal pregnancy. A case report of fetal death. Acta Radiol 36: 193,1995
10. Glew SS, Sivanesaratnam V. Advanced extrauterine pregnancy mimicking intrauterine fetal death: case reports. Aust NZ J Obstet Gynecol, 1989; 29:450
11. Elizabeth A. Letsky: coagulation defects in pregnancy and the puerperium. In Turnbull's Obstetrics 3rd edition. Geoffrey Chamberlain, Phillip Steer (Eds). Churchill Livinstone, 2001; Chap 20: 311-331
12. Misoprostol for induction of labor. The WHO reproductive health library update. The Cochrane Library, Jan 2004; 1: 2
13. Ectopic pregnancy, In Jeffcoate's principles of Gynecology 6th edition. Neerja Bhatia (Eds). Arnold publications, 2001; Chap 11: 208-224
14. Fedorkow DM, Nimrod CA, Taylor PJ: Ruptured uterus in pregnancy: A Canadian Hospital's experience. Can Med Assos J, 1987; 137:27
15. Pelosi MA III, Pelosi MA: Spontaneous uterine rupture at thiry three weeks subsequent to previous superficial laparoscopic myomectomy. Am J Obstet Gynecol, 1997; 177:1547

Author Information

Pandey Deeksha, MS
Assistant Professor of Obstetrics & Gynecology, Kasturba Medical College & Hospital

R. Vani, M.D.
Professor of Obstetrics & Gynecology, Kasturba Medical College & Hospital

S. Jyoti, M.D.
Associate Professor of Obstetrics & Gynecology, Kasturba Medical College & Hospital

K. Rupinder, M.D.
Associate Professor of Obstetrics & Gynecology, Kasturba Medical College & Hospital

S. Kamath, M.D.
Private Practitioner