

Distal Locking Screws: The Easy Way

D Loveday, A Carroll

Citation

D Loveday, A Carroll. *Distal Locking Screws: The Easy Way*. The Internet Journal of Orthopedic Surgery. 2007 Volume 8 Number 2.

Abstract

BACKGROUND

Distal locking in intramedullary nails can be technically demanding, using either a radiolucent drill or freehand technique. We describe a tried and tested technique which makes a difficult job easier.

METHOD

Pre-operative planning is the key. The image intensifier is positioned as close as possible and at right angles to the limb to get a magnified circle on the screen.

After a stab incision and blunt dissected, a Steinmann pin is placed on the bone. The pin is held with two Cockers Forceps to prevent the surgeon's hand being under the image intensifier (Figure 1). The tip of the pin is then aligned with the hole of the nail with the image intensifier. Moving only the proximal end of the pin, the position is adjusted so it is in line with the circle (Figure 2).

Figure 1

Figure 1

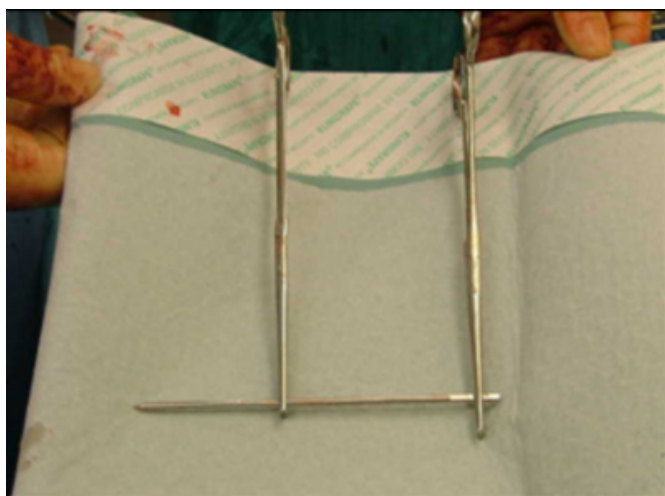
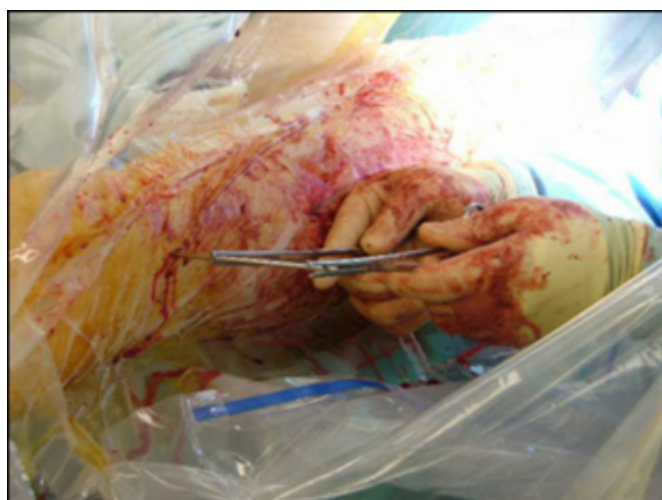


Figure 2

Figure 2



With the pin then aligned with the image intensifier it is tapped to leave a groove in the proximal cortex (Figure 3). The drill piece then replaces the pin in the groove and is advanced with the drill aligned with the image intensifier. With the set up correct, the drill advances through the proximal cortex, the nail and the distal cortex. The drill hole is then measured, tapped and the screw inserted to finish the distal locking of an intramedullary nail (Figure 4.)

Figure 3

Figure 3

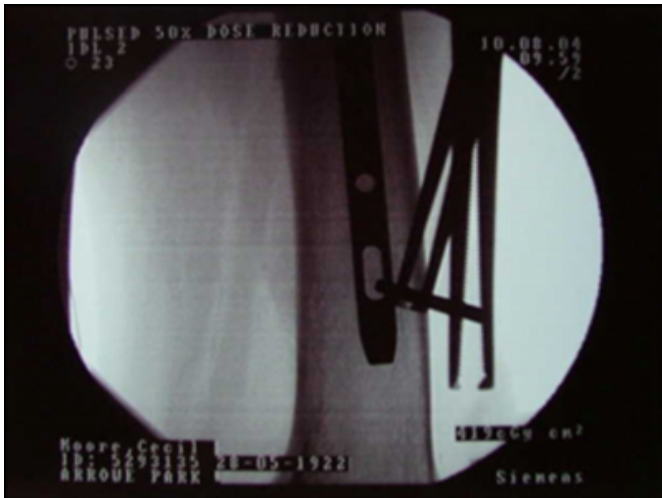
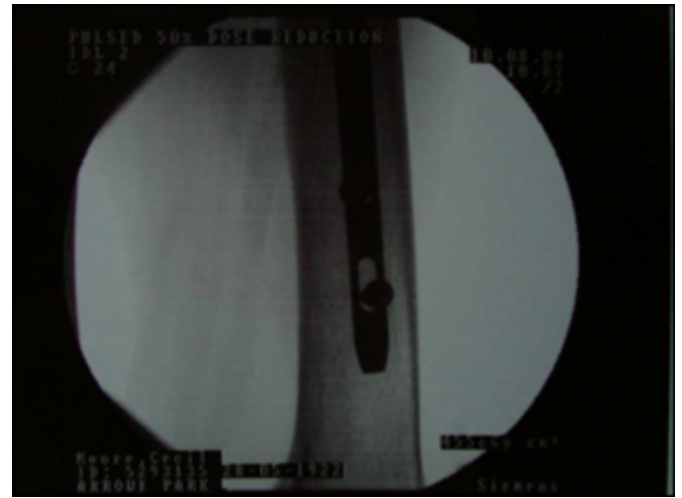


Figure 4

Figure 4



DISCUSSION

This technique is quick and easy to follow. Multiple drill holes are not made in the proximal cortex and the drill does not skid off the bone. A disadvantage occurs when the bone is soft. The pin can be driven through the bone and nail and can fracture the distal cortex. The intramedullary nail can also be damaged causing a stress riser and potential for nail breakage. Therefore care is needed when tapping the pin on the proximal cortex to leave a groove only.

We feel that this is a simple technique which, if followed correctly, can make free hand distal locking easier.

References

Author Information

D.T. Loveday, MRC
Addenbrookes Hospital

A. Carroll, FRCS
Arrowe Park Hospital