

A 58-Year-Old Woman With An Unusual Cause Of Respiratory Failure

M Jankowske, P Mailloux, M Przyborowski

Citation

M Jankowske, P Mailloux, M Przyborowski. *A 58-Year-Old Woman With An Unusual Cause Of Respiratory Failure*. The Internet Journal of Pulmonary Medicine. 2009 Volume 12 Number 1.

Abstract

A 58-year-old woman presented to the emergency department (ED) after she was found unresponsive for an unknown period of time. Upon paramedics' arrival she had a respiratory rate of 4 breaths/min, an O₂ saturation of 71% and a Glasgow Coma Score of 3. Her home medications included ibuprofen, fentanyl and lorazepam. The patient's mental status deteriorated and she ultimately required intubation and mechanical ventilation. She was managed in the intensive care unit (ICU) for what appeared to be a drug overdose and on the following day, after successful extubation, was transferred to the medicine wards. We report an unexpected twist in the pathogenesis of this case.

CASE REPORT

A 58-year-old woman presented to the emergency department (ED) after she was found unresponsive for an unknown period of time. Upon paramedics' arrival she had a respiratory rate of 4 breaths/min, an O₂ saturation of 71% and a Glasgow Coma Score of 3. The paramedics administered 0.8 mg of intravenous naloxone while transporting her to the hospital in addition to supplemental oxygen via a non-rebreather mask. Her mental status and respiratory rate slightly improved.

Upon admission to the ED her mental status made it difficult to obtain a thorough history. She denied any shortness of breath or any other recent generalized symptoms, but she admitted to ingesting an unknown quantity of diphenhydramine. She recently required casting for a broken right wrist and was wearing several 75 mcg/hr fentanyl patches, which were removed in the ED. She eventually admitted to ingesting 8 tablets of diazepam, dosage unknown. Her past medical history was significant for alcoholism, bipolar disorder, tobacco abuse and intravenous drug abuse. Her home medications included ibuprofen, fentanyl and lorazepam. The patient's mental status deteriorated and she ultimately required intubation and mechanical ventilation. She was managed in the intensive care unit (ICU) for what appeared to be a drug overdose and on the following day, after successful extubation, was transferred to the medicine wards.

PHYSICAL EXAMINATION

On admission to the ICU, her vital signs revealed sinus tachycardia at 100 beats/min and her blood pressure was 153/91 mmHg. She was intubated and sedated with a set respiratory rate of 20 breaths/min and an oxygen saturation of 100 percent while receiving an FiO₂ of 50%. Her pulmonary, cardiac, abdominal and extremity exams were unremarkable other than the cast on her right arm.

LABORATORY FINDINGS

Initial complete blood count and differential showed no signs of infection. Her blood chemistry was otherwise normal. Urine toxicology was negative for opiates but positive for methadone. Lab tests showed no evidence of salicylate or acetaminophen ingestion. An initial chest x-ray showed no signs of acute cardiopulmonary abnormality. Due to mental status changes, a computed tomography scan of the head was obtained and showed no acute pathology. Three days into her hospital course the patient developed a leukocytosis of 12,800 cells per cubic millimeter along with a cough, tachypnea and generalized weakness. Her left lung developed diminished breath sounds with dullness to percussion appreciated throughout her left hemithorax. A subsequent chest x-ray revealed opacification of the entire left lung (figure 1), while the right lung appeared normal. She was started on piperacillin - tazobactam and levofloxacin for empiric coverage of a presumed hospital acquired pneumonia. The decision was then made to proceed with bronchoscopy.

Figure 1

Figure 1: Chest X-ray, Left lung opacification with right-to-left mediastinal shift

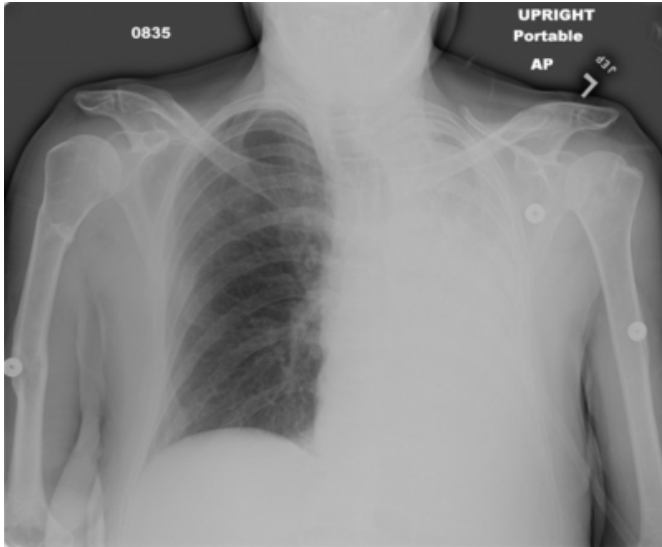
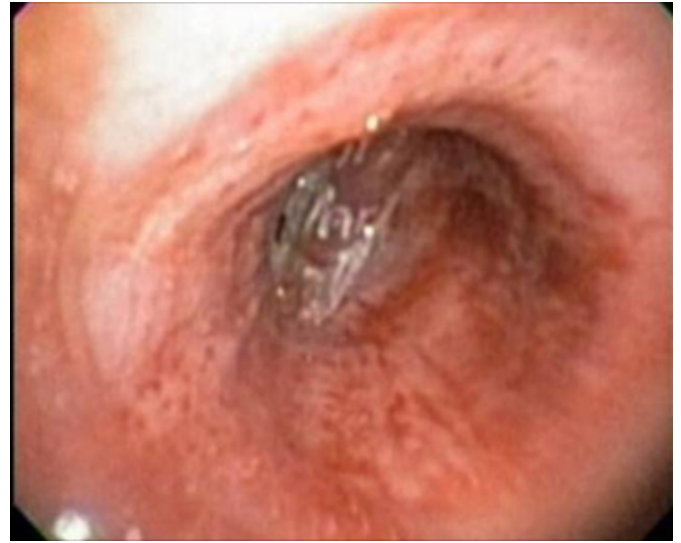

Figure 2

Figure 2: Bronchoscopic view. Fentanyl patch lodged within the bifurcation of the left superior and inferior bronchi

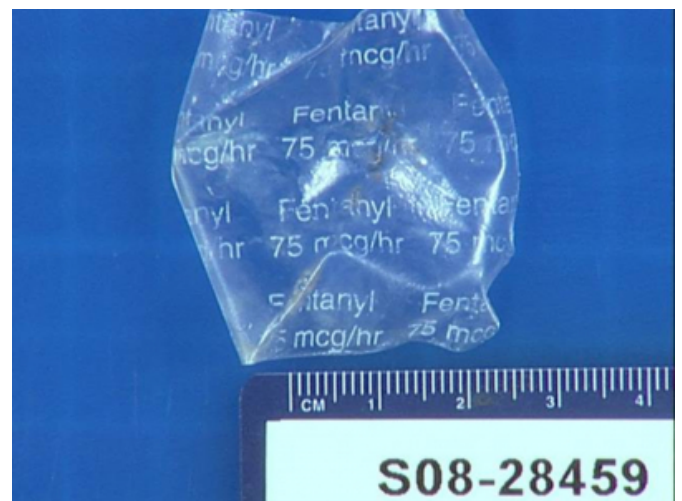

CLINICAL COURSE

A flexible bronchoscopy was performed, revealing a large mucus plug completely obstructing the left main bronchus. Therapeutic aspiration was then performed, clearing the bronchus. Moving distally, the bronchoscopist discovered what appeared to be a plastic tubular structure at the bifurcation of the upper and lower left lobes (Figure 2). A bronchoscopy was repeated and the structure was removed transorally using a forceps. Upon closer examination of the object, it was determined to be a fentanyl patch (Figure 3). A final therapeutic aspiration of the left airway was performed. The area surrounding the impaction site of the patch was grossly inflamed, and the patient was continued on an 8 day course of antimicrobials in the form of amoxicillin-clavulanate.

Figure 3

Figure 3: Gross specimen - Fentanyl patch removed from bifurcation of left superior and inferior bronchi



DISCUSSION

Tracheobronchial foreign body (TFB) aspiration occurs rarely in adults, in contrast to children, and as a consequence is infrequently included in the differential diagnosis. In the absence of a clinical history of aspiration, the diagnosis and treatment of a TFB is often delayed, occasionally on the order of months to decades.¹ Patients may present with sudden choking and intractable cough, with or without vomiting, often referred to as the “penetration syndrome.”^{2,3} This may only happen 49 percent of the time.² Symptoms may range from an acute episode of choking accompanied by coughing, wheezing, and cyanosis, to fever, dyspnea and

recurrent infection.

Diagnosing TFB aspiration in adults can be complicated by a number of factors. Many patients may not recall or be able to relate an aspiration event. Chest radiographs, the imaging modality of choice, may demonstrate only nonspecific abnormalities, especially when organic, radiolucent items such as food are aspirated. Adults presenting with TFB aspiration are typically found to have atelectasis on chest radiograph, as in our patient's case, while air-trapping is the more common presentation in pediatrics. Adult comorbidities, such as chronic obstructive pulmonary disease or congestive heart failure, can mimic symptoms of TFB aspiration and further complicate diagnosis by chest radiography.³

There is evidence the location of aspirated bodies differs in children and adults as well. While foreign bodies aspirated by children usually lodge in the proximal airways, foreign bodies aspirated by adults will migrate farther down the bronchial tree.² When they are lodged more proximally they may not entirely block the airway, leading to decreased acuity of symptoms, which also delays diagnosis. In their review, Baharloo and associates showed foreign bodies tend to lodge in the right bronchial tree in adults due to its more vertical structure, whereas this was not the case in children.² Adult patients may even present symptoms without any history of aspiration; even lack of a visible foreign body during bronchoscopy cannot rule out a TFB diagnosis, as the tissue surrounding the foreign body may become inflamed and obscure the object.⁴ All of these factors make the diagnosis of TFB aspiration difficult.

Although little comprehensive data is published to date on the prevalence of foreign body aspiration in adults, there are some apparent risk factors. In general, aspiration in adults can be attributed to two causes: loss of protective reflexes in the setting of altered consciousness and impaired neuromuscular function.⁵ These two causes may occur separately or in conjunction as a result of various conditions, including advanced age, mental retardation, use and abuse of sedating prescription drugs, use of illicit drugs, alcohol consumption, traumatic brain injury, poor dentition, dependence for feeding, procedural sedation, stroke and seizures. These same conditions may also make it difficult to elicit a clear medical history or even to perceive an episode of foreign body aspiration. In particular, the frequency of aspiration begins to rise steadily during the sixth decade of life as impairment of mental and neuromuscular function

becomes more prevalent.⁶

Once TFB aspiration is diagnosed, prompt removal is imperative. Delayed removal has been associated with recurrent pneumonia, lung abscess, bronchiectasis and bronchial stenosis.⁷ The foremost method of removal is flexible bronchoscopy in adults and rigid bronchoscopy in children. However, if a smaller TFB migrates to peripheral airways then thoracic surgery may be required. The removal process may be complicated by fracturing of the foreign body, especially with organic food items. Care should be taken to avoid mishandling of the foreign body, as it may necessitate a repeat bronchoscopy or surgical removal. TFB removal is best performed at more specialized centers, where experienced operators have fewer complications and more frequently obtain complete removal after a single attempt.² In our patient, removal was first attempted unsuccessfully using a ureteral stone basket. The patch was able to be grasped with forceps and removed in one piece (figure 3). There were no complications from this procedure and the patient's left lobe atelectasis resolved (figure 4, see below). She was discharged several days later. It was interesting to note that she had no recollection of swallowing the patch.

Polysubstance abuse predisposed our patient to develop an aspirated TFB, and evolution of clinical signs and symptoms took three inpatient days to occur. Certainly, the aspiration of a fentanyl patch is a unique occurrence most clinicians would not suspect. While TFB aspiration can potentially occur in anyone at any time, numerous factors make it much more likely, and diagnosis can be complicated by a multitude of factors. When evaluating patients with risk factors, TFB aspiration should accordingly be more highly suspected. Once foreign body aspiration is diagnosed, prompt removal of the foreign body generally relieves symptoms with no risk of recurrence.

CLINICAL PEARLS

Foreign body aspiration should be suspected in patients presenting with compromised airways, especially with identifiable risk factors for a TFB.

A normal chest radiograph does not rule out tracheobronchial foreign body aspiration.

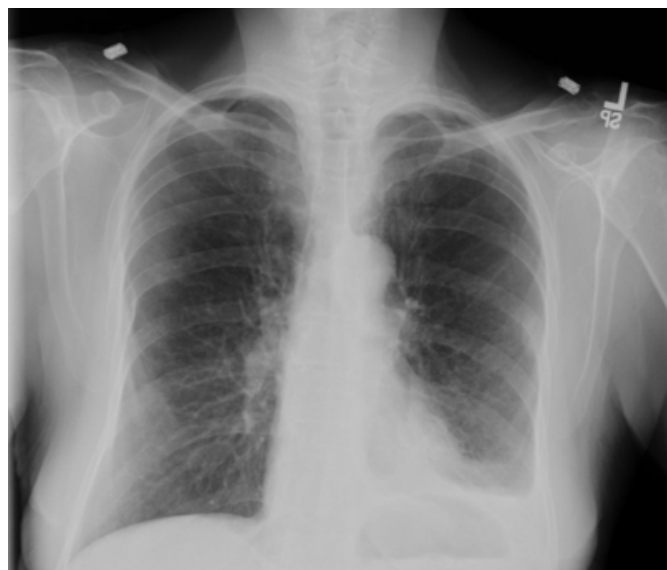Elderly patients, especially those requiring feeding assistance, and those with polysubstance abuse or who are mentally ill are at high risk for TFB aspiration.

Aspiration occurs twice as frequently in the right lower lung

than in the left in adults.

Figure 4

Figure 4: Chest X-ray resolution of left lung opacification and mediastinal shift post foreign body removal



References

1. Villegas FR, Zuñil M, Chillon MJ et al. Longstanding intrabronchial foreign body in an adult. *Journal of Bronchology* 2001; 8 (4), 289-293
2. Baharloo F, Veyckmans F, Charles, F et al. Tracheobronchial foreign bodies: presentation and management in children and adults. *Chest* 1999; 115: 1357-1362
3. Boyd M, Chatterjee A, Chiles C, et al. Tracheobronchial foreign body aspiration in adults. *Southern Medical Journal* 2009; 102, 2, 171-174
4. Lee P, Culver D, Farver C, et al. Syndrome of iron pill aspiration. *Chest* 2002; 121, 1355-1357
5. Paintal HS, Kushner WG. Aspiration syndromes: 10 clinical pearls every physician should know. *International Journal of Clinical Practice* 2007; 61, 5, 846-852
6. National Safety Council. Leading causes of death: An excerpt of injury facts. Chicago, IL, National Safety Council Press 2003; 10-15
7. Kim TJ, Goo JM, Moon MH, et al. Foreign bodies in the chest: how come they are seen in adults? *Korean Journal of Radiology*. 2001;2:87-96

Author Information

Mark Jankowske, DO

Medicine-Pediatrics Residency, Baystate Medical Center

Patrick Mailloux, DO

Critical Care Division, Baystate Medical Center

Mia Przyborowski

Mount Holyoke College