

Unusual Presentation of an Aural Foreign Body in an Adult

A Mukherjee, S Dutta, M Dutta, J Saha, I Sen, R Sinha

Citation

A Mukherjee, S Dutta, M Dutta, J Saha, I Sen, R Sinha. *Unusual Presentation of an Aural Foreign Body in an Adult*. The Internet Journal of Otorhinolaryngology. 2009 Volume 12 Number 1.

Abstract

Aural foreign body is a common entity in the ENT practice. An astonishing variety of materials have been reported as offending foreign bodies. The commonest articles found in the adults include cockroaches, cotton tips and ear plugs. Often, particularly in adults, the inaccessibility of the deep-seated foreign body inside the ear canal makes the self removal impossible and patient seeks medical advice. In the present article, an unusual case of aural foreign body has been reported where a gauze-piece got anchored to the handle of malleus through a pre-existing central perforation of the ear-drum and the successful removal was possible only by operative procedure under microscope.

INTRODUCTION

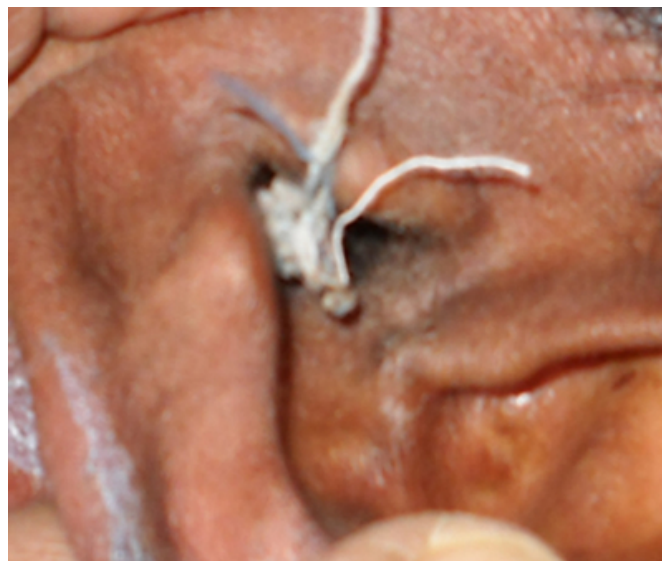
Studies on foreign body insertion were done mainly in children.¹ Available literature on adult aural foreign bodies are mostly unusual case reports. In available studies on adult aural foreign body, the object is mostly cotton wool of cotton buds, flying insects or silicone ear plugs². In some studies, cockroaches have been found as a common foreign body both in adults and children³.

CASE REPORT

A 30 year old male presented in the ENT out patient department with a part of cotton thread hanging outside his left ear for 2 days. On careful history taking it was noted that he had history of profuse, intermittent discharge from left ear for past many years. He had the habit of inserting rolled cotton gauge pieces in his ear to clean the discharge. Two days back, after cleaning his ear, he couldn't pull out the cotton piece and on traction, it caused pain. It was hanging outside his ear since then. [Fig-1]

Figure 1

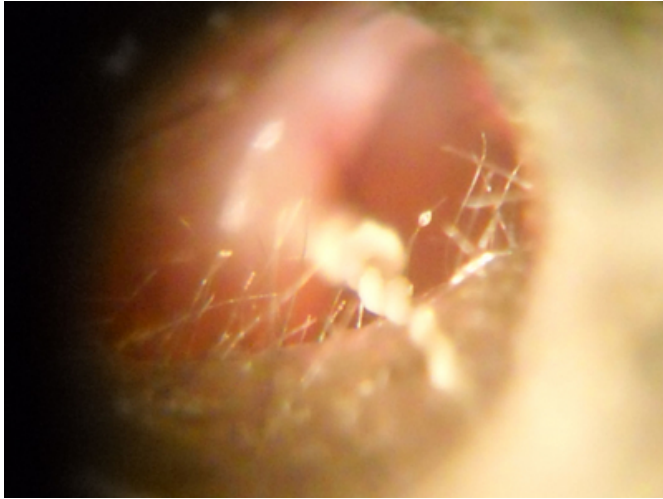
Figure. 1 - The white cotton thread can be seen hanging from the left ear in this photograph.



Otoscopy revealed a moderately large central perforation of the tympanic membrane and cotton threads of the gauge piece were found to be entangled to the malleus handle. The thread could not be removed in out patient department. He was taken to the operation theatre and was examined under microscope. It was found that the cotton threads got entangled forming a knot around the handle of malleus [Fig-2].

Figure 2

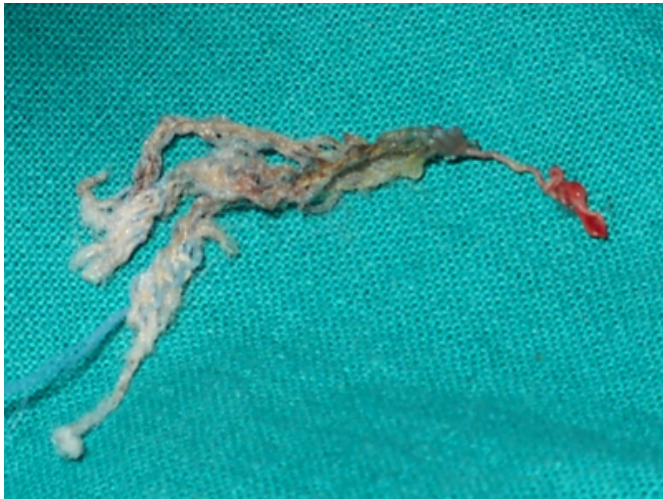
Figure. 2 - This is a microscopic view showing the left external auditory canal (with hairs). The tympanic membrane perforation can be seen. The whitish cotton thread is seen entangled with the malleus handle.



Under local anesthesia, the knots were untied carefully and the gauze-piece was removed. [Fig-3]

Figure 3

Figure. 3 - Photograph of the cotton thread after removal. The blood soaked end was tied to the malleus.



The patient was counseled to undergo proper treatment for his existing ear ailment.

DISCUSSION

Most of the case reports of adult aural foreign bodies, found in literature, are about unusual objects either accidentally entering the ear-canal⁴ or in cases where mentally diseased patient, inserting the foreign body in the ear and subsequently forgetting about it⁵. In the available studies, the adult foreign bodies commonly found in ear are cotton wool of cotton buds, flying insects, silicone ear plugs or cockroaches.^{2,3}

In self-inserted foreign bodies, done accidentally e.g. cotton wool, the deep-seated foreign body becomes inaccessible for self-removal forcing the patient to seek medical help. Adults generally present late, usually after all self removal methods fail.²

The novelty of the present case lies in the fact that –

(1) The foreign body got access to the middle ear ossicles due to the pre-existing central perforation and-

(2) It got anchored to the handle of malleus due to the maneuvering by the patient himself.

In fact, part of it was dangling outside the ear and the threads of the gauze-piece were entangled around the handle of malleus and any attempt to remove it by traction proved to be painful. It proves that, even when a part of any foreign body is visible outside the ear, it becomes imperative to perform an otoscopic examination to be sure of its attachments inside before planning a successful retrieval.

References

1. Ologe FE, Dunmade AD, Afolabi OA: Aural Foreign Bodies in Children. *Indian J Pediatr*; 2007; 74(8): 755-758
2. Ryan C, Ghosh A, De Villiers S, Wilson-Boyd B, O'Leary S: Adult aural foreign bodies. *Int J Otorhinolaryngol*; 2006; volume 4, number 2 available at: www.ispub.com/journal/the_internet_journal_of_otorhinolaryngology/volume_4_number_2_33/article/adult_aural_foreign_bodies.html downloaded on 13th April, 2010.
3. Antonelli PJ, Ahmadi A, Prevatt A: Insecticidal activity of common reagents for insect foreign bodies of the ear. *Laryngoscope*; 2001; 111:15–20
4. Eleftheriadou A, Chalastras T, Kyrmizakis D, Sfetsos S, Dagalakakis K, Kandiloros D: Metallic foreign body in middle ear: an unusual cause of hearing loss. *Head & Face Medicine*; 2007; 3:23.
5. Arora S, Goyal SK: Unusual foreign body in the ear in an adult patient with psychiatric illness. *Indian J Psychiatry*; 2009 Apr-Jun; 51(2):164

Author Information

Ankur Mukherjee, MS

Junior Resident, Department of ENT, R. G. Kar Medical College & Hospital

Sirshak Dutta, MS

Junior Resident, Department of ENT, R. G. Kar Medical College & Hospital

Mainak Dutta, MS

Junior Resident, Department of ENT, R. G. Kar Medical College & Hospital

Jayanta Saha, MS

RMO cum Clinical Tutor, Department of ENT, R. G. Kar Medical College & Hospital

Indranil Sen, MS

Associate Professor, Department of ENT, R. G. Kar Medical College & Hospital

Ramanuj Sinha, MS, DNB

Professor, Department of ENT, R. G. Kar Medical College & Hospital