

Unusual Presentation Of Hydatid Disease

S Kant, R Singh, R Bhatia, Sanjay

Citation

S Kant, R Singh, R Bhatia, Sanjay. *Unusual Presentation Of Hydatid Disease*. The Internet Journal of Pulmonary Medicine. 2007 Volume 10 Number 1.

Abstract

Haemoptysis is one of the most dreaded manifestations of cardiopulmonary diseases. In adults, It is most often caused by tuberculosis, bronchitis, bronchiectasis, trauma or bronchogenic carcinoma. Here, we report an unusual cause of haemoptysis, which was due to pulmonary hydatidosis.

INTRODUCTION

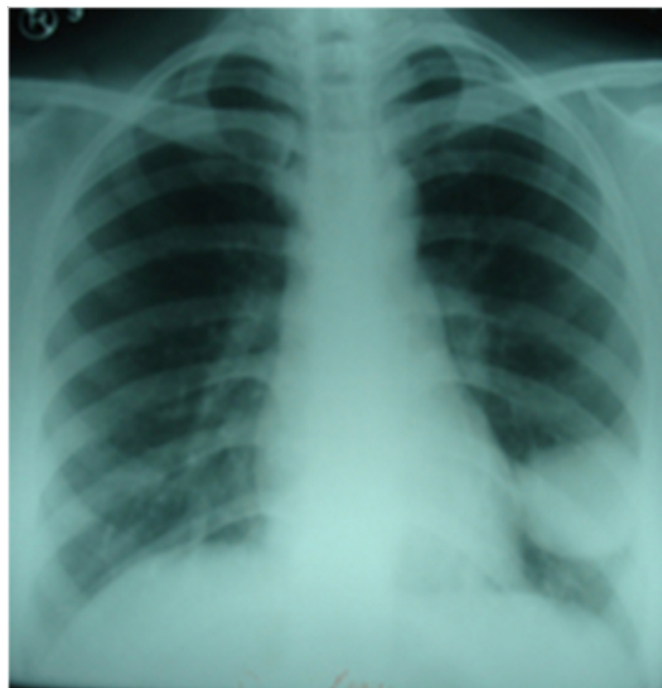Hydatidosis has a wide geographic distribution around the world. Hydatidosis is the most frequent cause of liver cyst in the world₁. In man, hydatid disease affects the liver in 68.8-75.2% of cases and the lung in 17.2-22.4% of cases₂. The lungs are the second most common sites of lodgement of the parasite. Although the liver and lung are most common sites for the disease, hydatids can occur in any organ of the body. Synchronous pulmonary and hepatic hydatid disease may occur in 4% to 25% of cases₃. Extrapulmonary cysts can occur in the chest wall, mediastinum, pericardium, and myocardium, and within the pleura cavity.

CASE REPORT

A 30 years nonvegetarian female was admitted to our department with three years history of haemoptysis and no other complaints. There was no history of exposure to domestic animals. Physical examination reveals anaemia and rest was without any significant finding. Chest X ray showed a well defined radio-opacity in left lower zone (Fig 1).

Figure 1

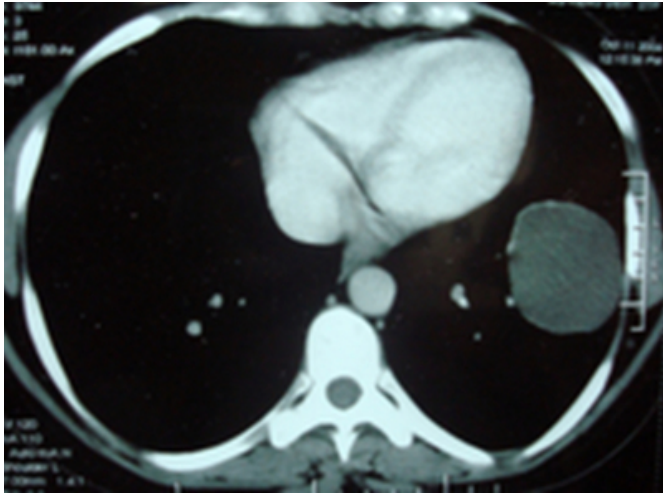
Figure 1: Chest X ray PA view showing a well defined radio-opacity in left lower zone



CT thorax showed a well margined rounded cystic lesion in the left lower lobe, anterobasal segment with no calcification or surrounding consolidation (Fig 2).

Figure 2

Figure 2: CT thorax showing a well marginated rounded cystic lesion in the left lower lobe



The total and differential count were within normal limits except for increased neutrophils. All routine investigations including liver function, kidney function, urine analysis and lung function were within normal limits. Sputum specimen for mycobacterium and other pathogens were smear and culture negative. Sputum was negative for scolices and brood capsules too. Serological tests were negative for all other pathogens including mycoplasma and chlamydia but serology for echinococcus was positive. USG abdomen was within normal limits and not suggestive of any cystic lesion in liver and kidneys. Fibreoptic bronchoscopy reveals no pathological finding. Patient was put on antihelminthic treatment, Albendazole 400mg bid for 6 cycles of 28 days with a gap of two weeks and she improved clinically and radiologically (Fig 3).

Figure 3: Chest X ray PA view showing resolution of lesion

DISCUSSION

Hydatid disease is the most widespread serious human cestode infection. Echinococcosis, or hydatid disease, is infection with the larval (cystic) stage of tapeworms belonging to the genus *Echinococcus*. The most common definitive host for *E. granulosus* is the domestic dog and human acquires infection by ingesting viable parasite eggs with food. Cysts most commonly develop in the liver, but can also be found in the lungs, kidney, spleen, nervous tissue, or bone. Three species of *Echinococcus* are known to cause disease in human beings: *E. granulosus*, *E. multilocularis*, and *E. vogeli*. Pathogenesis and disease manifestations vary according to the infecting species.

Echinococcus granulosus, the most common and widespread species, causes cystic hydatid disease. A hydatid cyst enlarges slowly and is generally well tolerated by an infected person until it is large enough to cause a notable mass effect. Signs and symptoms depend on cyst size and location. Ruptured or leaking cysts, however, may result in severe anaphylactoid reactions and they may release protoscolices capable of producing secondary cysts. Cough, chest pain and breathlessness, haemoptysis are the most common presenting symptoms. Haemoptysis in adults is most often caused by tuberculosis, bronchitis, bronchiectasis, trauma or bronchogenic carcinoma⁴. Underlying etiology for haemoptysis may be unknown in 20% of the cases. The mechanism of haemoptysis in pulmonary hydatid disease may be due to pressure erosion of a bronchus or obstructive effect with bronchial infection. This may in turn lead to further erosion into branch arterial supply leading to haemoptysis⁴. The cyst may rupture into a bronchus, pleural cavity, mediastinum, chest wall and blood vessels like aorta and can lead to massive haemoptysis⁵. Usually the diagnosis is either first suspected or decided upon by radiological studies. In endemic areas hydatid cysts are the most common cause of well defined, solid, single or multiple round densities. Rarely these may calcify when a cyst ruptures into a bronchus and empties its contents only partially leaving the ruptured membrane floating on a fluid level. This radiological finding is often considered to be pathognomonic of pulmonary echinococcosis is called the WATER LILY SIGN. When air is trapped between two layers of ruptured cyst wall the CRESCENT/ MENISCUS sign can be demonstrated⁶. Other radiological signs that have been described are the double arch sign, mass migrating sign, solar eclipse sign, daughter cyst sign and the ring within ring sign⁷. CT and USG are used more commonly to evaluate for hepatic disease. All suspected hydatid cyst lung should have a ct chest, abdomen and pelvis to evaluate for metastatic disease which may not be uncovered by other means. Serological sensitivity is 80-100% and specificity is 88-96% for liver cyst infection but lower for lungs (50-56%) or other organ involvement. Diagnostic puncture of cysts is only justified when imaging and serological tests do not permit discrimination between hydatid cyst and neoplasm. It carries risk of anaphylaxis and spillage of cyst contents leading to secondary echinococcosis⁸. Treatment options for cystic hydatid disease include surgery, drug therapy and percutaneous drainage. Optical treatment of symptomatic cyst is surgical dissection of the cyst. Surgery has the potential to remove cyst and lead to complete cure. Surgical

procedures of choice include cystectomy with removal of germinal and laminated layers and preservation of pericyst. Operative mortality varies from 0.5% -4%. Medical therapy for inoperative cyst is with benzimidazoles (albendazole and mebendazole) and praziquantel, an isiquinolone derivative, which have scolical tendency and has been widely used in patient with cystic hydatid disease. Albendazole in comparison to mebendazole is better absorbed and used in daily dose of 10-15mg/kg. Cyclic treatment in form of 3month course with interval of 14 days has been widely used. Recent data shows that uninterrupted drug therapy for 3-6 months has better efficacy with no increase in adverse effects. Imidazoles are hepatotoxic, can cause neutropenia, thrombocytopenia, alopecia and are potentially embryotoxic and teratogenic⁹. Recently percutaneous drainage of hydatid cysts popularly known as PAIR(Puncture, Aspiration, Instillation of scolical agent and Reaspiration) has gained acceptance¹⁰. This procedure is minimally invasive; cost effective involves reduced hospital stay and has less morbidity and mortality than surgery.

References

1. Beauchamp RD, Holzman MD, Fabian T C spleen, townsend CM, Beauchamp RD, Evers BM. Sabiston textbook of surgery. 6th ed Philadelphia, W.B. Saunders company 2001; pp: 1151-52.
2. Karmali S, Thompson S, Mckinon G, Anderson I. A 37 year-old-women with fever and abdominal pain. CMAJ 2005; 13: 1503.
3. Koyluoglu G, Oztoprak I. Unusual presentation of pancreatic Hydatid cyst in a child. Pancreas 2002; 24(4): 410-1.
4. Griffith DE, Girard WM, Wallace RJ. Clinical features of pulmonary disease by rapidly growing mycobacteria: An analysis of 154 patients. Am Rev respire Dis 1993; 147: 1271-8.
5. Harris DG, Van Vuuren WM, Augustyn J, Rossouw GJ. Hydatid Cyst fistula into the aorta presenting with massive haemoptysis: case report and literature review. J Cardiovasc Surg (Torino) 2001; 42: 565-7.
6. Beggs I. The radiology of hydatid disease. AJR 1985; 145: 639-48.
7. Xu M. Hydatid disease of lung. Am J Surg 1985; 150: 568-73.
8. Gori S, Campetelli A, Luchi S, Paladini A, Sovalli E, Scasso A. Cytology in the percutaneous treatment of hydatid cysts: a report of four cases. Acta cytol 1998; 37: 423-6.
9. WHO Informal Working Group on Echinococcus. Guidelines for treatment of cystic and alveolar Echinococcosis in humans. Bull WHO 1996; 74: 231-42.
10. Gargouri M, Ben Amor N, Ben Chehida F, et al. Percutaneous treatment of hydatid cysts (Echinococcus granulosis). Cardiovasc Intervent Radiol 1990; 13: 169-7.
11. Surya Kant, Gupta GL, Tandon S. Pulmonary hydatid disease - Case report and review. Journal of internal medicine of India 2003; 6: 149- 51.

Author Information

Surya Kant

Professor, Department of Pulmonary Medicine, CSMMU

Rajni Singh

Junior Resident, Department of Pulmonary Medicine, CSMMU

R.S. Bhatia

Consultant chest physician

Sanjay

Senior Resident, Department of Pulmonary Medicine, CSMMU